

# NUCLEAR MEDICINE FOR MEDICAL STUDENTS AND JUNIOR DOCTORS

Dr JOHN W FRANK

M.Sc, FRCP, FRCR, FBIR

PAST PRESIDENT,

BRITISH NUCLEAR MEDICINE SOCIETY

DEPARTMENT OF NUCLEAR MEDICINE,

1<sup>ST</sup> MEDICAL FACULTY, CHARLES UNIVERSITY,  
PRAGUE

2009

## ACKNOWLEDGEMENTS

I would very much like to thank Prof Martin Šámal, Head of Department, for proposing this project, and the following colleagues for generously providing images and illustrations.

Dr Sally Barrington, Dept of Nuclear Medicine, St Thomas's Hospital, London

Professor Otakar Bělohlávek, PET Centre, Na Homolce Hospital, Prague

Dr Gary Cook, Dept of Nuclear Medicine, Royal Marsden Hospital, London

Professor Greg Daniel, formerly at Dept of Veterinary Medicine, University of Tennessee, currently at Virginia Polytechnic Institute and State University (Virginia Tech), Past President, American College of Veterinary Radiology

Dr Andrew Hilson, Dept of Nuclear Medicine, Royal Free Hospital, London, Past President, British Nuclear Medicine Society

Dr Iva Kantorová, PET Centre, Na Homolce Hospital, Prague

Dr Paul Kemp, Dept of Nuclear Medicine, Southampton University Hospital

Dr Jozef Kubinyi, Institute of Nuclear Medicine, 1<sup>st</sup> Medical Faculty, Charles University

Dr Tom Nunan, Dept of Nuclear Medicine, St Thomas's Hospital, London

Dr Kathelijne Peremans, Dept of Veterinary Medicine, University of Ghent

Dr Teresa Szyszko, Dept of Nuclear Medicine, St Thomas's Hospital, London

Ms Wendy Wallis, Dept of Nuclear Medicine, Charing Cross Hospital, London

## **Copyright notice**

*The complete text and illustrations are copyright to the author, and this will be strictly enforced. Students, both undergraduate and postgraduate, may print one copy only for personal use. Any quotations from the text must be fully acknowledged. It is forbidden to incorporate any of the illustrations or diagrams into any other work, whether printed, electronic or for oral presentation.*

## ***CONTENTS***

Introduction	p 5
History	p11
Clinical studies	p19
Bone, soft tissue and infection	p19
Breast	p32
Sentinel node	p37
Lymphatics	p38
Cardiac	p40
Endocrine	p47
Pituitary	p47
Thyroid	p48
Parathyroid	p52
Pancreas	p54
Adrenals	p57
Ovaries/testes	p64
Neuroendocrine	p64
Gastro-intestinal	p67
Gastric emptying	p67
Oesophageal transit	p68
Inflammatory disease	p70
Bleeding	p73
Meckel's	p74
Hepato-biliary	p75
Head and neck	p82
Vocal cord	p83
'lumps'	p84
Epiphora	p86

Brain	p87
Tumour	p87
Infection	p88
Movement disorders	p89
Dementias	p92
Cerebral blood flow	p94
Epilepsy	p95
Lung and Chest	p98
Paediatric	p113
Renal	p122
Static	p123
Dynamic	p128
Reflux	p136
Vascular	p139
Radionuclide therapy	p142
The Future	p149
Statistics	p152
Legal requirements	p153
Patient information	p154
Quiz	p156
Suggested reading and websites	p178



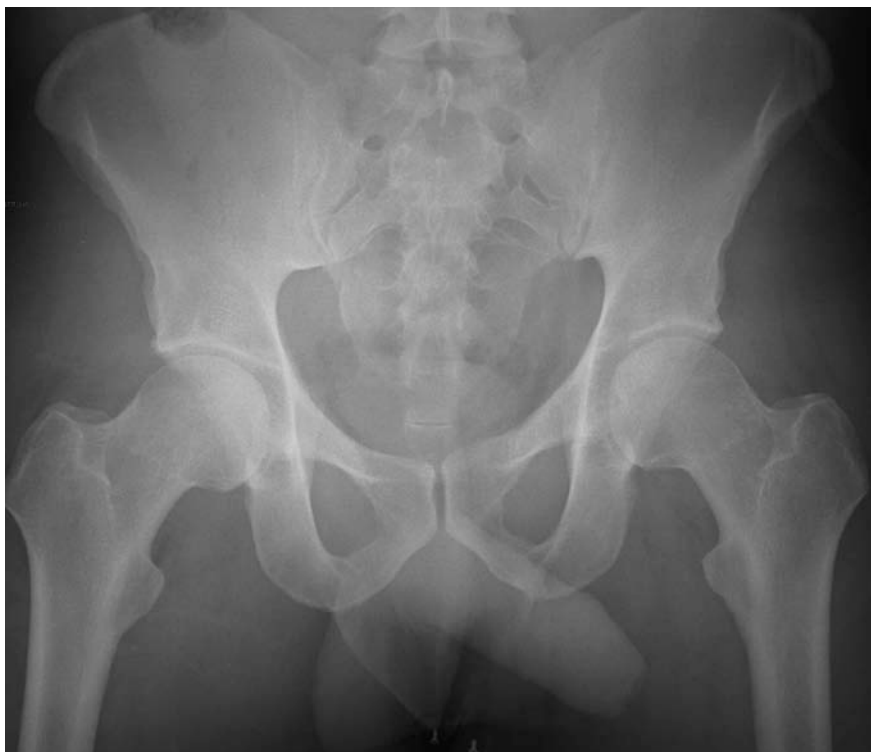## INTRODUCTION

### Principles

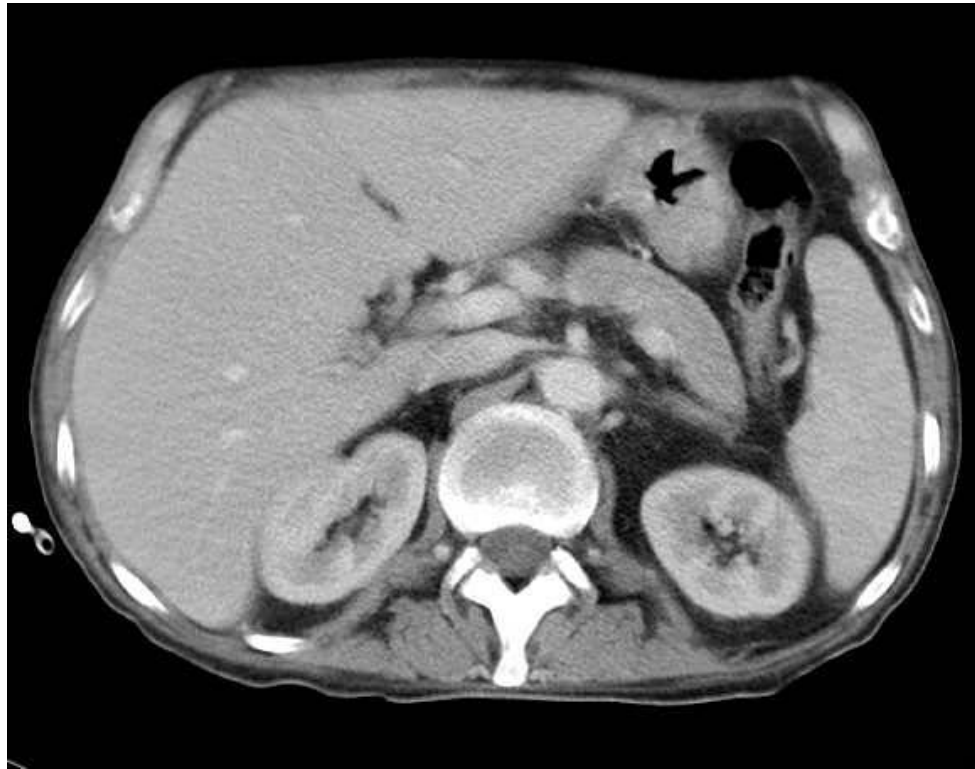
There are four basic methods of imaging the body, using x-rays, gamma rays, sound waves and magnetism. Each has its own place, and they are complementary, not exclusive.

X-rays, whether as conventional images or as CT, provide anatomical information.

X-rays (first discovered by Röntgen in 1895) are produced when electrons from the cathode in the x-ray tube hit the anode, usually made of tungsten mounted on steel, which is angled so that the x-rays leave the tube and can be collimated into a beam. The energy of the x-rays is a measure of their penetrating power - the higher the energy, the more penetrating. The beam is then collimated, and passes through the area of the body under investigation. The x-rays are absorbed by the tissues through which they pass, and the denser the tissue, the more are absorbed. Thus, at an x-ray energy of 85kV which is normal for diagnostic imaging, air absorbs none and bone absorbs all, with other tissues absorbing a variable amount. Thus a 'shadowgraph' emerges and it is this that is imaged on the x-ray film. In CT there is no film, rather an array of detectors, which pick up the attenuated beam and process it.



X-RAY ADULT PELVIS - SEX OF PATIENT?

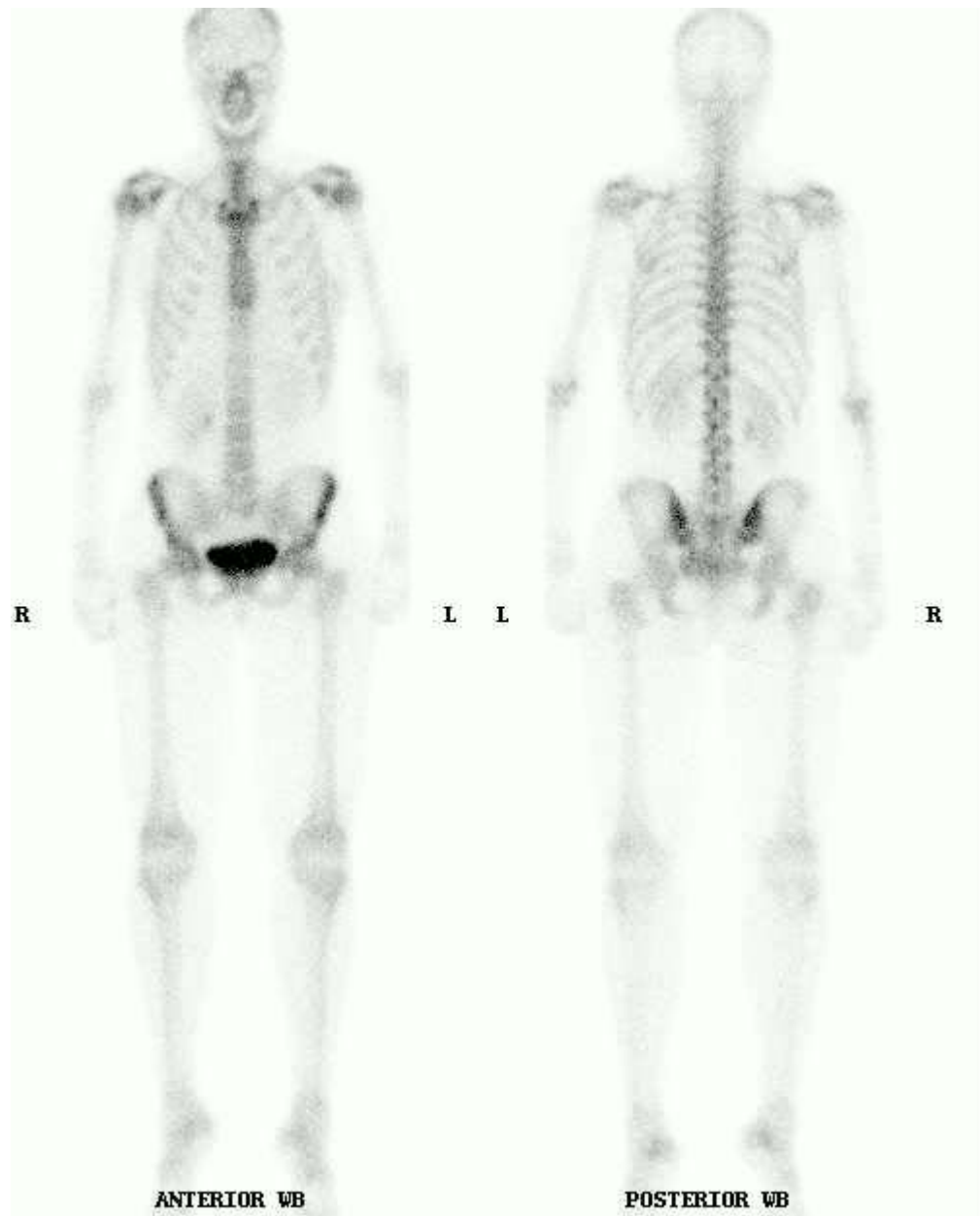


CT SCAN UPPER ABDOMEN

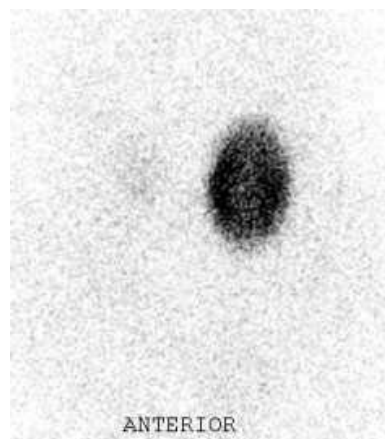
In both the conventional image and the CT image, the differential attenuation allows visualisation of the tissues.

In Nuclear Medicine studies, a carrier molecule is labelled with a radio-active tracer, usually  $^{99m}\text{Tc}$ , and this is injected into the patient. Thus in this case it is the patient who is the source of the radiation, which are gamma rays, and they are emitted all around the patient. Another major difference is that x-rays are only produced from the tube when the machine is activated and the current flows through the x-ray tube, and the duration of current flow is set by the radiographer. When there is no current, there are no x-rays emitted. However, the gamma rays are emitted continuously, but decaying all the time. Isotopes have a half life ( $t_{1/2}$ ) which varies from isotope to isotope. This is the time required for the activity to fall to 50%.  $^{99m}\text{Tc}$  has a  $t_{1/2}$  of 6 hours. Nuclear Medicine studies, using gamma rays, provide physiological information. Conventional radiography, CT, US and MRI all provide anatomical information. The isotope and carrier used depend on the organ or system to be studied, and will be detailed later.

This means that the Nuclear Medicine image will not necessarily be anatomically recognisable, although in the case of bone scans it often is.



NORMAL ADULT BONE SCAN - FAIRLY ANATOMICAL



TOXIC THYROID NODULE - NOT ANATOMICAL AT ALL

A patient who has been injected with a radio-active tracer is slightly radio-active, but the activity is constantly falling, both due to the physical  $t_{1/2}$  of the isotope, but also due to breakdown and excretion of the carrier molecules (the biological  $t_{1/2}$ ). The effective  $t_{1/2}$  can be defined thus:

$$1/t_{1/2 \text{ eff}} = 1/t_{1/2 \text{ phys}} + 1/t_{1/2 \text{ biol}}$$

Nuclear Medicine can be used to image most parts of the body, but some organs are imaged much more than others.

### Risks

For short  $t_{1/2}$  isotopes administered in normal diagnostic doses, there is no risk to either the patient or anyone else. It is important to inform the patients of this because they may otherwise worry needlessly, especially as a lot of people equate radiation with atom bombs, Chernobyl, and so on. With most straightforward diagnostic scans, as opposed to therapeutic administration of isotopes, radiation levels are well within the normal variation of background radiation, e.g. watching TV. Patients who have had a diagnostic scan can go near pregnant women or children without causing them any harm, and the same applies after treatment for benign diseases with isotopes such as  $^{131}\text{I}$  for thyrotoxicosis. Obviously, the patient cannot ask every woman they stand next to if she is pregnant!

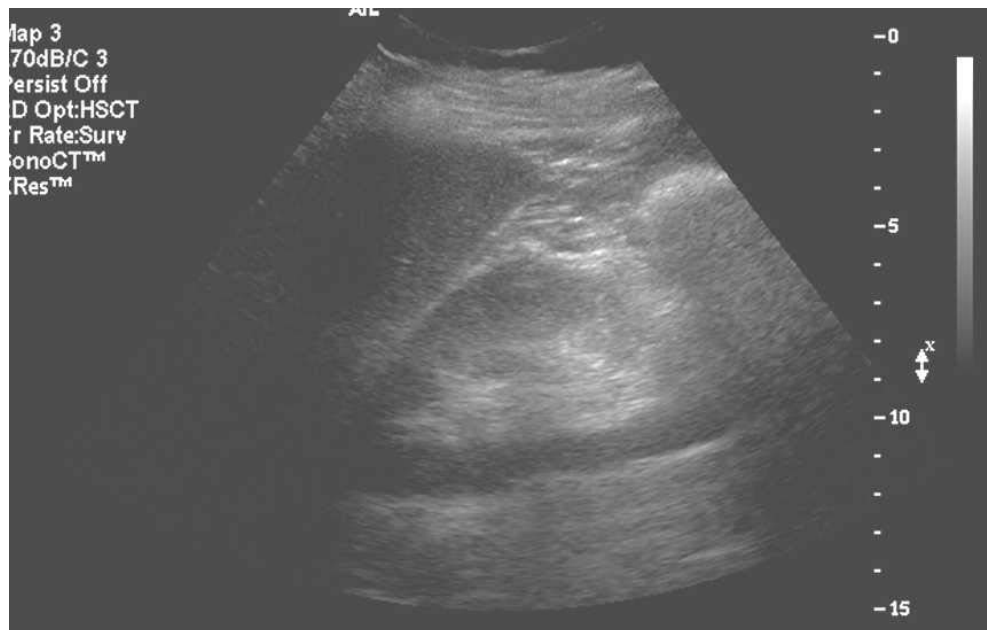Whilst theoretically non-ionising radiation is safe for use during pregnancy, in practice only Ultrasound is used. In all other imaging situations, it is crucial to ask female patients between the ages of 12 - 55 about sexual activity, contraception and the likelihood of pregnancy. In minors, such questioning must be done tactfully, with a female chaperone on hand, and without the patient's parents.

Some isotopes are excreted via the kidneys and bladder, so in patients suffering from urinary incontinence, care must be taken not to contaminate their bedding, chairs and so on, even with short  $t_{1/2}$  isotopes. This is more important when patients are treated with longer  $t_{1/2}$  isotopes such as  $^{131}\text{I}$ .

X-rays and gamma rays are both examples of ionising radiation, in comparison with Ultrasound and MRI which are non-ionising and so do not (theoretically) cause any cellular damage, and are thus safer.

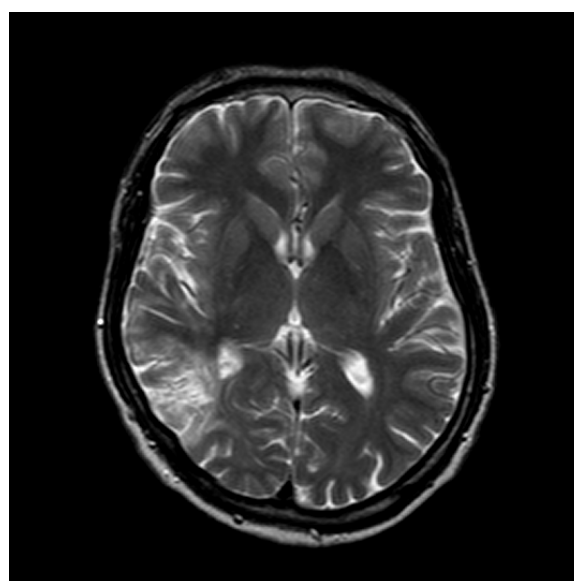
The most widely used non-ionising radiation imaging is Ultrasound, in which sound waves are emitted from a transducer and reflected back in varying amounts from every anatomical interface, detected, and an image produced. Ultrasound waves are totally reflected by bone or calcium-containing structures such as gall stones, which appear white and cast an acoustic shadow behind them, and pass totally through liquid such as urine in the bladder, causing acoustic enhancement behind the structure.

The investigation takes place in real time, making the interpretation much easier for the operator.

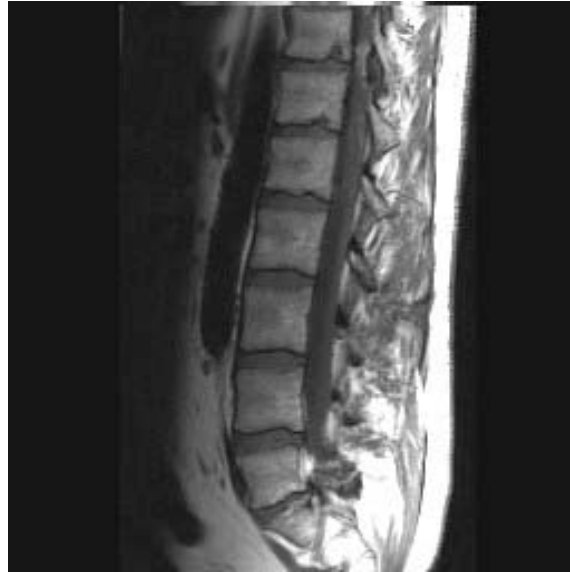

UPPER ABDOMINAL ULTRASOUND SHOWING LIVER AND KIDNEY

MRI does not use ionising radiation, but rather a strong magnetic field to align all the hydrogen protons. The alignment is then disrupted by properly tuned RF pulses. As the protons recover their alignment, they emit radio signals and these can be measured and converted by Fourier transforms in a computer to produce an image. The machine is large with a long central tunnel, in which the patient is placed. The walls are very near the patient to ensure an even magnetic field.



MRI BRAIN SHOWING ALTERED SIGNAL IN RIGHT PARIETAL AREA - STROKE



**LATERAL MRI OF LUMBAR SPINE**

Both US and MRI show anatomical information, but recent advances in MR imaging (fMRI) allow physiological information to be obtained, particularly in the brain.

Due to the intense magnetic field, care must be taken that no magnetic objects are in the room, and the patients have to complete a questionnaire prior to imaging. Such a check list is reproduced here.

### ***MRI PATIENT CHECKLIST***

*Some items can interfere with the examination, some can be hazardous to your health. Please check the following list carefully. Answer all questions. Please do not hesitate to ask staff for help if you have any queries.*

NAME: .....

DATE OF BIRTH: .....

WEIGHT: .....

1. Do you have a pacemaker, artificial heart valve or coronary stent?
2. Do you have aneurysm clips in your head (from a surgical procedure)?
3. Do you have any metal implants e.g. joint replacements, pins, wires?
4. Do you have a cochlear implant?
5. Do you have an artificial limb, calliper or surgical corset?
6. Do you have any shrapnel or metal fragments in your body?
7. Have you ever worked with metal filings?

8. Do you wear dentures, plate or a hearing aid?

9. Have you ever had a fit/blackout, or suffered from epilepsy/diabetes

10. Are you sure you have nothing metal within or about your body?

For women:

11. Do you have an intrauterine contraceptive device fitted?

12. Is it at all possible that you could be pregnant?

Yes/No

SIGNATURE: ..... CHECKED BY:.....

DATE:..... ,.....

DO NOT take removable metal objects into the examination room. This includes:

Keys, Coins, Watches, Jewellery, Hair clips, Hearing aids

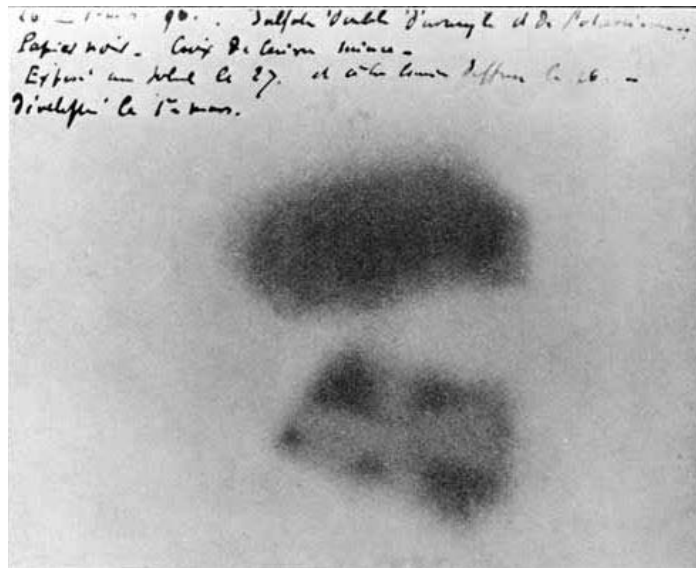
DO NOT take any magnetic media (e.g. bank/credit cards, travel cards, tube tickets) into the examination room. These may be erased if brought into the MR room. Please store these and other valuables in the lockers provided.

For your information:

Loose metal objects can be attracted to the magnet and act like projectiles. Function of the pacemaker can be disturbed.

## HISTORY

Radioactivity was discovered by Henri Becquerel in 1896, whilst investigating phosphorescence in uranium salts. Following the work of Röntgen, Becquerel wrapped a fluorescent substance, potassium uranyl sulphate, in photographic plates and black material in preparation for an experiment, but prior to actually performing the experiment, Becquerel found that the plates were fully exposed. This led Becquerel to investigate nuclear radiations, and in 1903 he shared the Nobel Prize for physics with the Curies.



From Wikipedia

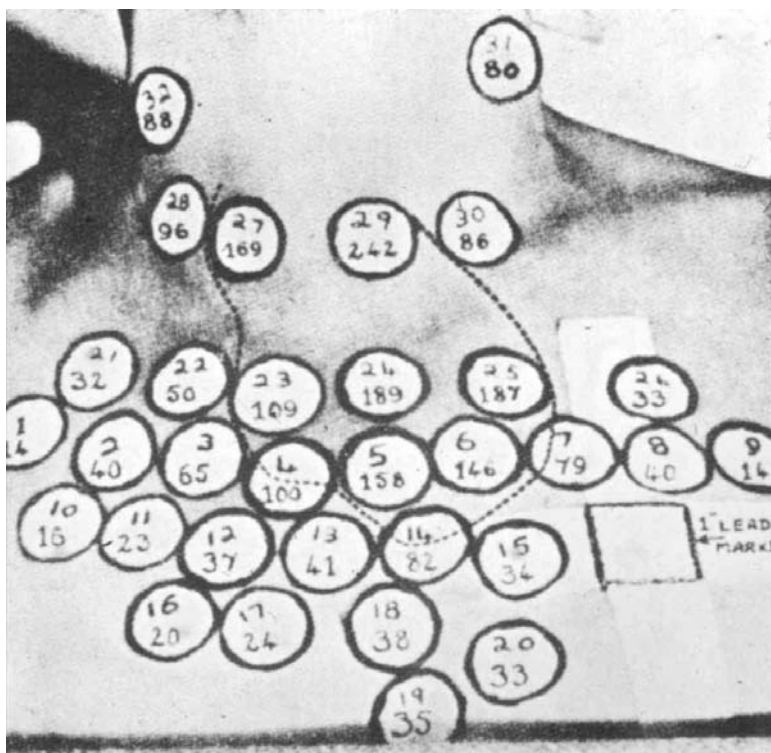
Image of Becquerel's photographic plate which has been fogged by exposure to radiation from a uranium salt. The shadow of a metal Maltese Cross placed between the plate and the uranium salt is clearly visible.

In honour of his work, the SI unit of radioactivity is the becquerel Bq. However, the earlier, non-SI, unit was the curie (symbol Ci), and the mCi is still used as the measure of radioactivity in the USA. The curie is a unit of radioactivity, defined as  $1 \text{ Ci} = 3.7 \times 10^{10}$  decays per second. This is roughly the activity of 1gm of  $^{226}\text{Ra}$ , a substance studied by the Curies. The becquerel (Bq) equates to one decay per second.

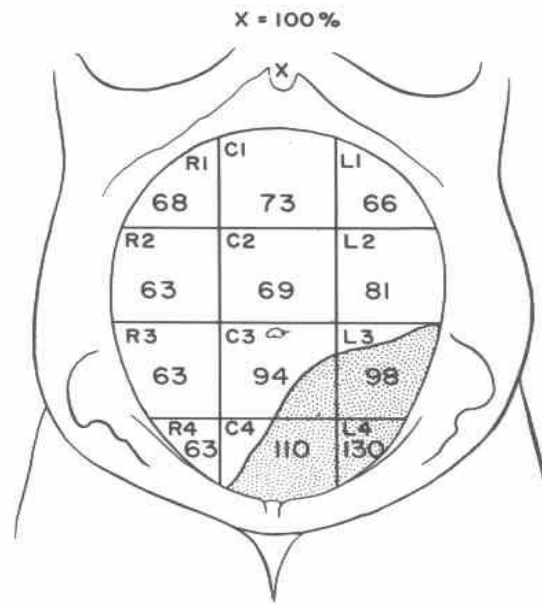
A measurement in Bq is proportional to activity. As any SI unit, Bq can be prefixed; commonly used multiples are KBq ( $10^3 \text{ Bq}$ ), MBq ( $10^6 \text{ Bq}$ ) and GBq ( $10^9 \text{ Bq}$ ). In human diagnostic work the administered activity is in MBq, but in therapy it may well be in GBq. In Veterinary work, especially in horses, the administered activity is in GBq.

Isotopes were originally used for physiological measurement, particularly by von Hevesy (1911) who wrote "The coming Sunday in an unguarded moment I added some deposit to the freshly prepared pie, and on the following Wednesday, with the aid of an electroscope I demonstrated to the landlady the presence of the active material in the soufflé", and more seriously used them in blood flow measurements (1923). Progress was slow until Fermi split the atom, and reactors were developed, and the most useful uranium breakdown product at that time was  $^{131}\text{I}$  which was used to find thyroid tissue using Geiger counters, and to treat thyroid disease.





Interestingly, localization using counters was still performed in the 1950s for placental localisation.

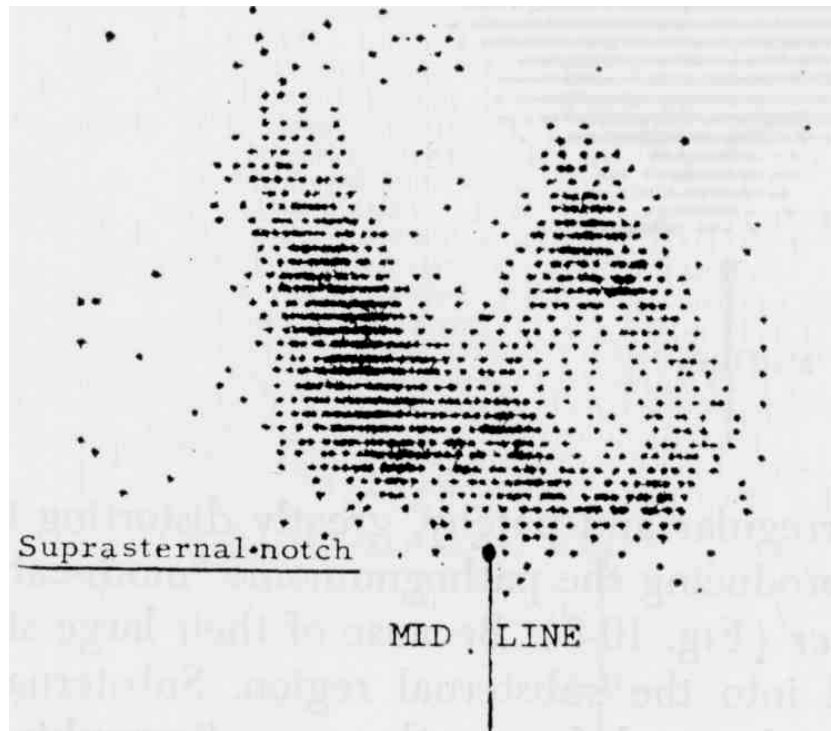


**Fig. 17-22.** A typical record illustrating increased radioactivity over sections C3, C4, L3, and L4. The diagnosis of placenta previa was confirmed at Cesarean section. [After D. L. Hutchinson et al.: Surg. Gynec. Obstet. 107:370 (1958).]

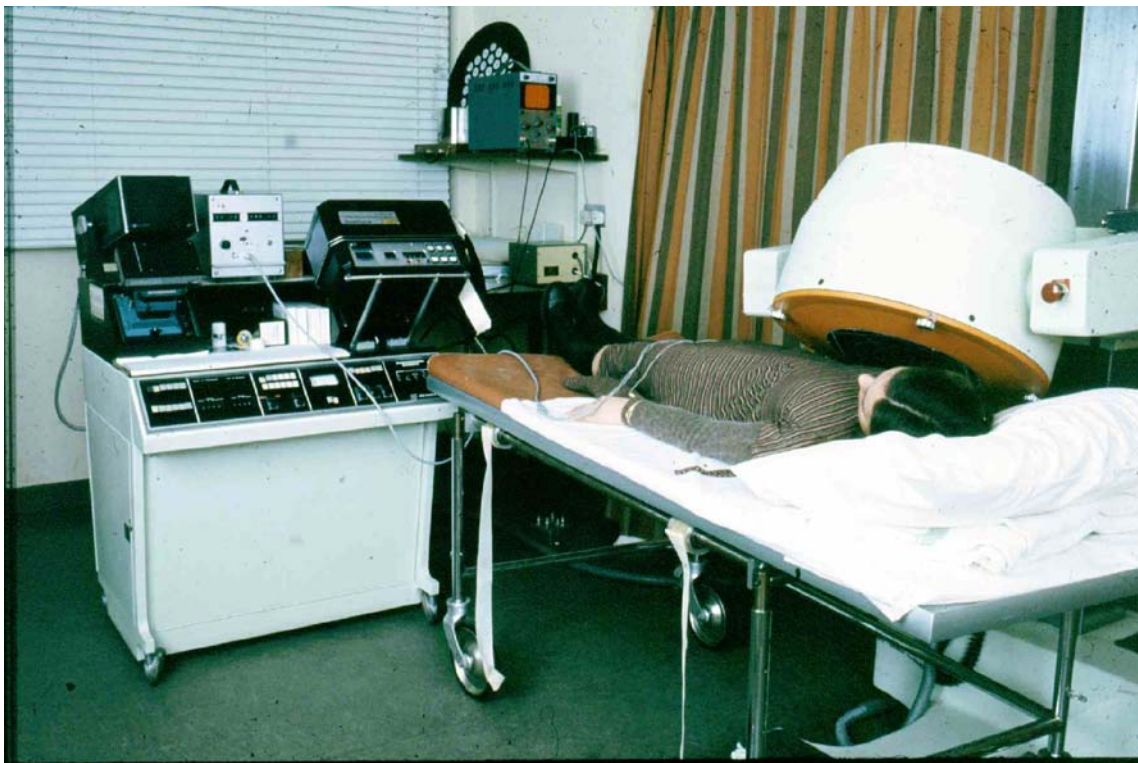Of course, this has been totally superseded by Ultrasound and is the proof of Norman Veal's dictum 'the best nuclear medicine physiological test involves no isotopes'.

Rectilinear scanners became available in the 1960s, and produced life-size images, albeit very slowly.

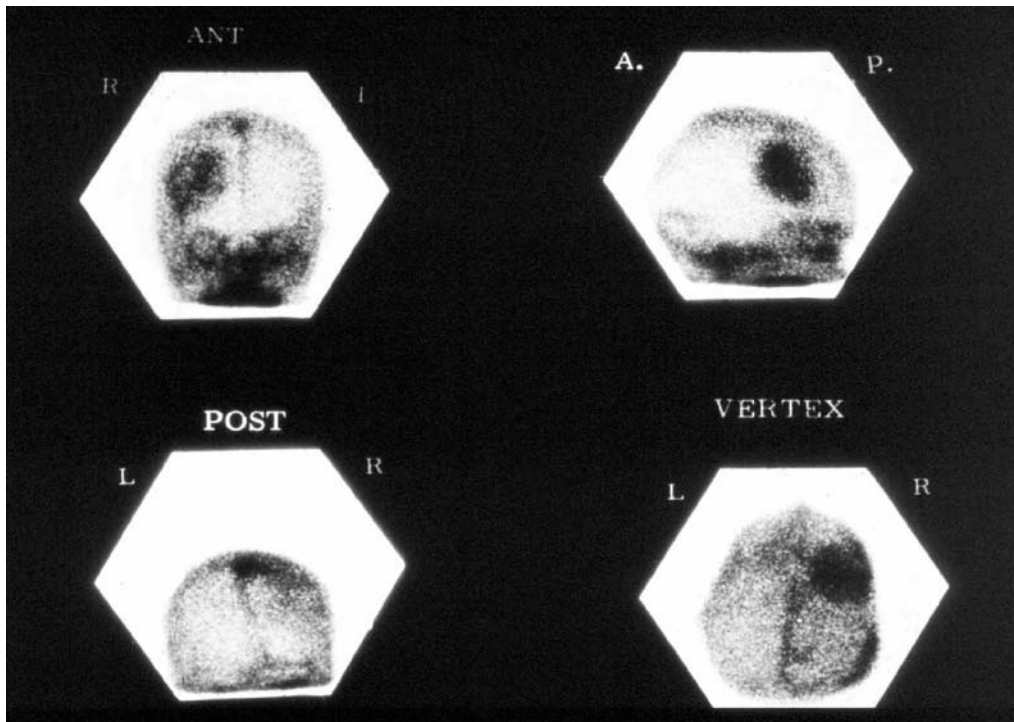




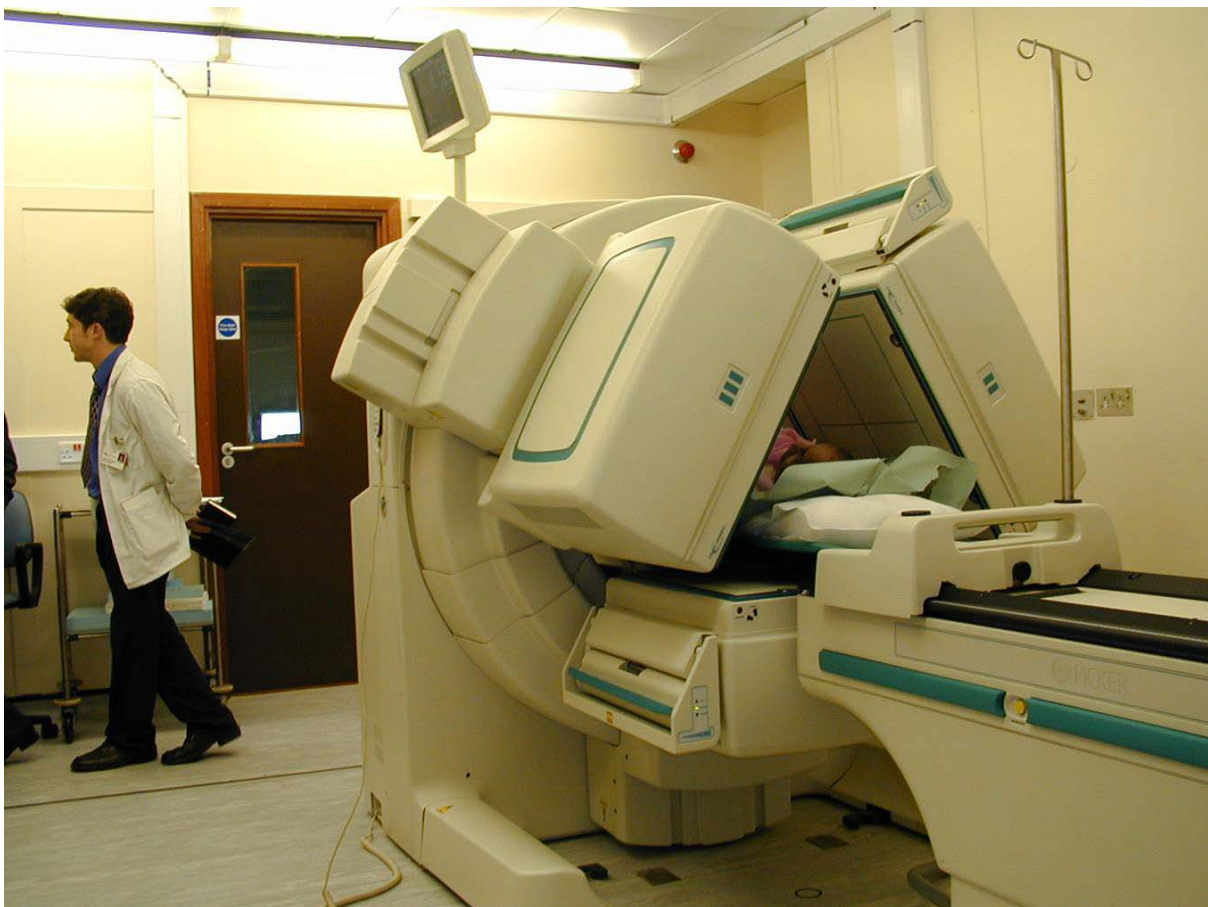In the late 1960s Anger devised the gamma camera, again initially slow in that it took single views only, but over the next three decades has developed into the modern multi-headed SPECT camera.



Gamma camera 1973



Brain scan 1974

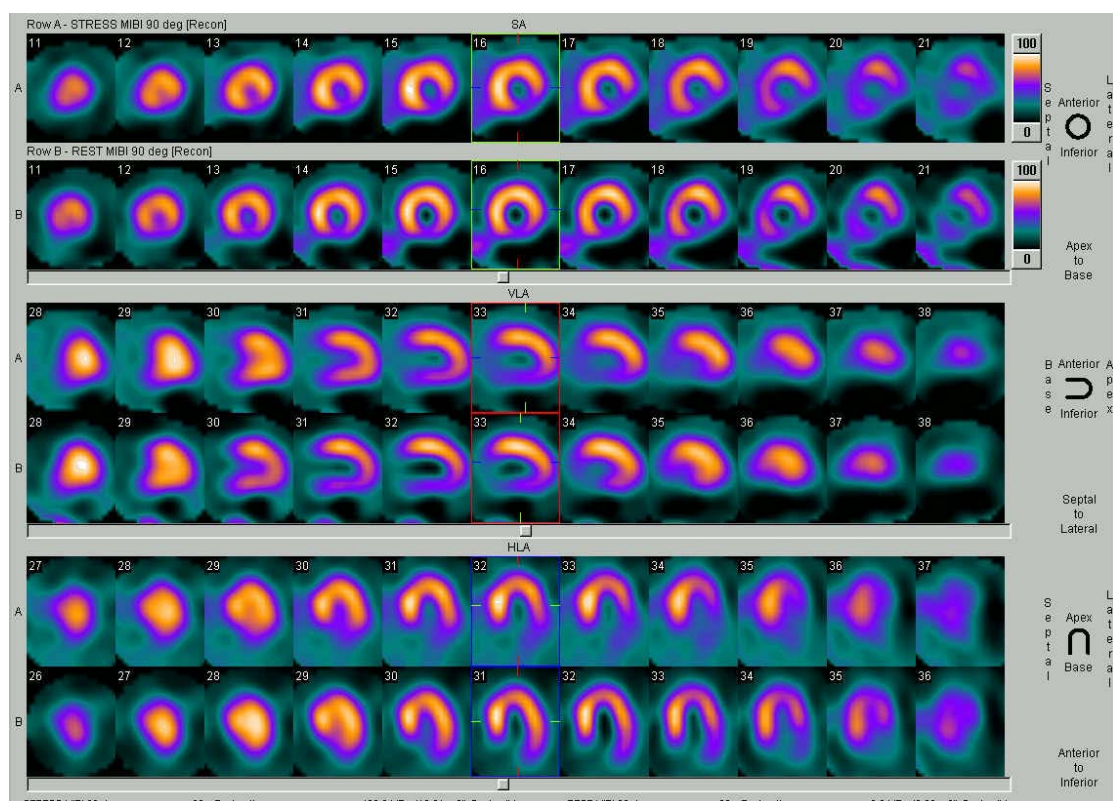
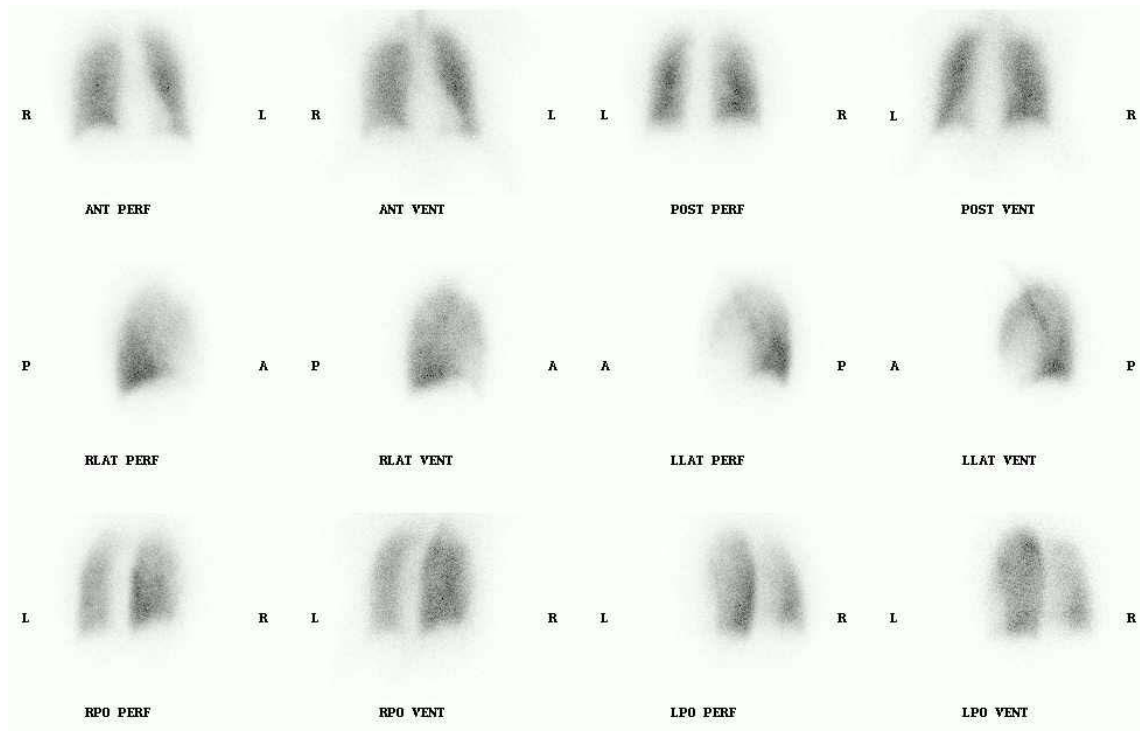


Modern triple-headed SPECT camera

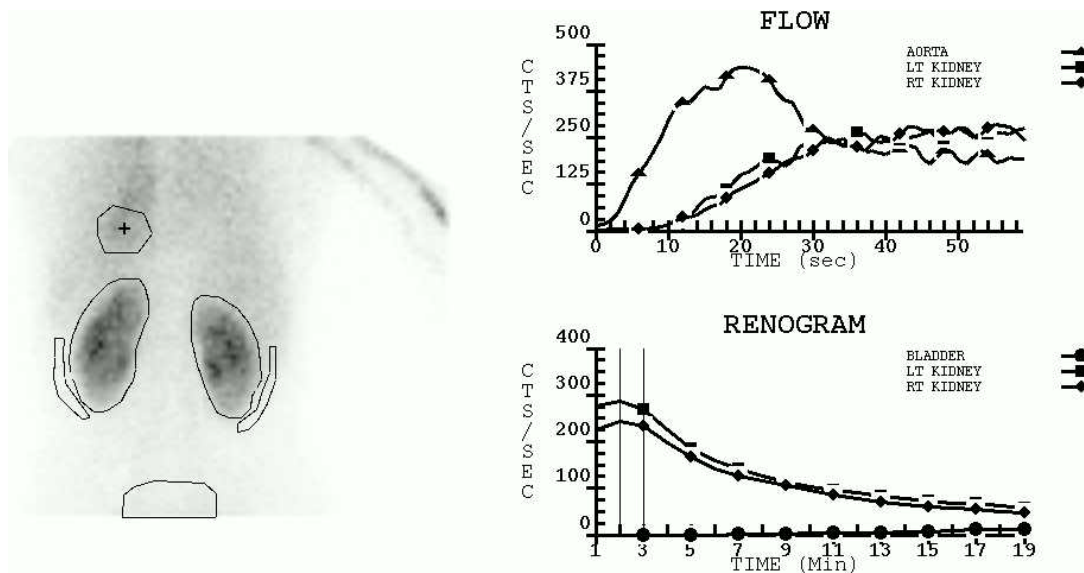


Needless to say, the other major advance in all aspects of imaging is computer development, as can be seen in CT, MRI and of course Nuclear Medicine.

All the above images courtesy of Dr Andrew Hilson, Royal Free Hospital, London



These are examples of current static and tomographic computer-produced Nuclear Medicine images. As well as these, the camera can also acquire dynamic images. In these, the computer is instructed to acquire a certain number of frames in sequence, and then regions of interest can be drawn, and time/activity curves obtained. The commonest study of this type is the renogram.



As all modern images are digital, the major advance in image presentation and distribution is PACS, which allows rapid dissemination of the image and the report within the hospital, and also more widely by the use of security-encrypted teleradiology computer systems which allow the images and reports to be seen at distant hospitals.

# CLINICAL STUDIES

## *BONE AND INFECTION*

### **Principles**

Bone disease may be regarded as either congenital or acquired. Most bone disease needs high quality anatomical imaging, involving radiography, CT or MRI. Nuclear Medicine studies are best undertaken when physiological information is required.

Bone imaging is the commonest form of Nuclear Medicine imaging - see pie chart on page 152.

### **How to perform the nuclear medicine tests**

There is no special patient preparation, but as the isotope is excreted via the kidneys, if the patient is incontinent, then the department must be informed and it may well be advisable to catheterise the patient. The isotope used is usually a  $^{99m}\text{Tc}$  labelled bisphosphonate injected intravenously. The standard adult dose is 600MBq.

Conventional bone scans can be either planar or tomographic (SPECT). The labelled bisphosphonate is taken up in the bone and adequate blood flow and osteoblastic activity are needed.

There is no special preparation for bone scanning.

### **Indications**

The most common reason to image the skeleton is in malignant disease, searching for metastases. Other important indications are trauma, infection, metabolic bone disease, degenerative and vascular bone disease.

### **Contra-indications**

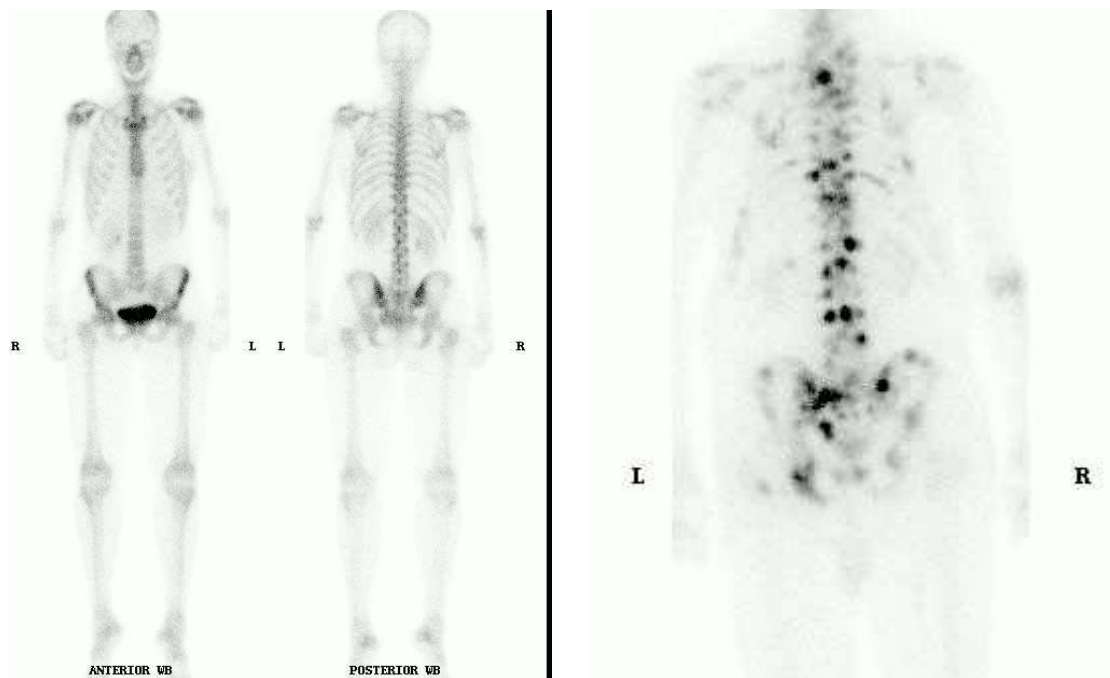
Pregnancy. Breast-feeding.

### **Diagnostic algorithms**

- Congenital bone disease - high quality radiography, MRI
- Metastatic disease - bone scan using a  $^{99m}\text{Tc}$  labelled bisphosphonate for a whole body survey. MRI for further local information
- Trauma - conventional x-ray or CT. Bone imaging useful in difficult cases such as scaphoid fracture or stress fractures where the x-ray may be normal

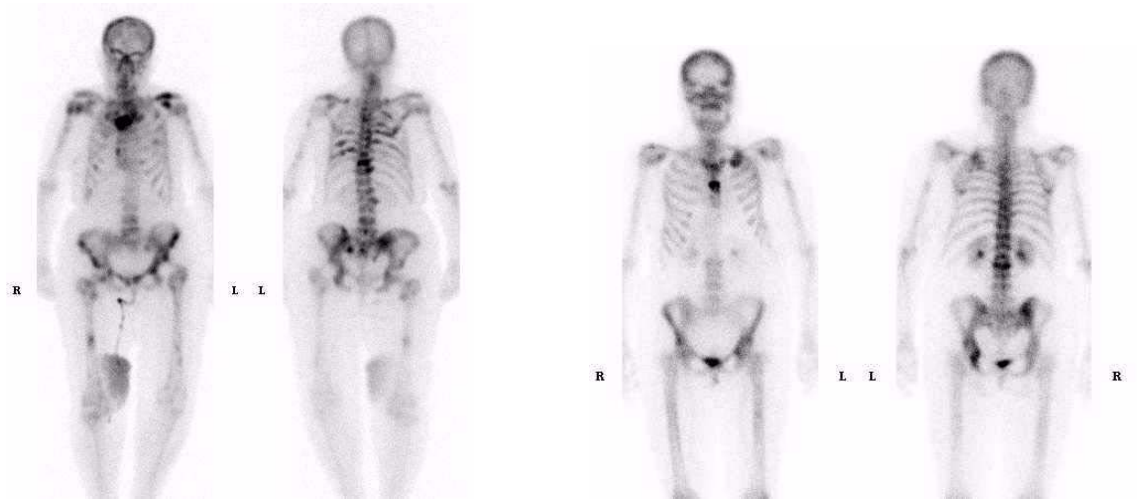
- Infection -  $^{99m}\text{Tc}$  HMPAO labelled white blood cells,  $^{99m}\text{Tc}$  labelled Leukoscan (anti-WBC antibodies) or  $^{18}\text{F}$ -FDG PET/CT. With a positive result, MRI, CT or US with aspiration of any abscess for microbiology may be required
- Metabolic bone disease - CT or MRI, reserving bone imaging for difficult cases
- Degenerative disease - conventional x-rays, but bone scan (SPECT or SPECT/CT) of spine may be extremely helpful in showing areas of active inflammatory disease
- Vascular bone disease - bone imaging may be helpful, but MRI better

## Examples

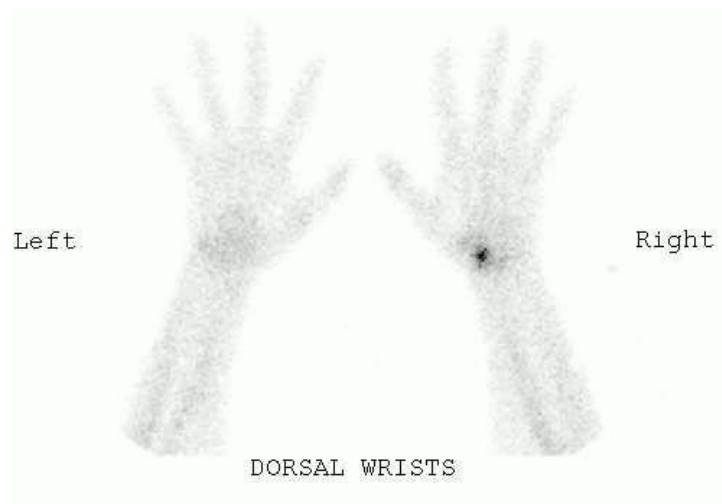
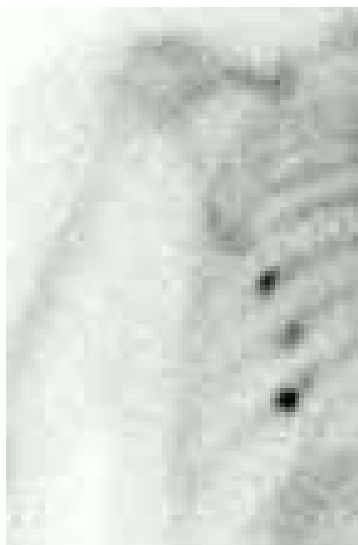
The image on the left is a normal adult skeleton; that on the right shows multiple metastases. Metastases are normally seen in the central skeleton in an irregular distribution, unlike fractures which are either isolated or in a linear distribution, particularly in the ribs.





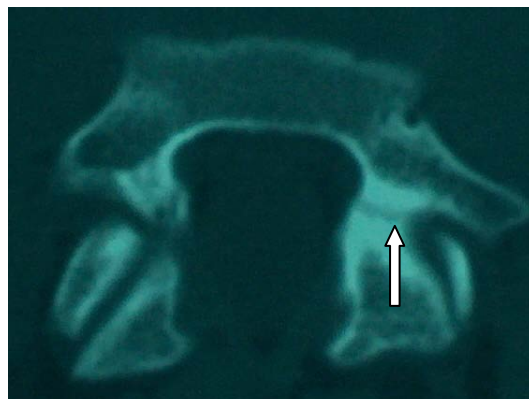
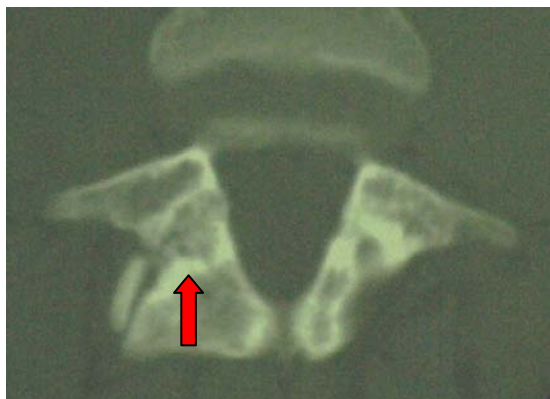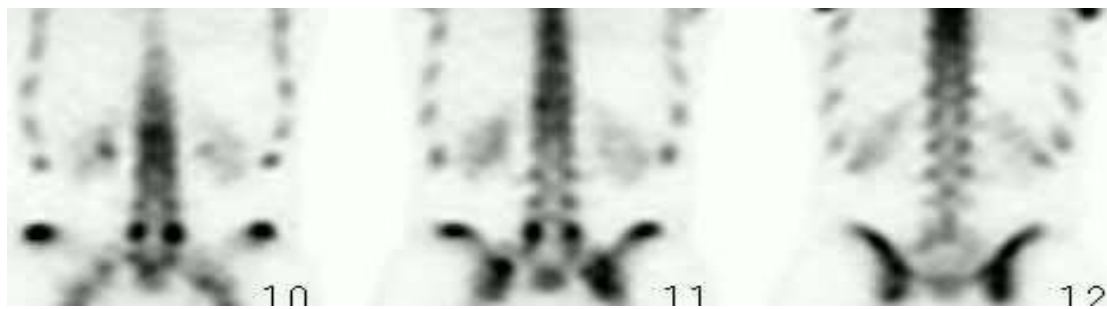
The two images above also show metastatic bone disease. The images below show, on the left, a linear arrangement of areas of punctate increased uptake, typical of fractures, and on the right an area of increased uptake in the right scaphoid, again due to fracture.



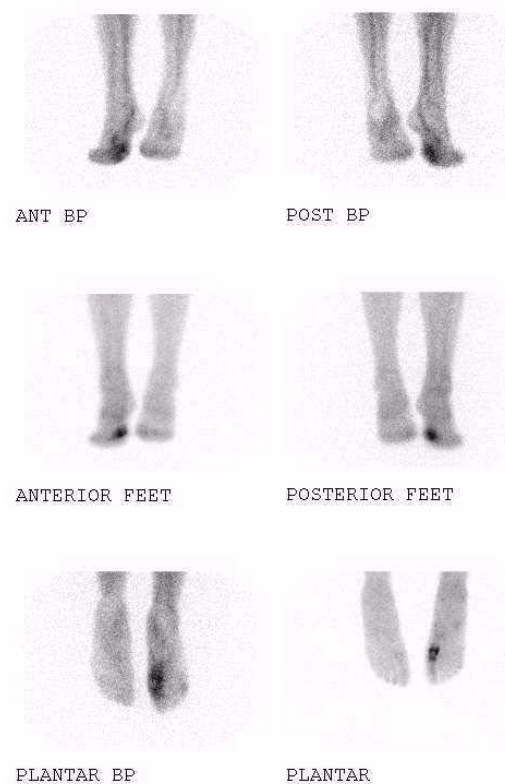
Obviously, a complete patient history is needed to make an accurate diagnosis.

These are all examples of planar images, and SPECT is used to reveal extra information, particularly in the spine.

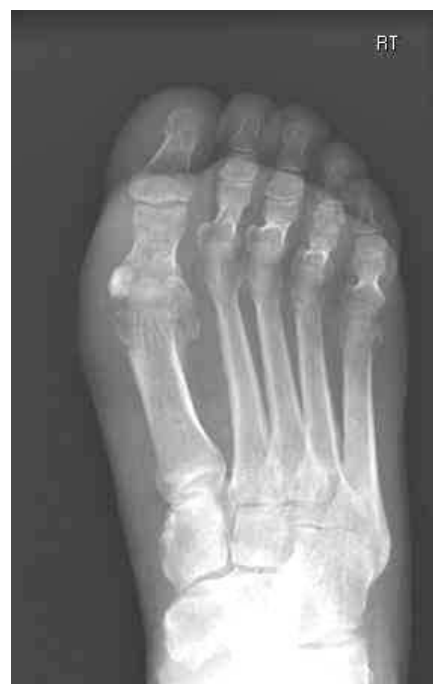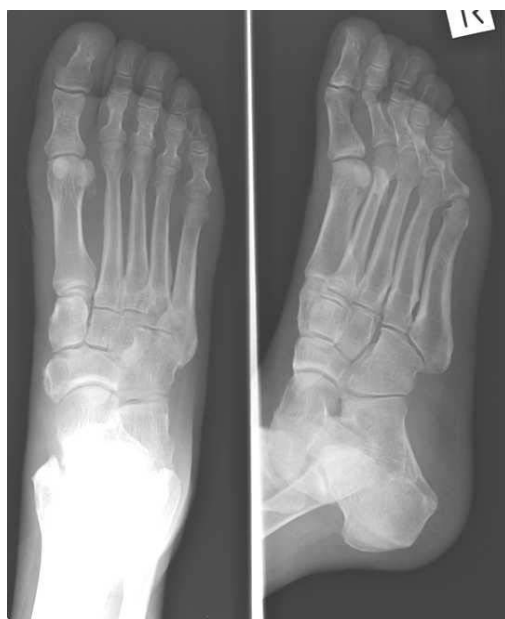This case of a young ballet dancer with low back pain showed minimal abnormality on the planar images, but the SPECT showed markedly increased activity in the region of the pares interarticularis, and fractures were confirmed on the CT (arrows).

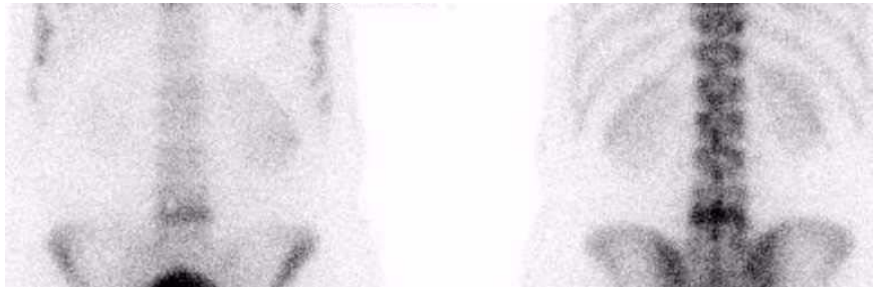

Infective change is also well demonstrated using Nuclear Medicine techniques.

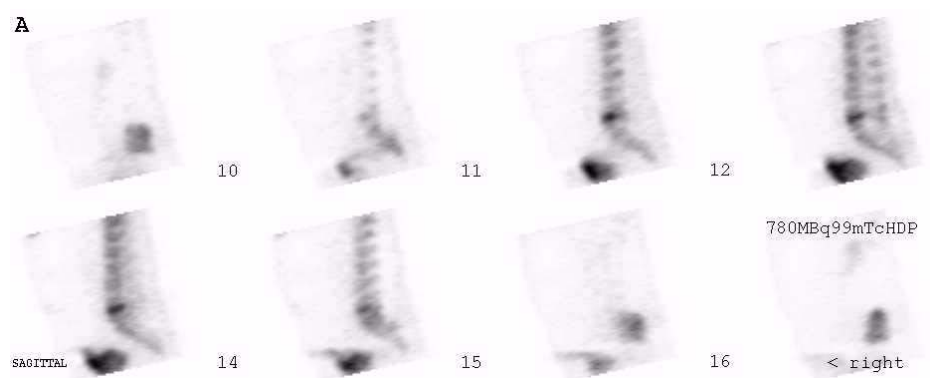


The above images show the feet of a diabetic. There is obviously increased activity in the first toe both on the blood pool (BP) and later images, typical of osteomyelitis. The radiograph at this time was normal (on the left); only later did the bone destruction become apparent.

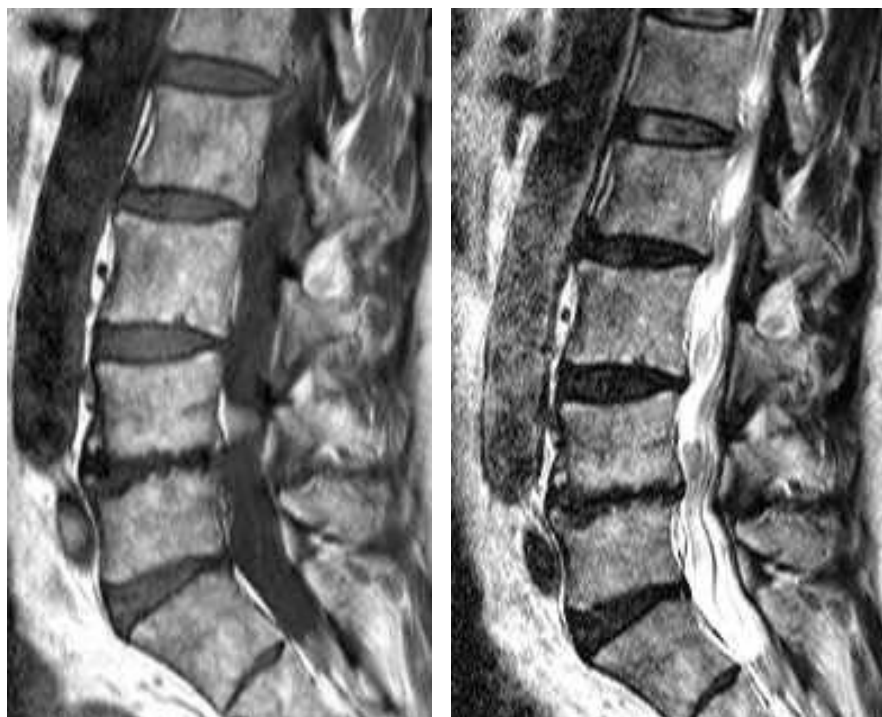




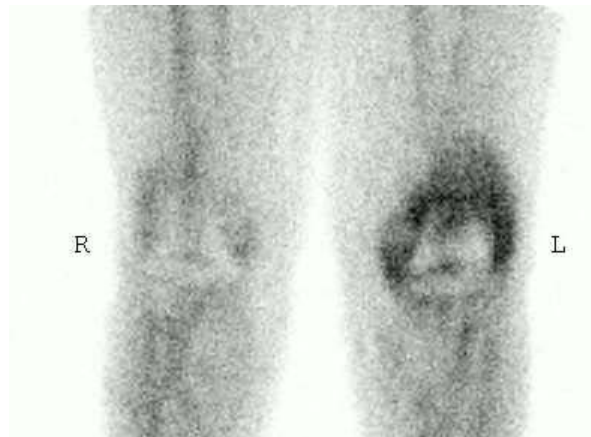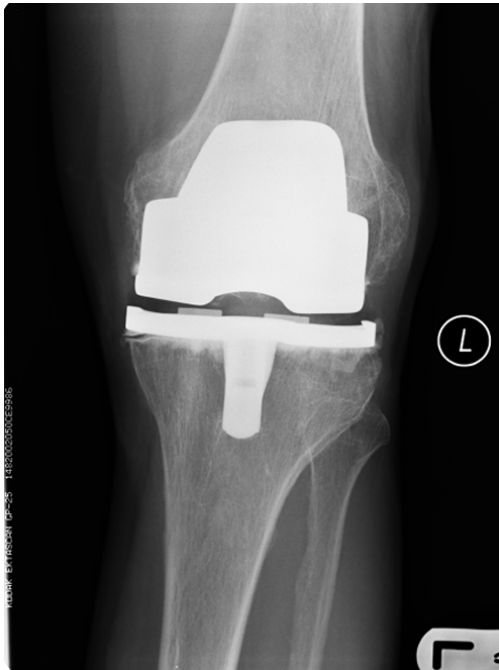This planar image of a patient with lower back pain due to discitis shows increased activity at about L4/5, and this is confirmed on the SPECT images.



These images show the physiological distribution of disease, but the anatomy is here best shown on MR.

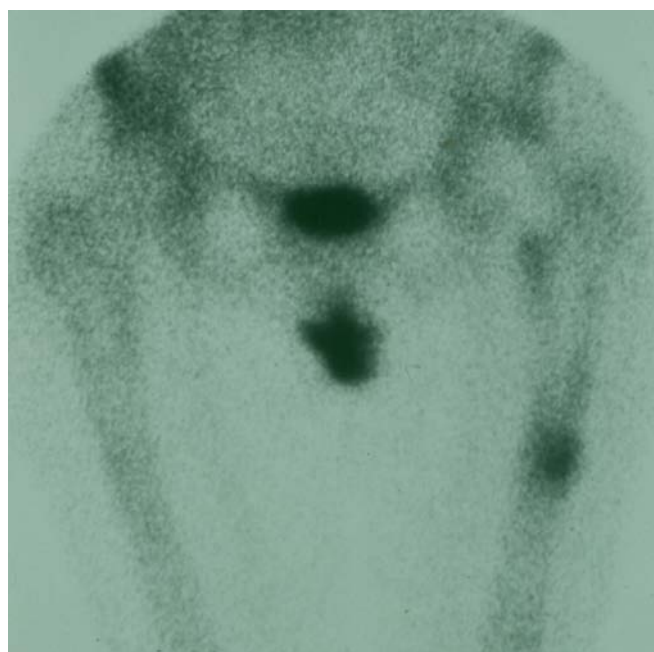
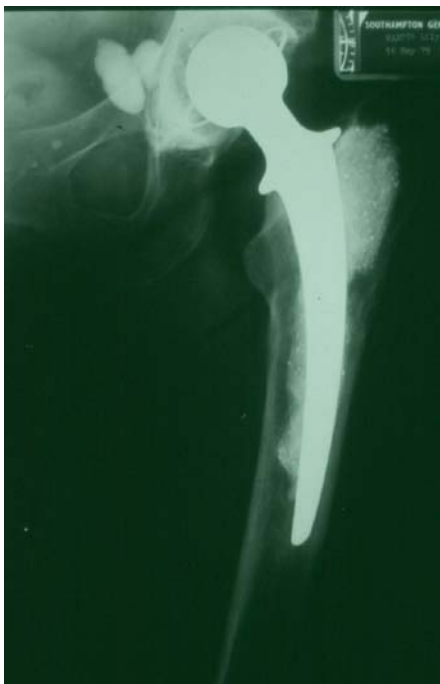
A common problem occurring in patients with joint prostheses is pain, and bone imaging can help differentiate loosening from infection.

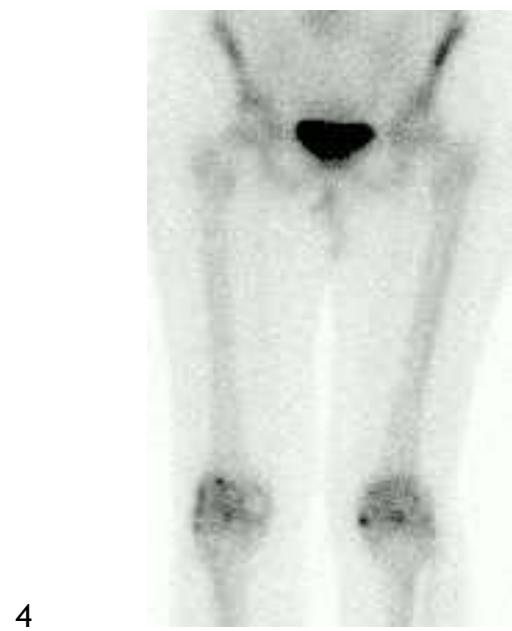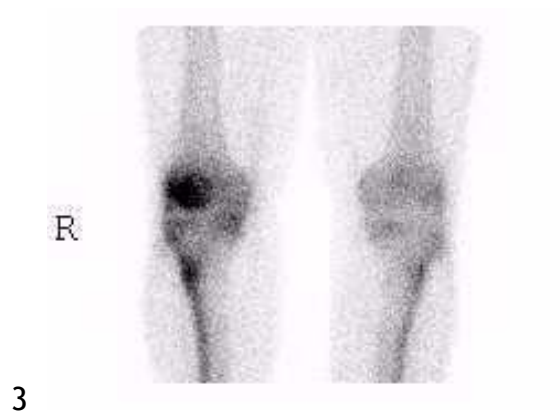

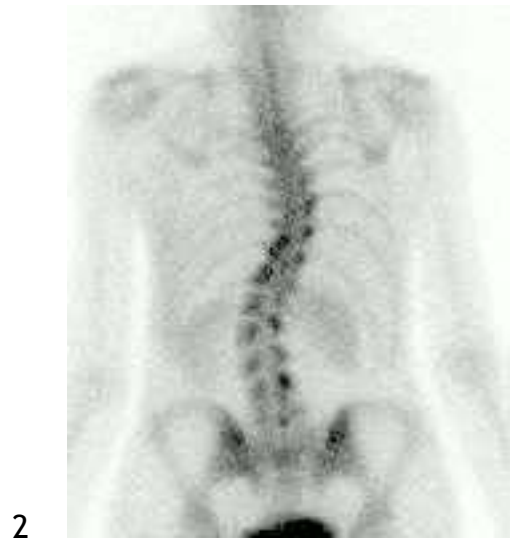
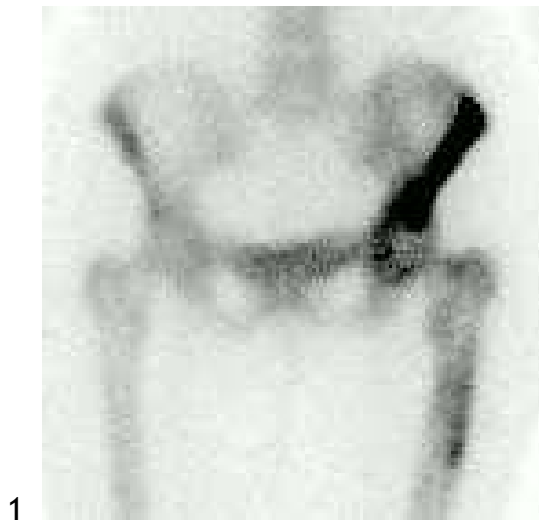The x-ray shows a left total knee replacement, which was painful. The x-ray shows no obvious bone destruction, but the scan shows increased uptake associated with the femoral component of the prosthesis. This type of scan uses labelled  $^{99m}\text{Tc}$  labelled antibodies to white cells, rather than a conventional bone scan.

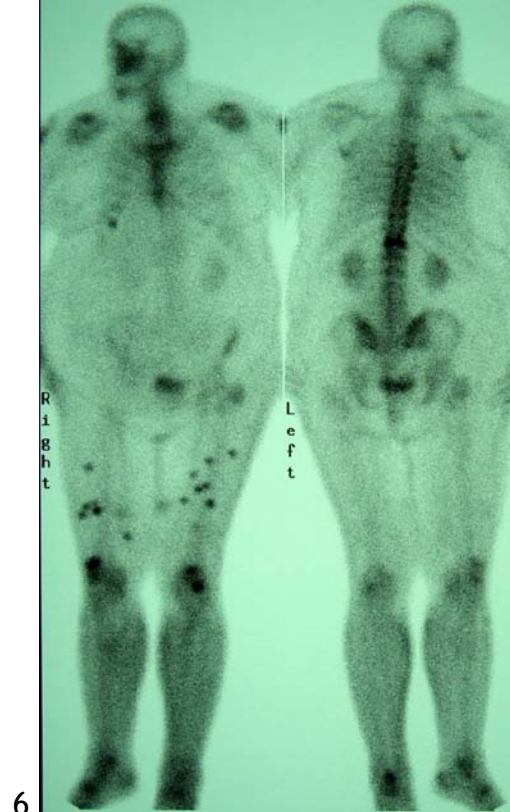
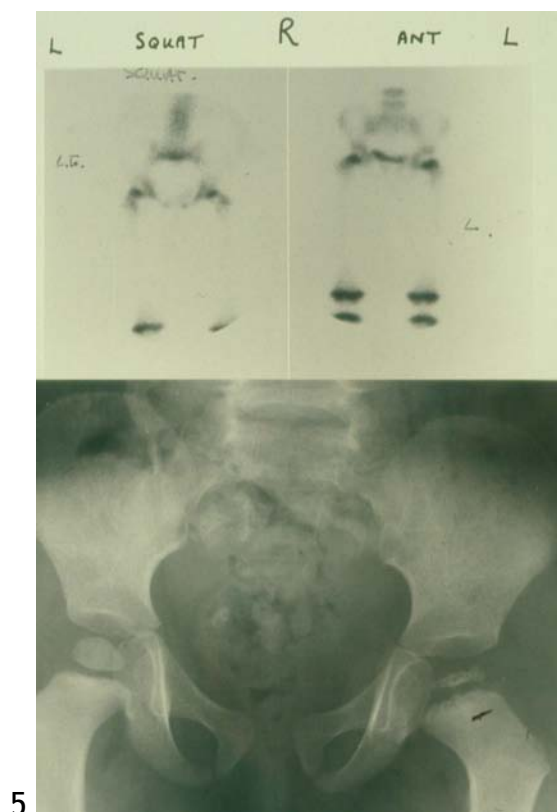This x-ray shows a cemented left total hip replacement, which was painful. The bone scan shows focal increased uptake at the tip of the stem of the prosthesis, typical of loosening.



Other uses of bone imaging are in metabolic bone disease such as Paget's disease, degenerative disease and vascular bone disease such as infarcts or Perthe's disease, as below.





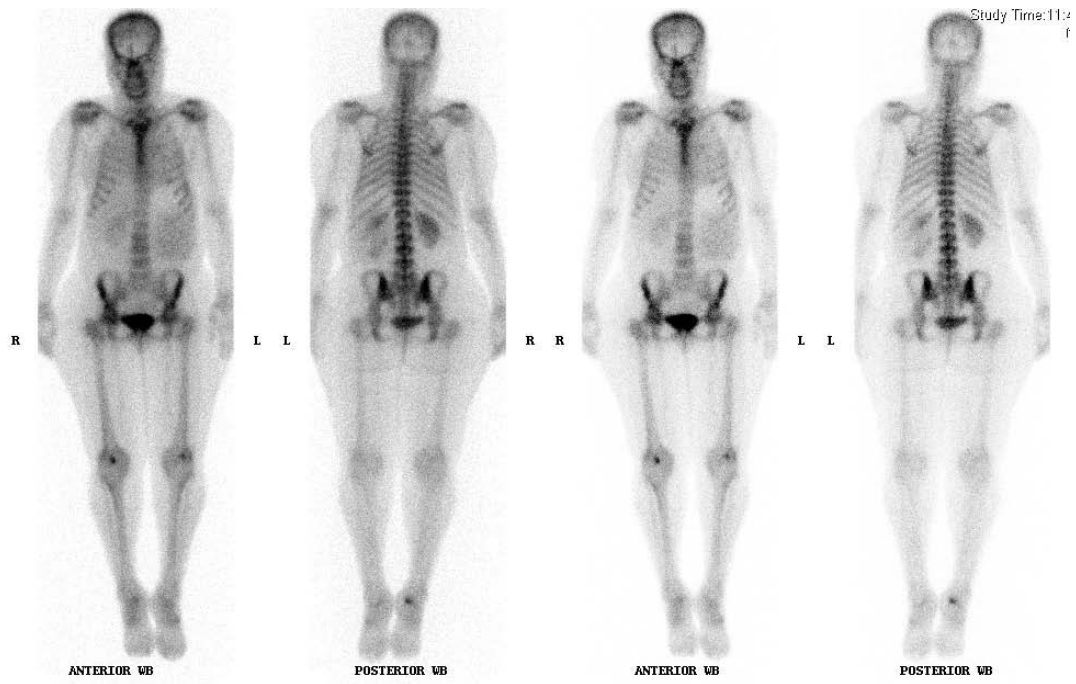


1 = Pagets disease of the left pelvis, 2 = kyphoscoliosis with degenerative change, 3 and 4 = degenerative changes in knees, 5= Perthé's of the left hip in a child, 6 = a diabetic lady with abnormal sites of uptake in the thighs, due to the insulin injections

### Incidental findings

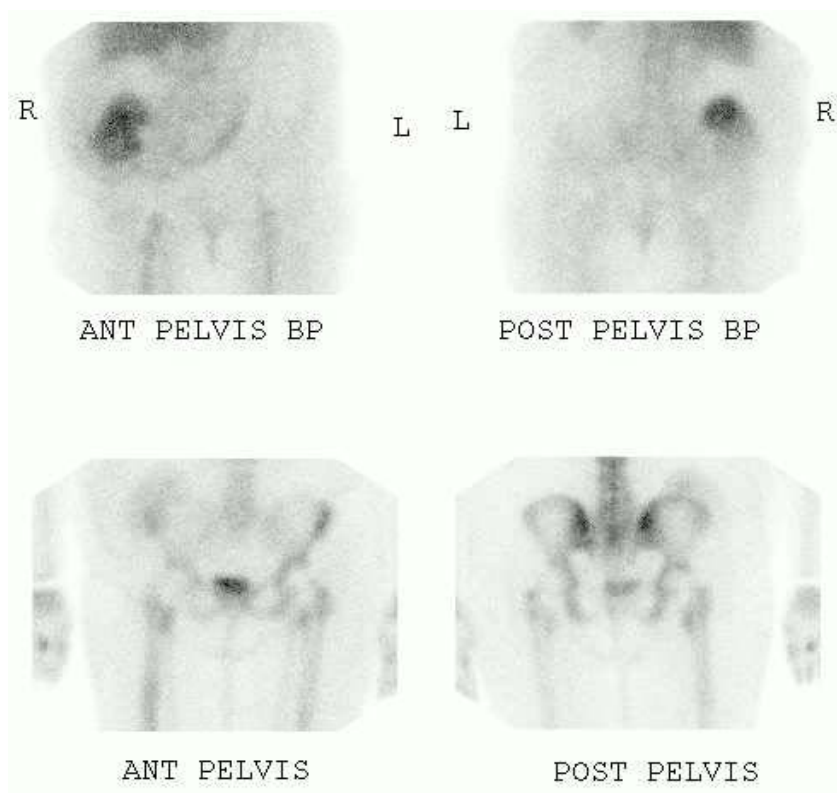
These may also be seen on bone scans. In the examples below,

1 shows a filling defect in the mid-pole of the left kidney due to a renal tumour, 2 shows a right pelvic renal transplanted kidney (and a left total hip replacement), 3 shows myocardial uptake in a lady receiving herceptin for breast cancer (a large number of anti-cancer drugs are cardiotoxic) and 4 shows bone agent taken up in an unsuspected right breast cancer.



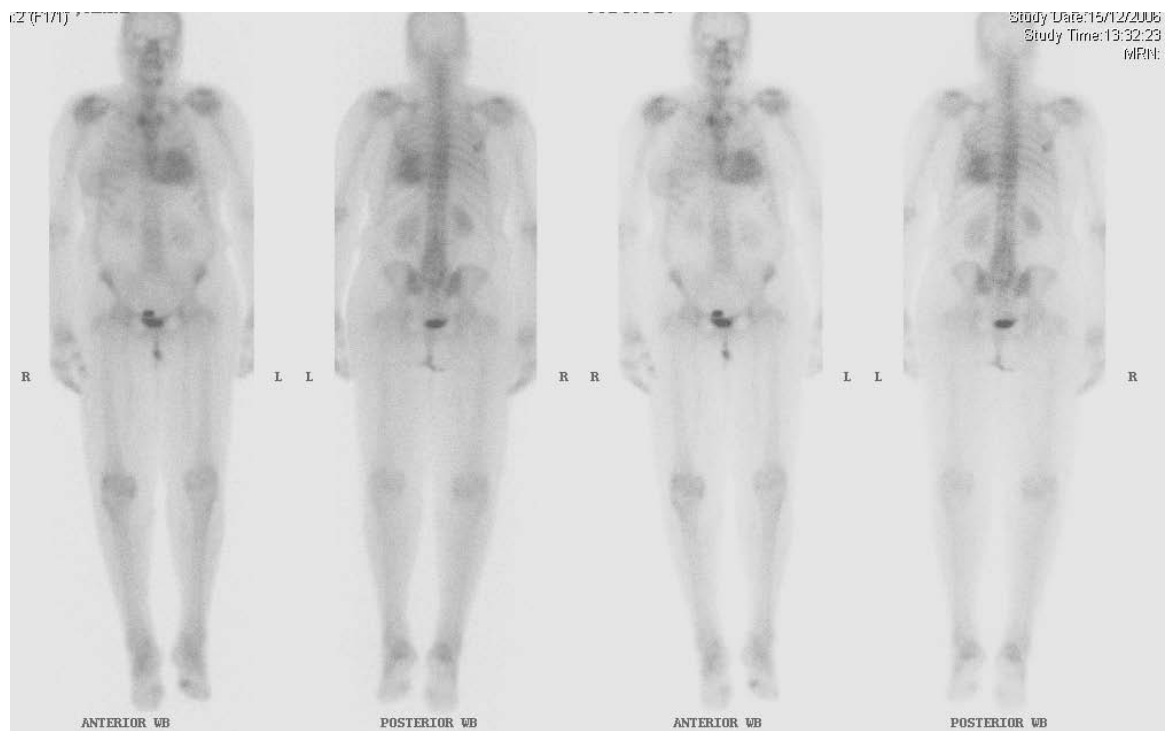
1 Charing Cross Hospital

563.0 MBq 99mTc HDP

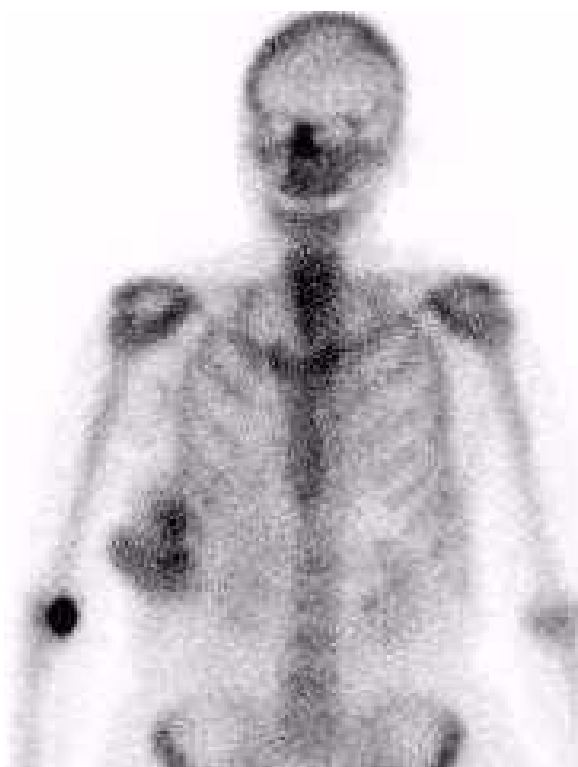

2



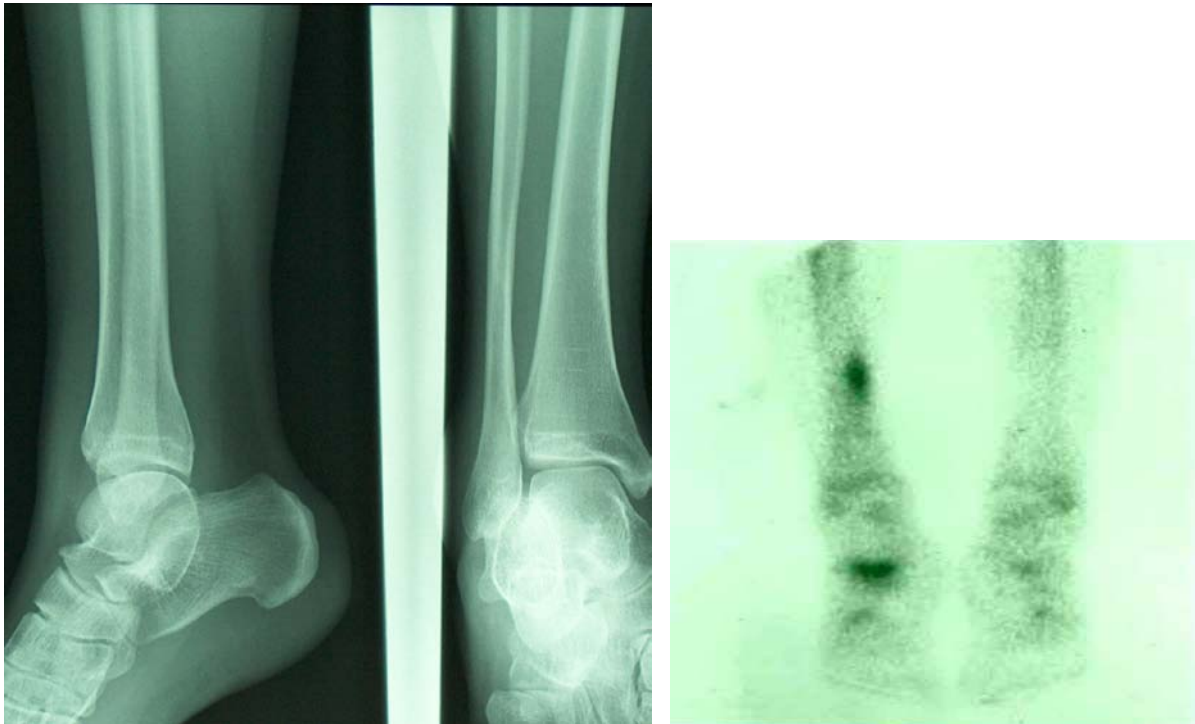

3



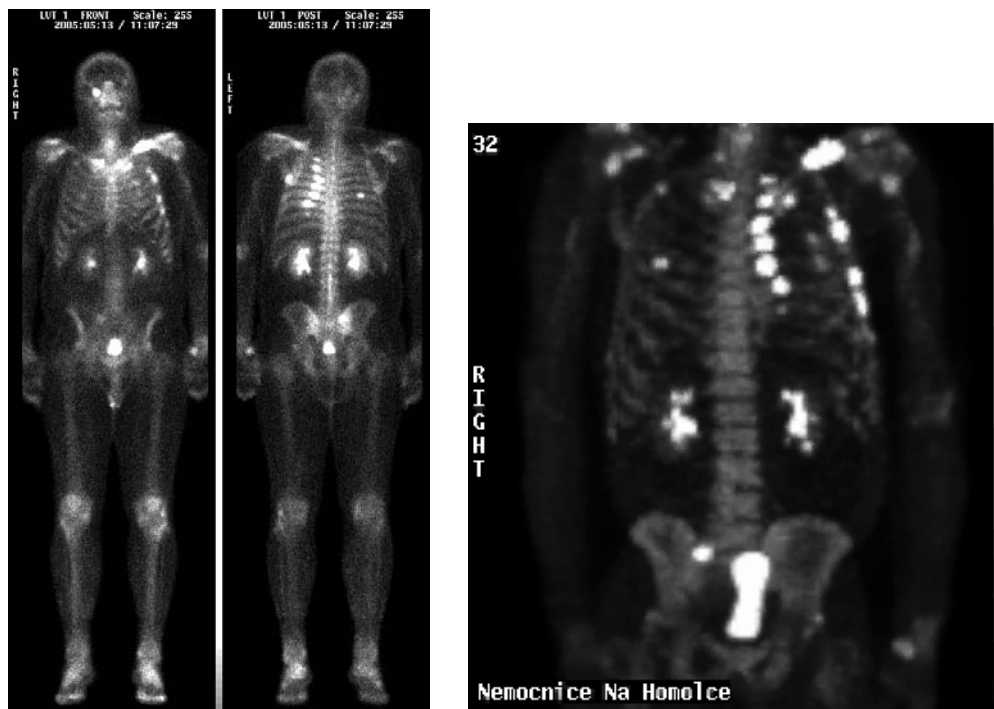
4

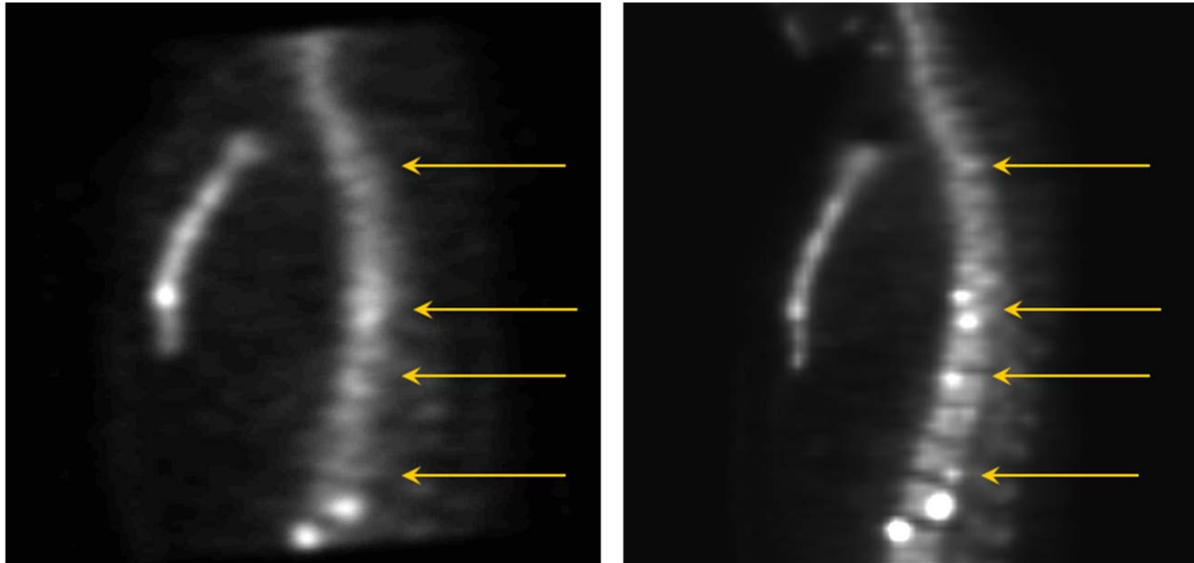
Sports injuries are often better investigated with bone scans which are much more sensitive to periosteal or slight bone damage than x-rays.



These images of a stress fracture show a normal x-ray but abnormal uptake in the mid right tibia at the fracture site.

All these bone images are obtained using a  $^{99m}\text{Tc}$  labelled bisphosphonate, but the skeleton can also be imaged using  $^{18}\text{F}$  as fluoride ( $\text{NaF}$ ), which is a PET emitter. The standard dose is 250MBq.





Courtesy of Professor Otakar Bělohlávek, PET Centre, Na Homolce Hospital, Prague

These images show a conventional  $^{99\text{m}}\text{Tc}$ -MDP image on the left, and a  $^{18}\text{F}$  NaF image on the right, and the lower ones show how much better the  $^{18}\text{F}$  demonstrates the metastases.

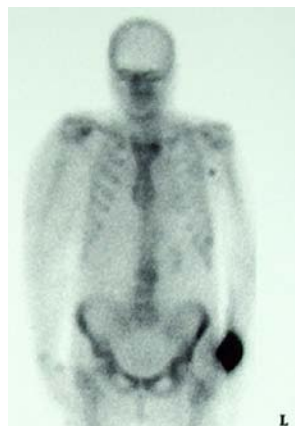
## BREAST

### Principles

There is relatively little place for Nuclear Medicine in first-line breast imaging, which is done with conventional x-ray mammography to find breast cancer. Remember that there are two main avenues with mammography - population screening, normally in women over 55, and symptomatic mammography where the woman presents with a breast lump on palpation, or other symptoms such as nipple inversion or bleeding.

### How to perform the nuclear medicine tests

There are 2 main uses of nuclear medicine in breast disease. For defining breast cancers, the agent used is sestamibi, labelled with  $^{99m}\text{Tc}$ . The administered dose is 900MBq. Sestamibi is a tumour-seeking pharmaceutical, taken up by breast cancer and axillary nodal deposits. It is injected into a vein on the foot, the reason being that any extravasation is trapped by lymph nodes in the knee or groin. If the injection were in the arm, then the extravasation would be trapped by lymph nodes in the axilla and may erroneously suggest axillary deposits. The images are 'all or nothing' - if uptake is seen, then it is in a tumour.



In the image above, there has been extravasation at the injection site in the dorsum of the left hand with activity seen in the left axilla.

The other main use of Nuclear Medicine in breast cancer is in sentinel node imaging. Between 20 and 40 MBq  $^{99m}\text{Tc}$ -labelled nanocolloid is injected intradermally above the tumour and images obtained. The administered dose depends on whether the operation is the day of imaging or the next day. The first node visualised is the sentinel node, and this is removed at surgery to see whether it contains metastatic disease. Knowledge of this alters further treatment of the disease.

At operation, the sentinel node is identified using a gamma probe operated by the surgeon.

There is no special patient preparation required for either test.

### **Indications**

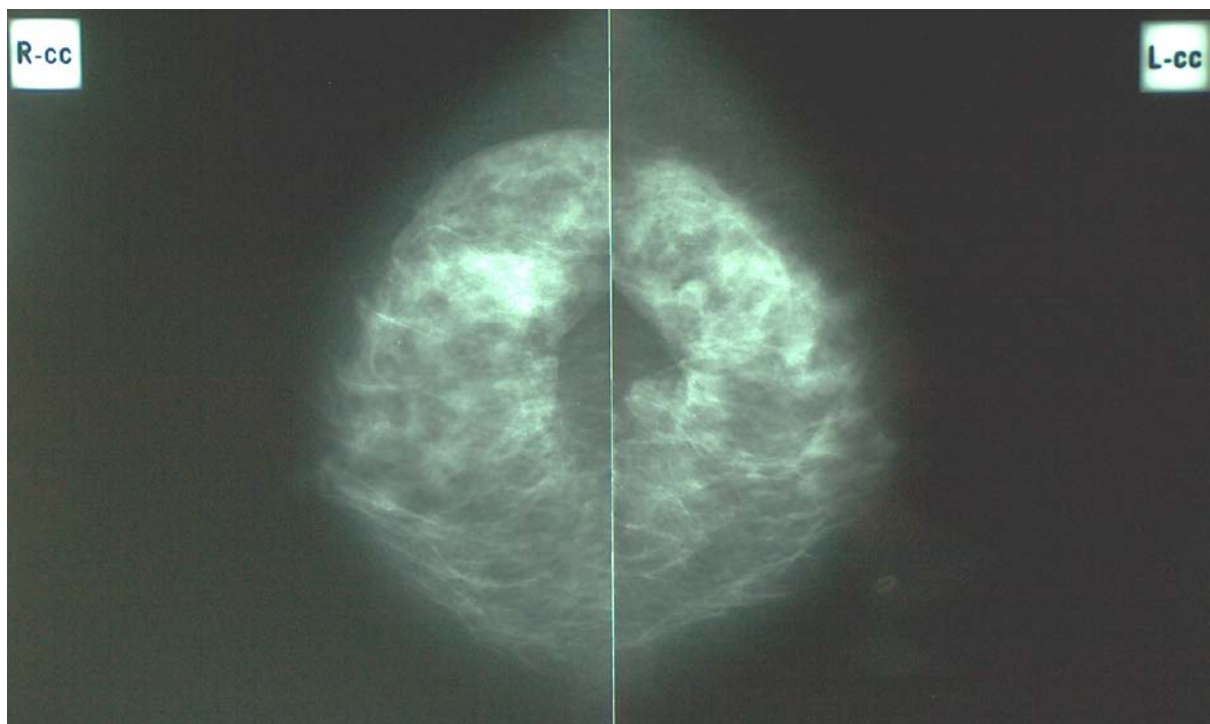
Nuclear Medicine imaging is used as a second-line investigation, in women who have had breast surgery or radiotherapy, both of which lead to scarring, making conventional mammography and Ultrasound difficult to interpret, and in young women with dense breasts.

### **Contraindications**

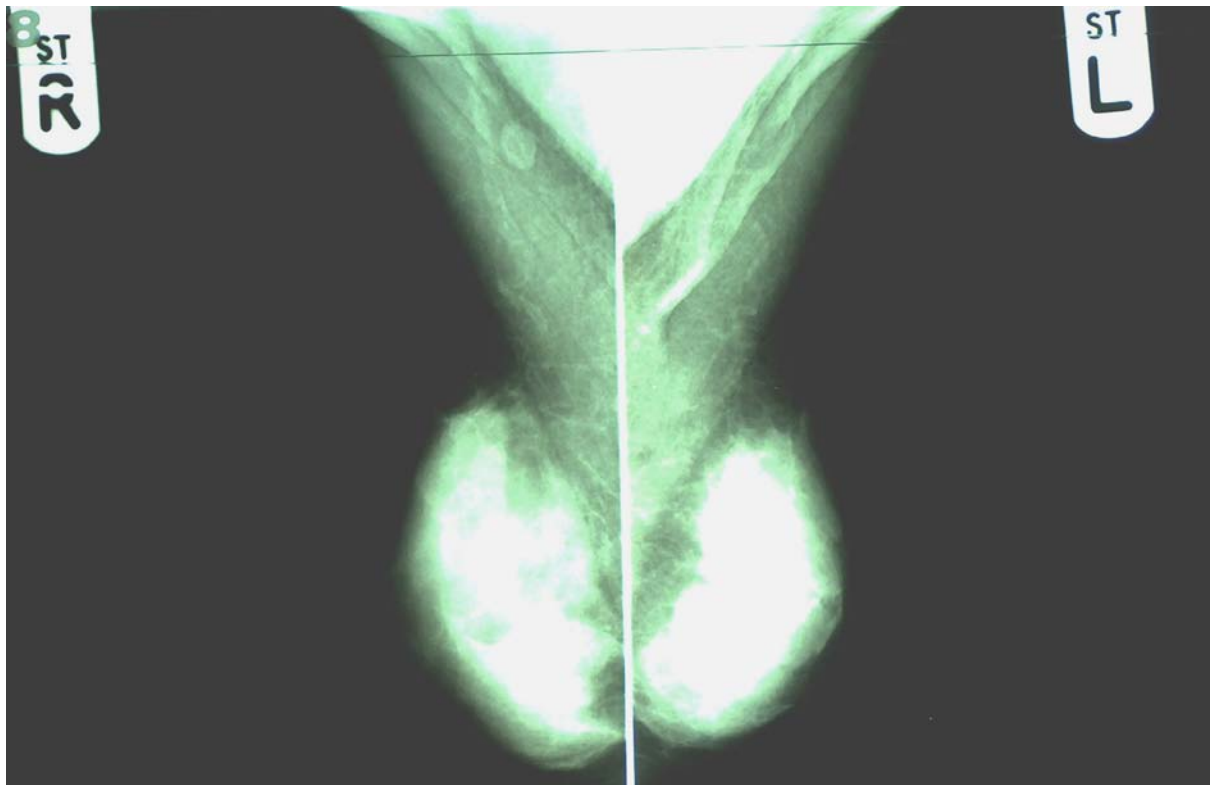
Pregnancy, but this may be relative and depends on the tumour type, and must be discussed with the surgeon.

### **Diagnostic algorithms**

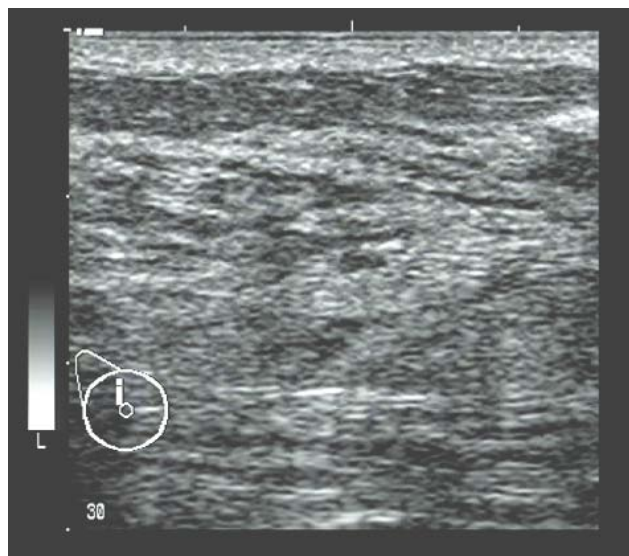
Conventional mammography and ultrasound with biopsy are the first-line investigations.



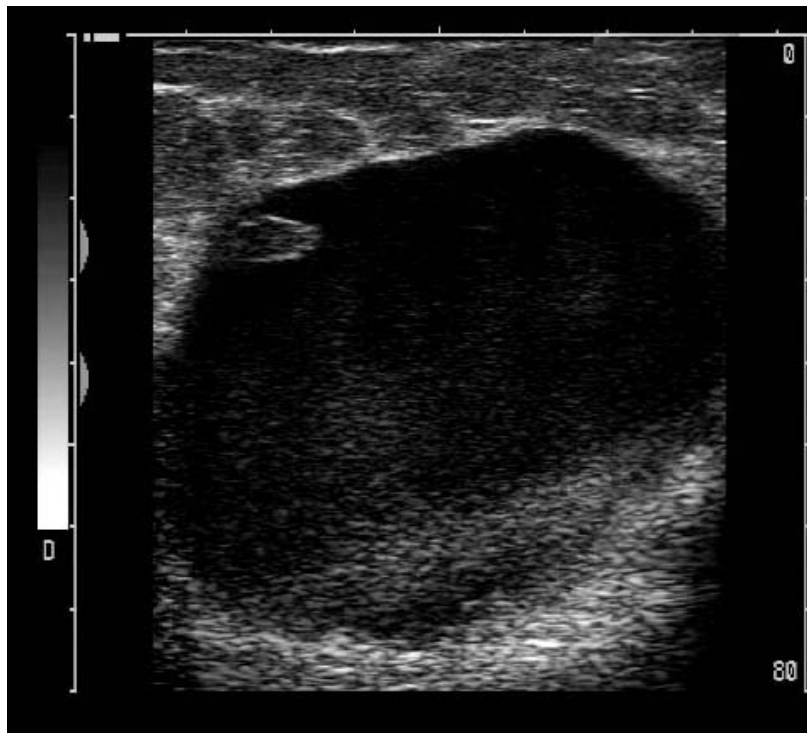
Malignancy shows up as dense speculate areas with micro-calcification. Mammography is most successful in older women where there has been some atrophy of breast tissue and there is a reasonable amount of fat. Mammography is less successful in younger dense breasts and small breasts.



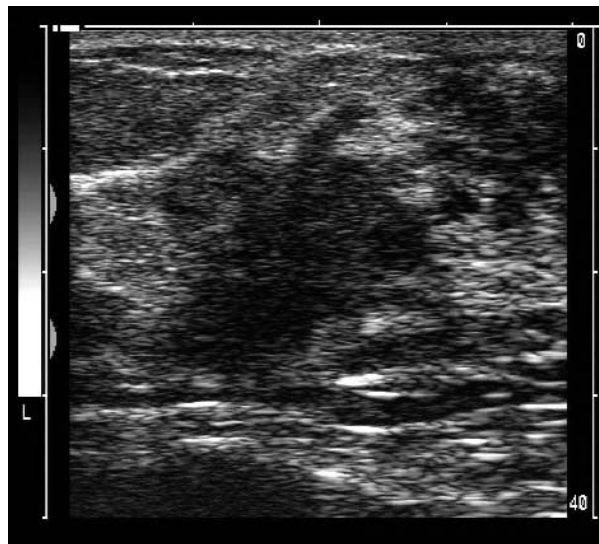
In such cases ultrasound may well be extremely useful. The image below shows the typical benign intraglandular architecture.



The image below shows a typical benign cyst with debris.



The image below shows intraductal invasion from a breast cancer.

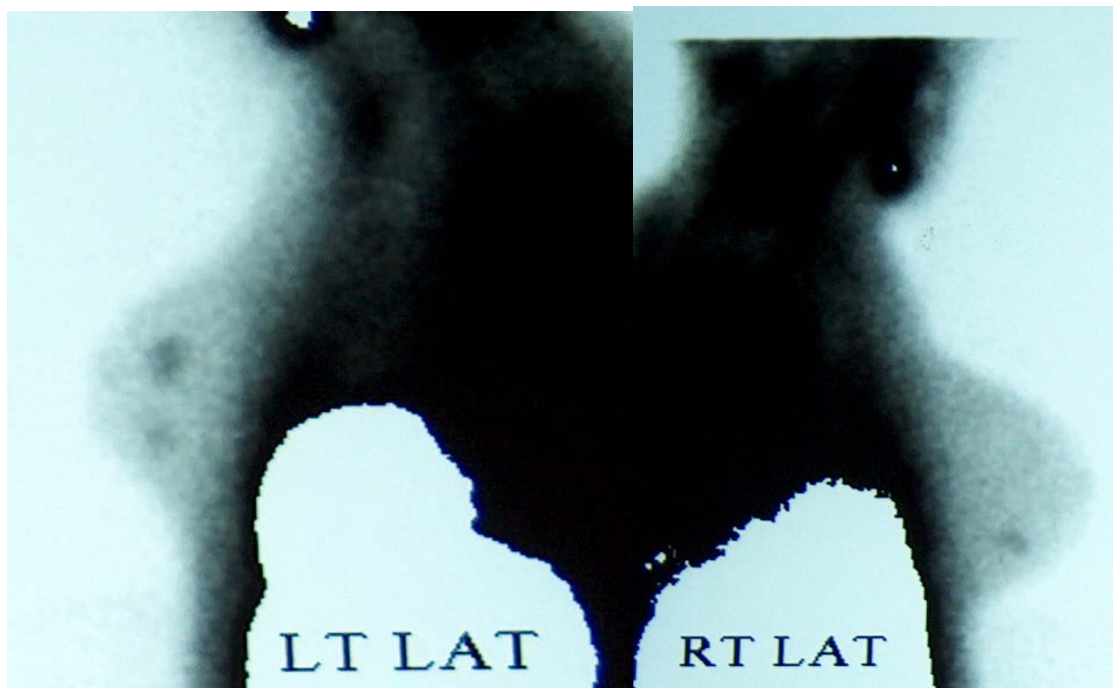


Ultrasound is very operator-dependent, but both it and mammography have the advantage that if a lesion is seen, biopsy can be performed immediately.

Scintimammography and MRI are reserved for difficult cases and in breasts where there has been previous surgery or radiotherapy.

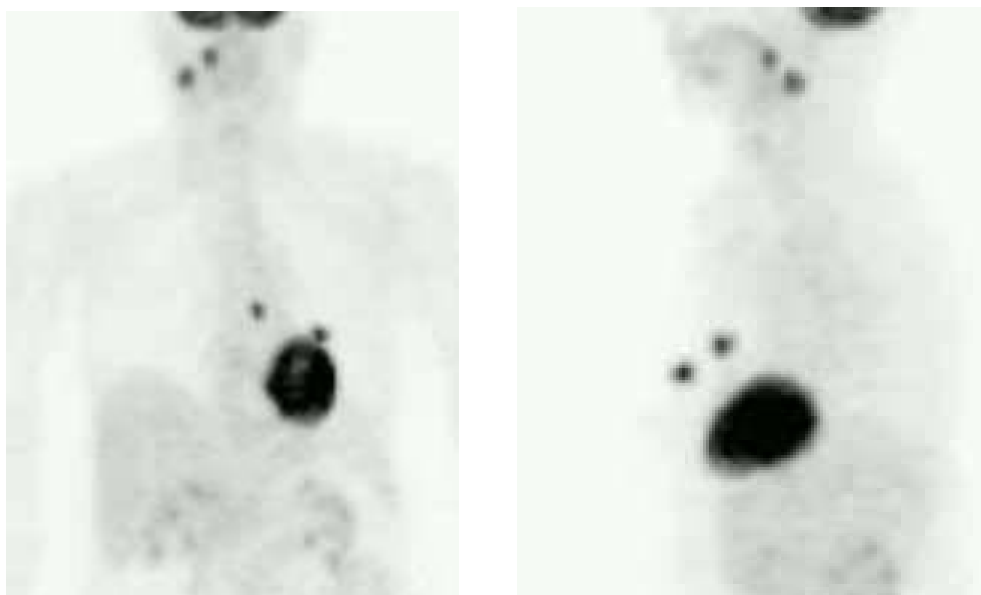


Scintimammographic images are shown below.



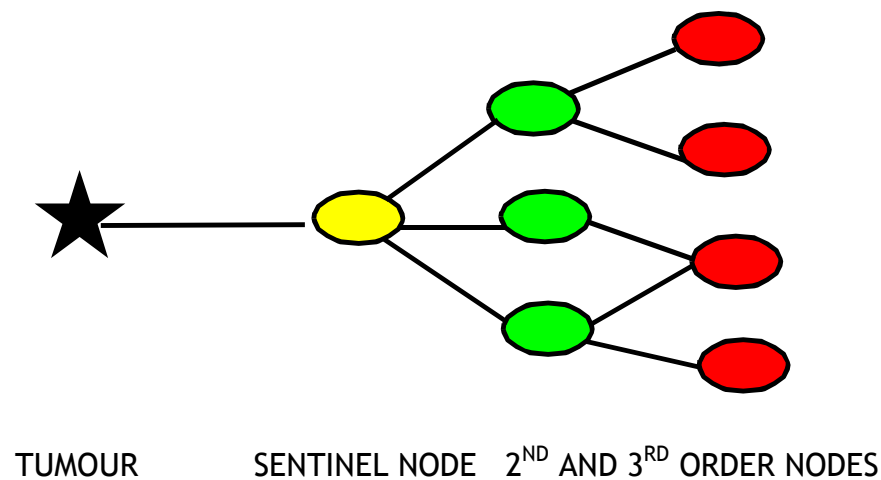
These images show uptake in two tumours in the left breast and one in the right.

There is growing use of PET using  $^{18}\text{F}$ -FDG in breast tumour imaging. The standard dose administered is 350 MBq. The two images below (anterior and left lateral) show  $^{18}\text{F}$ -FDG uptake in the left breast and internal mammary node in a case of unsuspected breast cancer (the patient presented with a lump in the right side of the neck due to a tumour of the tongue - uptake in neck).

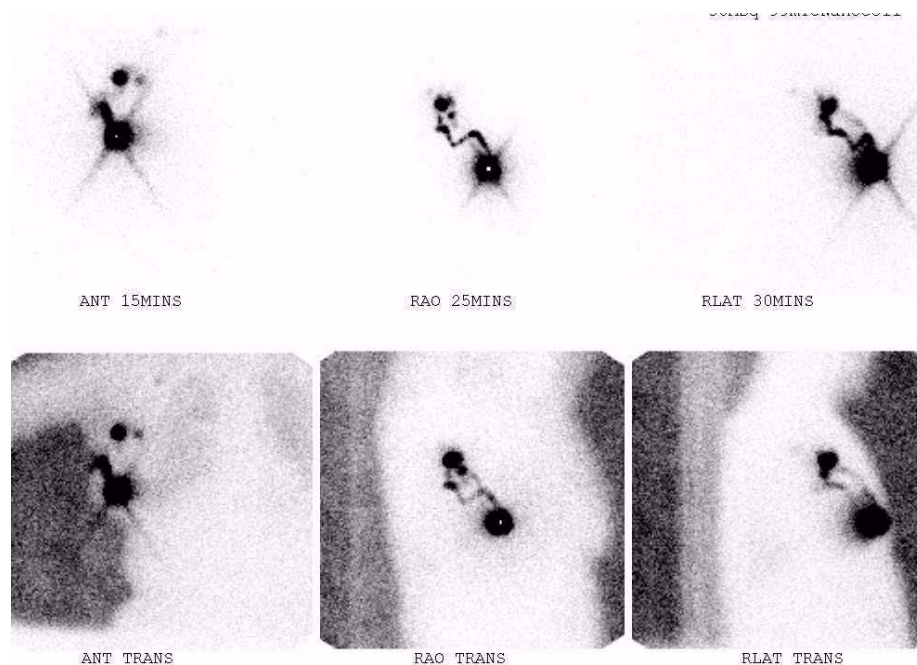




The principle of sentinel node imaging may be summarised in this diagram.

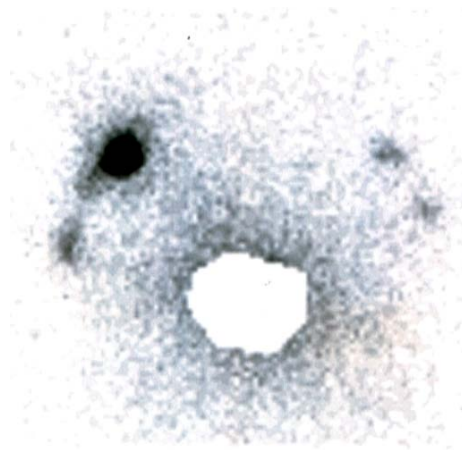


The images, below, show this in practice. The large black spot is the injection site, and the lymphatic tracks and sentinel node are clearly shown. The procedure may be done on the morning of surgery, or the afternoon before using a higher dose of administered activity. The sentinel node is marked on the skin for the surgeon. At surgery, or just before, a blue dye is injected. This is taken up by the lymphatics and also aids in nodal detection.



Breast cancer may be followed up in a variety of ways, and the commonest is using bone scans and liver Ultrasound, since the disease most commonly metastasises to bone and liver.

Sentinel node studies are also carried out to trace the spread of melanoma, and in carcinomas of the tongue, vulva, penis and anus.



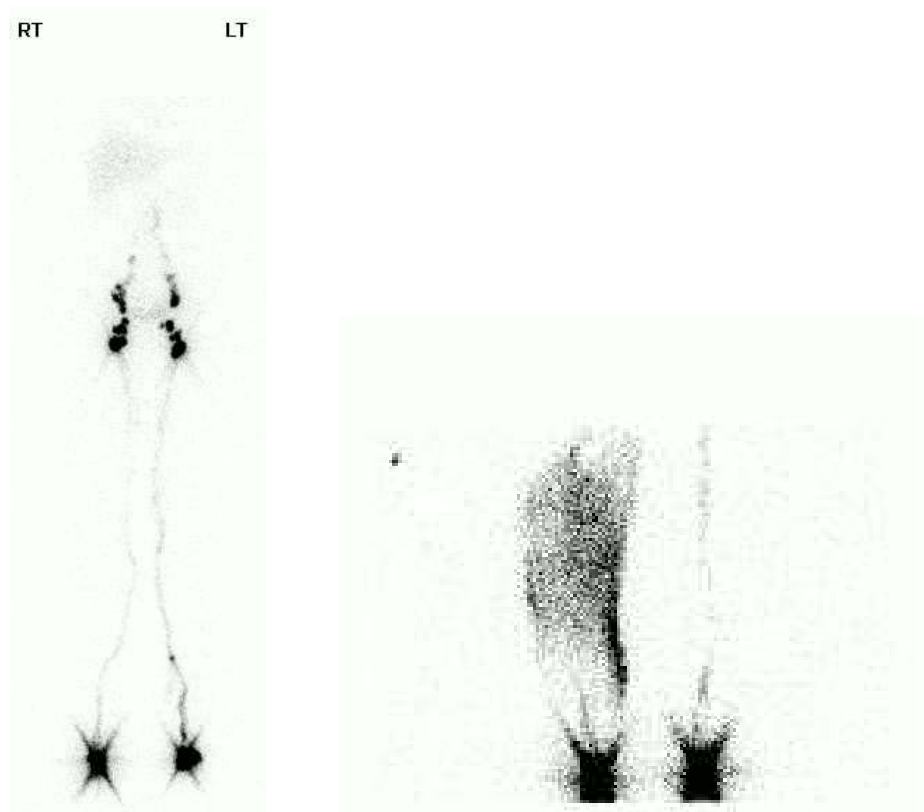
Courtesy of Dr Tom Nunan, Dept of Nuclear Medicine, St Thomas's Hospital, London

The scan above shows a sentinel node study from a patient with a melanoma in the middle of the back. The region of the injection is masked so that the much lower activity in the sentinel nodes is easily seen. There are four sentinel nodes seen, two in each axilla.

### Other lymphatic imaging

Lower limb lymphatics can also be studied using  $^{99m}\text{Tc}$ -colloid injected intradermally between the first and second toes. Clearance will show normal or abnormal lymphatics, and the study is carried out in cases of swollen legs not due to a vascular cause.

The study on the left, below, is normal but that on the right shows leakage into the soft tissues in the right leg due to abnormal lymphatic channels.



## CARDIAC

### Principles

There are two main ways of imaging the heart using Nuclear Medicine, either imaging the myocardial muscle or the blood within the heart. All these studies are done as dynamic studies, and they may also be ECG gated. In gated studies, the patient has ECG electrodes applied and a standard 3-limb ECG obtained. This is inputted to the computer, which creates frames and accepts data during certain times in the ECG cycle, and also rejects irregular beats. The computer uses this data to create a moving image of the heart, as well as images of the myocardium.

A resuscitation trolley and staff skilled in life support and resuscitation must be available when cardiac imaging is performed.

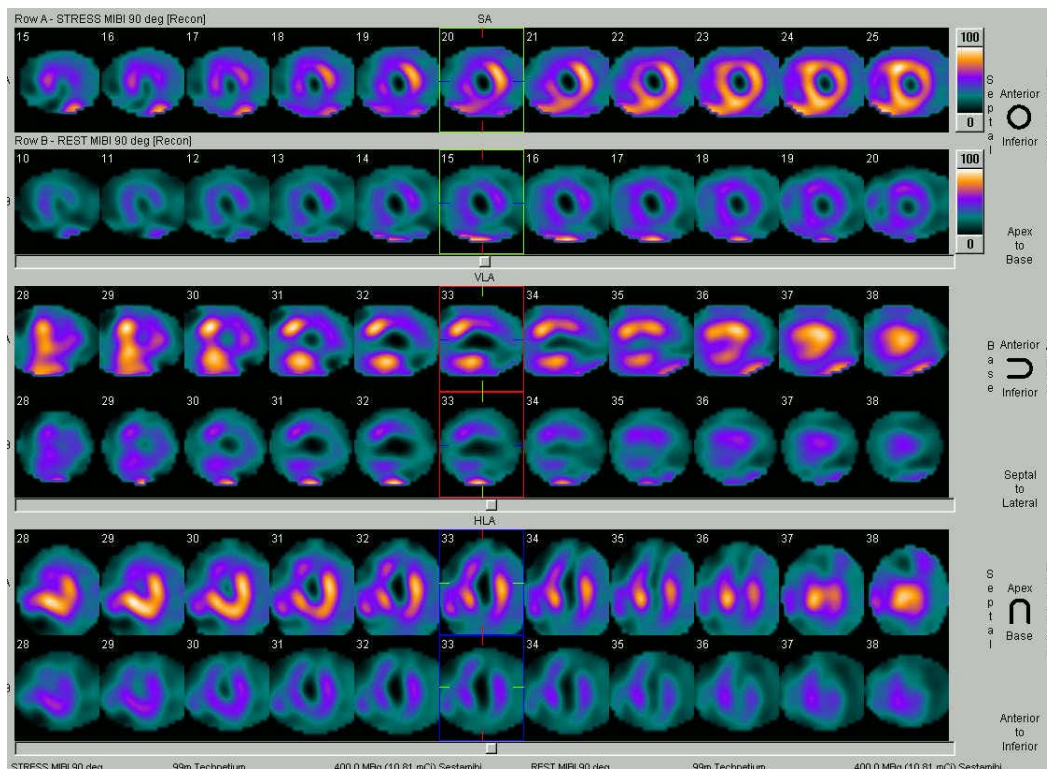
### How to perform the nuclear medicine tests

Imaging the heart muscle - known as MPI (myocardial perfusion imaging).

The idea behind this is to see whether there is myocardial ischaemia which shows as perfusion defects on stressing the heart, and if so, whether they persist at rest - so called reversible or irreversible defects. The heart used to be stressed mechanically on a treadmill, but this was not reproducible, so chemical stressing is now used with adenosine, dobutamine or dipyridamole. These allow a precise level of stress to be applied. At maximum stress the radiopharmaceutical labelled with 800 MBq  $^{99m}\text{Tc}$  is injected. The pharmaceutical is either sestaMibi or tetrafosmin.

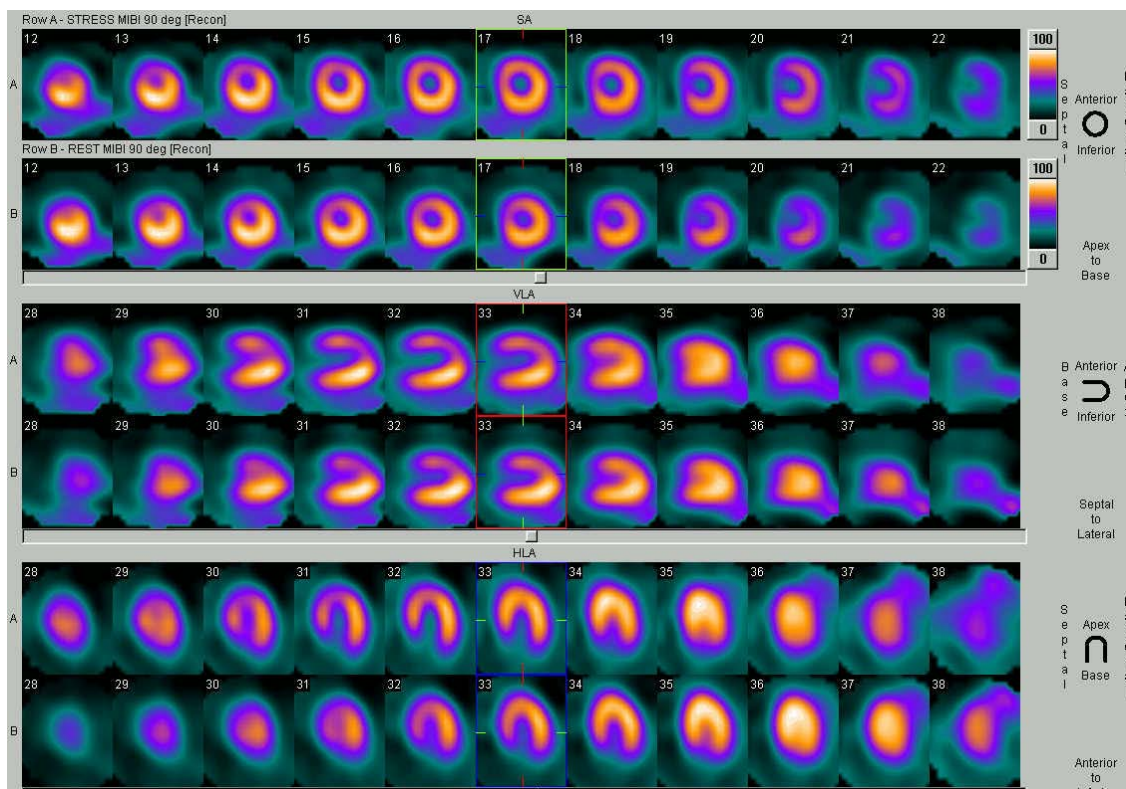
The stress test is performed first, and if normal there is no need for a rest test, which would otherwise be done a day or so later. Some centres do a one-day protocol, imaging stress first and waiting some 5-6 hours before performing the rest study. Two-day protocols give better results.

Myocardial perfusion imaging was originally done using  $^{201}\text{Tl}$ , a  $\text{K}^+$  analogue, but thallium is a poor isotope to use as the energy of the gamma rays is low, at 78KeV. However, thallium is still used in certain countries.

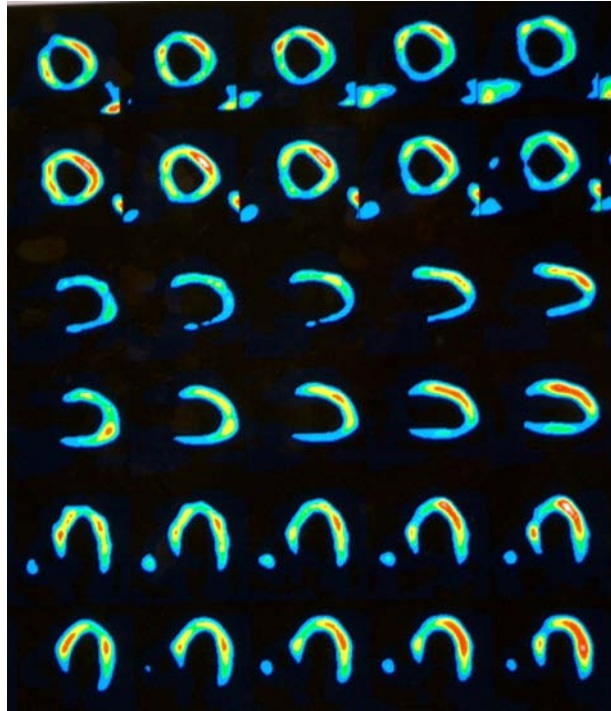


Stress in the upper row, rest in the lower.

The above image shows a significant defect at the apex, both on rest and stress, indicating irreversible ischaemia.



The above image shows a normal study both on stress and rest.



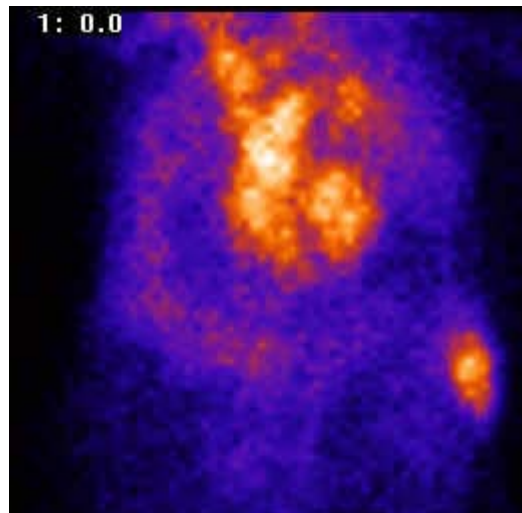
This study shows very significant thinning of the myocardium, and a greatly enlarged left ventricular volume. The cause is alcoholic cardiomyopathy.

The gated study also allows calculation of the LV ejection fraction - normal is above 55%.

#### Imaging the blood.

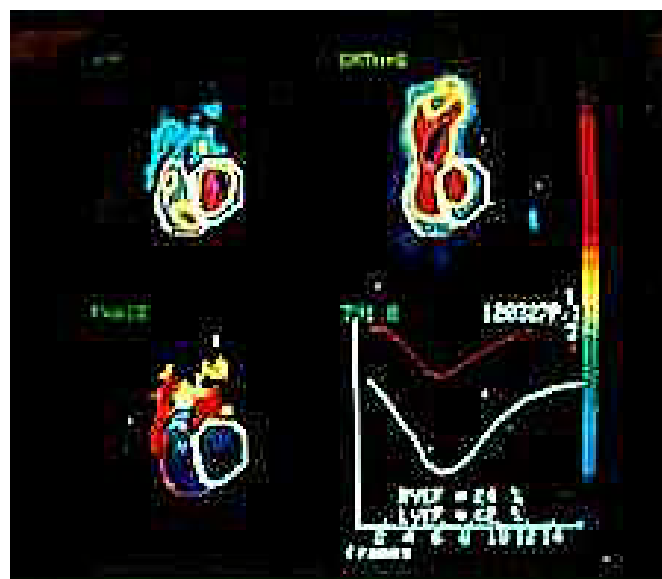
The logic behind this is that as the blood volume changes during systole and diastole, it is representing the movement of the myocardium. The RBCs are labelled *in vivo* by injecting stannous pyrophosphate which adheres to the red cell membrane, followed by 800 MBq  $^{99m}\text{Tc}$  as pertechnetate, which then sticks to the red cells. The study is gated, and is known as a MUGA (Multiple Gated Acquisition) study. Computer analysis allows the LV ejection fraction (LVEF) to be easily calculated.



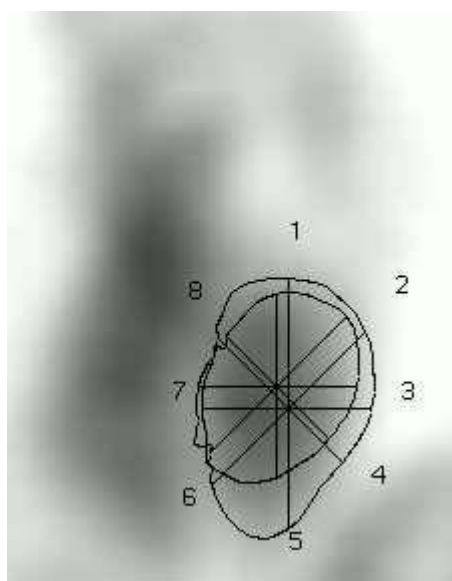
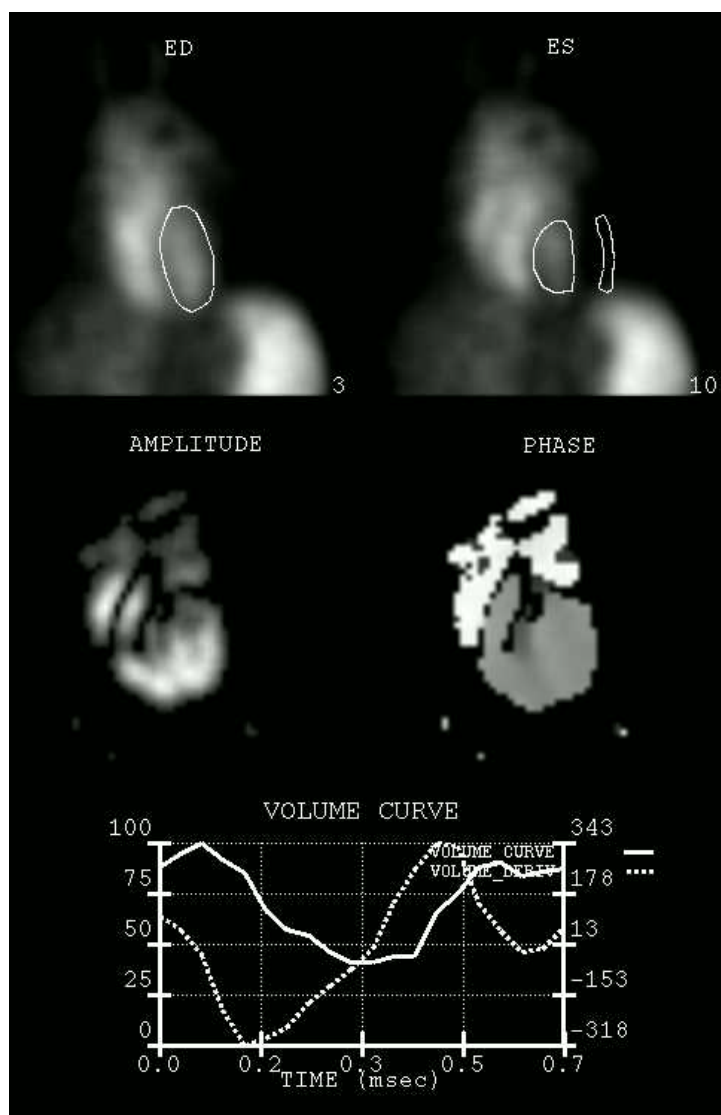


This image shows the labelled blood in the LV, the RV, the aorta and bottom right, the spleen. ROIs are drawn and the LVEF calculated.

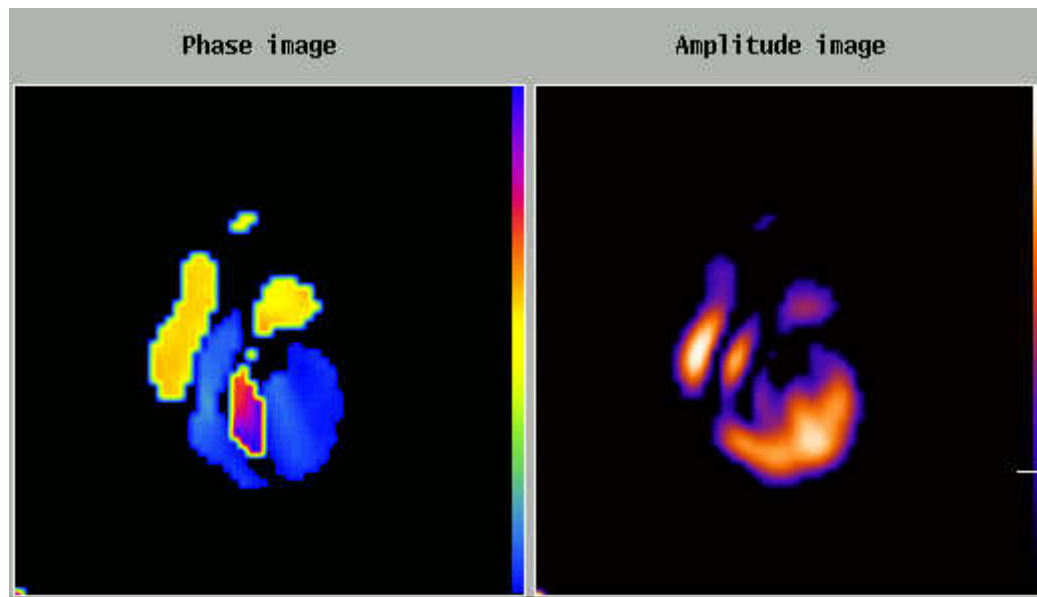
These next images show the ROIs drawn at end-systole ES and end-diastole ED, together with the background. The volume curve allows the EF to be calculated.



If required, the RV ejection fraction can also be calculated. A normal RV ejection fraction is around 35%.







Phase and amplitude images also show whether there is any movement irregularity in the LV.

### Indications

#### a) MPI

Anginal symptoms. Allows investigation without need for coronary angiography.

Abnormal ECG

Chest pain of indeterminate cause

Pre-operative in high-risk vascular patients, especially diabetics

Risk analysis of future cardiac events

#### b) MUGA

Simple easily repeatable estimate of LVEF in patients receiving cardiotoxic chemotherapy such as Herceptin. In such cases it is important that the same method is used each time.

Intracardiac shunts can also be assessed using MUGA scans, especially L to R shunts, but in general, shunts are best evaluated with cardiac echo studies.

### Contraindications

Pregnancy

### Diagnostic algorithms

MPI is a quick and relatively cheap method of assessing the state of myocardial perfusion, and so should be used as the first line examination. Abnormal results

suggesting reversible ischaemia then need coronary angiography and perhaps stenting.

However, in cases of hibernating myocardium, the appearances on the MPI are those of irreversible ischaemia, but the myocardium remains vascularised. To show this, the myocardium is perfused with a PET isotope,  $^{82}\text{Rb}$ . Other PET isotopes used in myocardial imaging are  $^{18}\text{F}$ -FDG and  $^{13}\text{NH}_3$ .

Second-line investigations of the coronary arteries are multislice CT and cardiac MRI.

LVEF estimation can be easily performed using MUGA studies, but can also be investigated using cardiac echo studies. These have the advantage that stress echo studies can be performed as well, and valve dynamics studied.

## ENDOCRINE IMAGING

The endocrine glands comprise the pituitary, the thyroid, parathyroids, pancreas, adrenals, ovaries, testes and neuro-endocrine tumours.

### Pituitary.

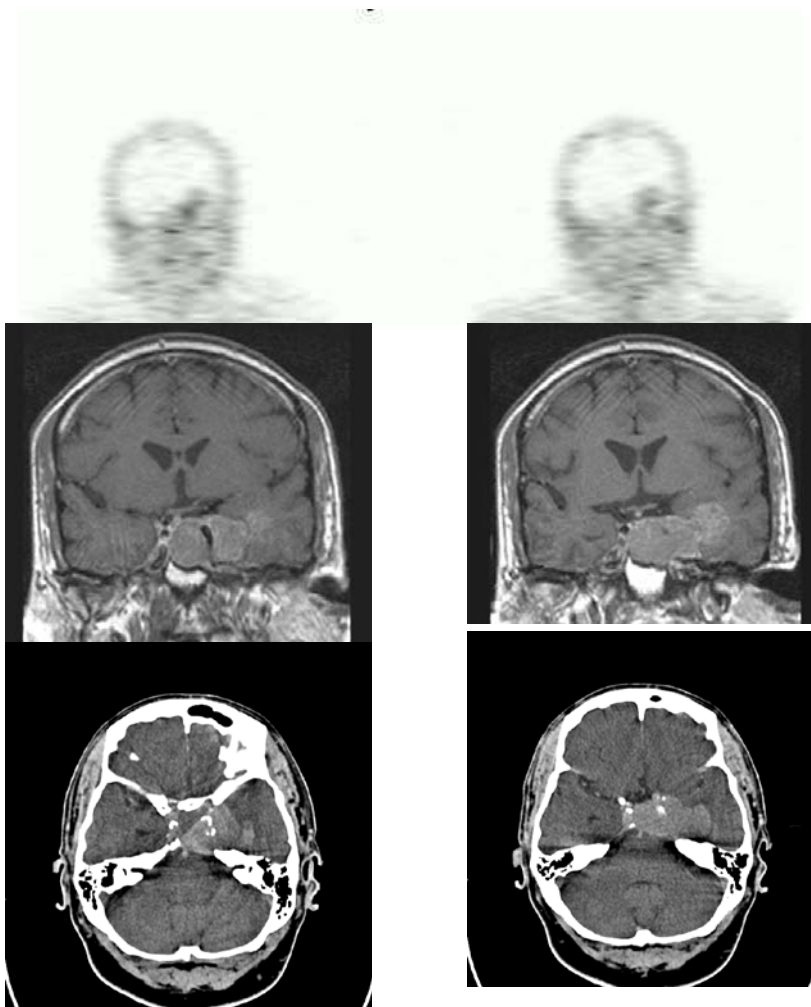
#### Principles

The pituitary consists of anterior and posterior, and their function is evaluated biochemically. The pituitary gland is imaged using MRI, although it is possible to image it using  $^{111}\text{In}$ -octreotide (administered dose 200MBq). This is hardly ever done, as the information from the MRI and biochemistry is all that is required.

#### Indications

Prolactinoma

Acromegaly



These images show a large pituitary tumour imaged with octreotide (top), MRI (middle) and CT (lower).

## Thyroid.

### Principles

The thyroid is investigated in cases of goitre, or suspicion of hyper- or hypo-thyroidism.

### How to perform the nuclear medicine tests

The commonest isotope used is  $^{99m}\text{Tc}$  as pertechnetate, administered dose 80 MBq.  $^{123}\text{I}$  as iodide can also be used, administered dose 20 MBq, but is more expensive. The isotope is injected intravenously, and the patient imaged after 15-20 minutes, using a pinhole collimator. If  $^{99m}\text{Tc}$  is used, there is no special patient preparation and no need to stop anti-thyroid medication such as carbimazole/methimazole or thyroxine. However, these need to be stopped if  $^{123}\text{I}$  is used.

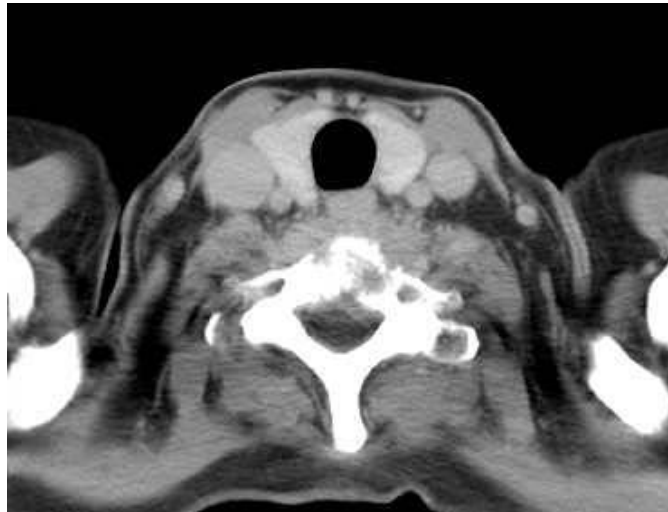
### Indications

Goitre

Altered thyroid function

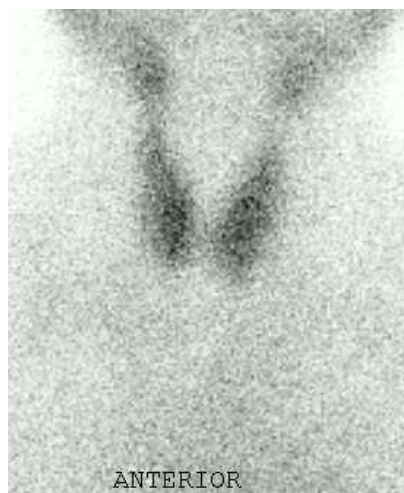Ectopic thyroid

The thyroid gland lies anteriorly in the neck below the thyroid cartilage. When thyroid disease is suspected, the first examination is biochemical, looking at the levels of  $\text{fT}_4$ ,  $\text{fT}_3$  and TSH. The thyroid may be imaged using Ultrasound, CT or Nuclear Medicine tests. The commonest used are Ultrasound and Nuclear Medicine; which one is a matter of preference. Ultrasound will show the size and morphology of the gland, and will identify solid or cystic nodules, and will allow immediate biopsy of solid nodules. On the other hand, a Nuclear Medicine examination shows the function of the gland and differentiates 'hot' from 'cold' nodules. In difficult cases it is probably best to perform both. If the thyroid is seen on CT, and i.v. iodine-containing contrast has been given, the iodine will stay in the thyroid for up to a year, making therapy with  $^{131}\text{I}$  impossible.



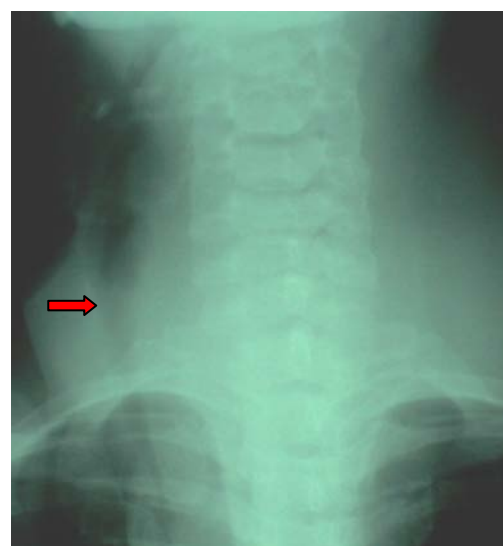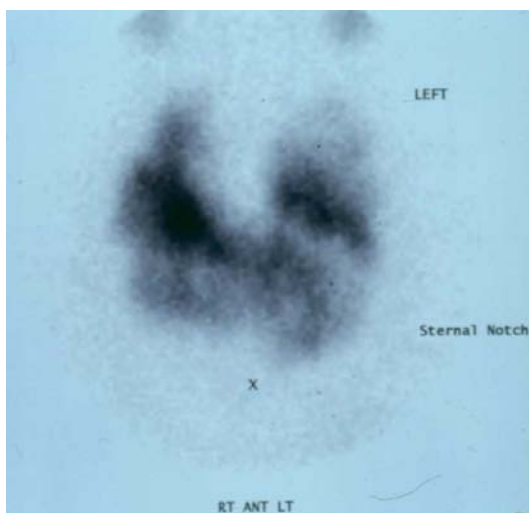
This CT image shows the thyroid either side of the trachea. Lateral to the thyroid are the carotid artery and jugular vein.

Note that there is an association between thyroid disease, untreated coeliac disease and diabetes.



The image above is a normal thyroid, and as well as the gland, the salivary glands can also be seen.

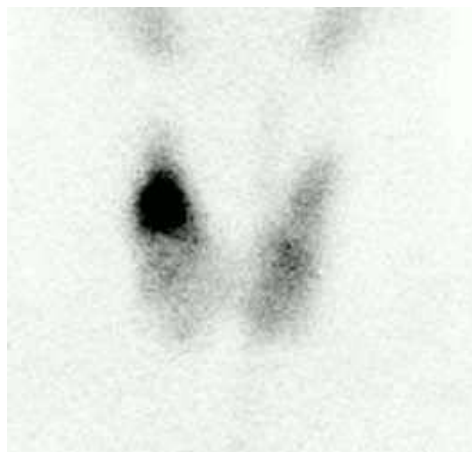A non-toxic goitre is easily palpated and is almost always a large multi-nodular goitre.



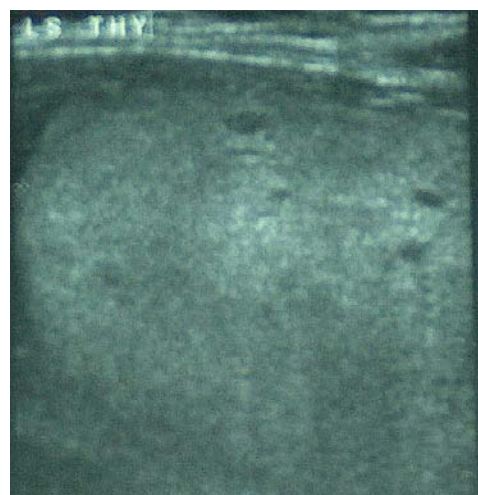

These images show a large multinodular goitre (left) and the radiograph of the patient. Note that the trachea is markedly displaced to the right (arrow), and this displacement may be very significant in that there may be marked narrowing of the trachea (red arrow), and the patient presents as an emergency with stridor. Not all cases are so extreme, and once a multinodular goitre has been diagnosed, no further diagnostic action is required.

Thyroids may also have solitary nodules, and these may be 'hot' i.e. toxic, or 'cold'.

'Hot' nodules need no further investigation since there is a very low incidence of malignancy. 'Cold' nodules, however, need to be investigated further using Ultrasound, and if solid, a fine needle aspiration biopsy needs to be performed since the risk of carcinoma is about 5%. 'Cold' nodules are more likely to be malignant in the younger age group.



The above image shows a 'hot' nodule in the upper pole of the right lobe.

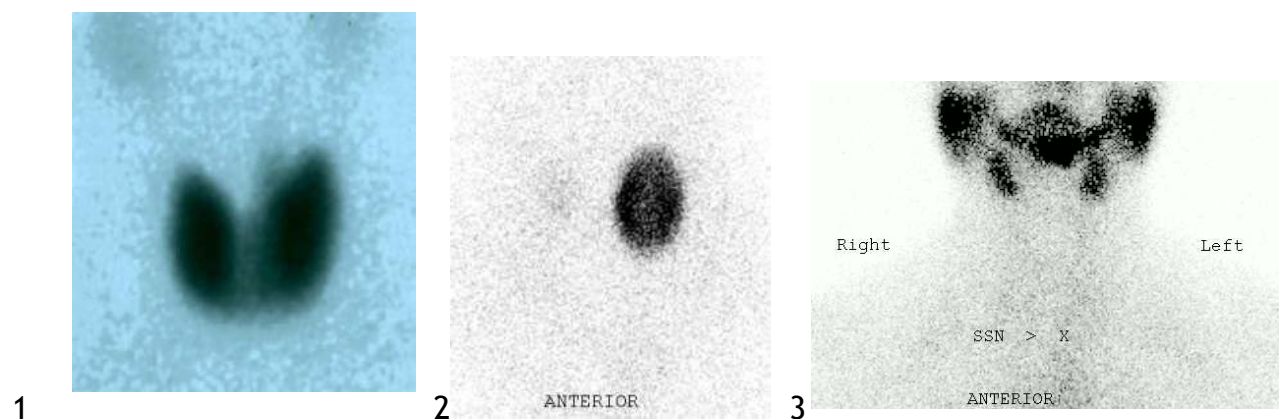


These images above show a 'cold' nodule which is expanding the lower pole of the left lobe of the thyroid, and the Ultrasound, which shows it to be solid.

Over-active or toxic thyroids are characterised biochemically by high  $fT_4$ , high  $fT_3$  and suppressed TSH. Prior to therapy they should be imaged, and there are three main types of toxic gland - Grave's disease, toxic nodular disease in which the nodule may be seen within a normal gland or may be an autonomous nodule suppressing the rest of the glandular activity, or viral thyroiditis.

Treatment is discussed in the section on Therapy.

### Examples



1 = Grave's disease - note the intense even activity with very little background activity

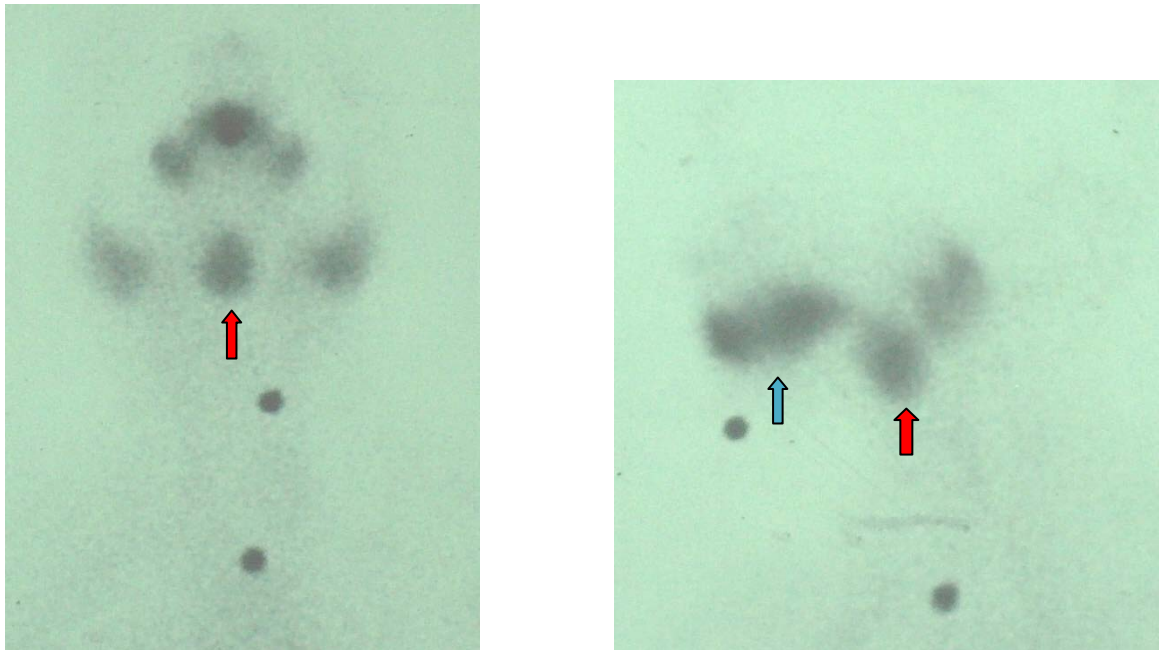
2 = a toxic autonomous nodule - note that the activity in the rest of the gland is suppressed

3 = viral thyroiditis - note that although the patient is toxic, there is no glandular activity. This is because the viral disease disrupts the thyroid cells allowing the hormones to escape into the bloodstream, causing the thyrotoxicosis. The viral thyroiditis is self-limiting and usually requires no treatment apart from  $\beta$  blockers.

Under-active thyroids are characterised by low  $fT_4$  and  $fT_3$  and raised TSH. There is no need to perform any imaging.



The most important ectopic thyroid is lingual thyroid, found at the base of the tongue. There may well not be any other functioning thyroid tissue present.



The anterior view (above, left) shows the thyroid lying between the parotid glands (red arrow). The two black circles are markers - the upper is the thyroid cartilage and the lower is the sternal notch. The lateral view (right) shows the tongue (arrowed, blue) with the thyroid behind it (arrowed, red). The two black circles are markers - the upper is the tip of chin, the lower is the thyroid cartilage.

### **Contraindications**

Pregnancy

### **Diagnostic algorithms**

Biochemical thyroid function tests

Nuclear Medicine imaging

Ultrasound +/- FNA

## Parathyroids.

### Principles

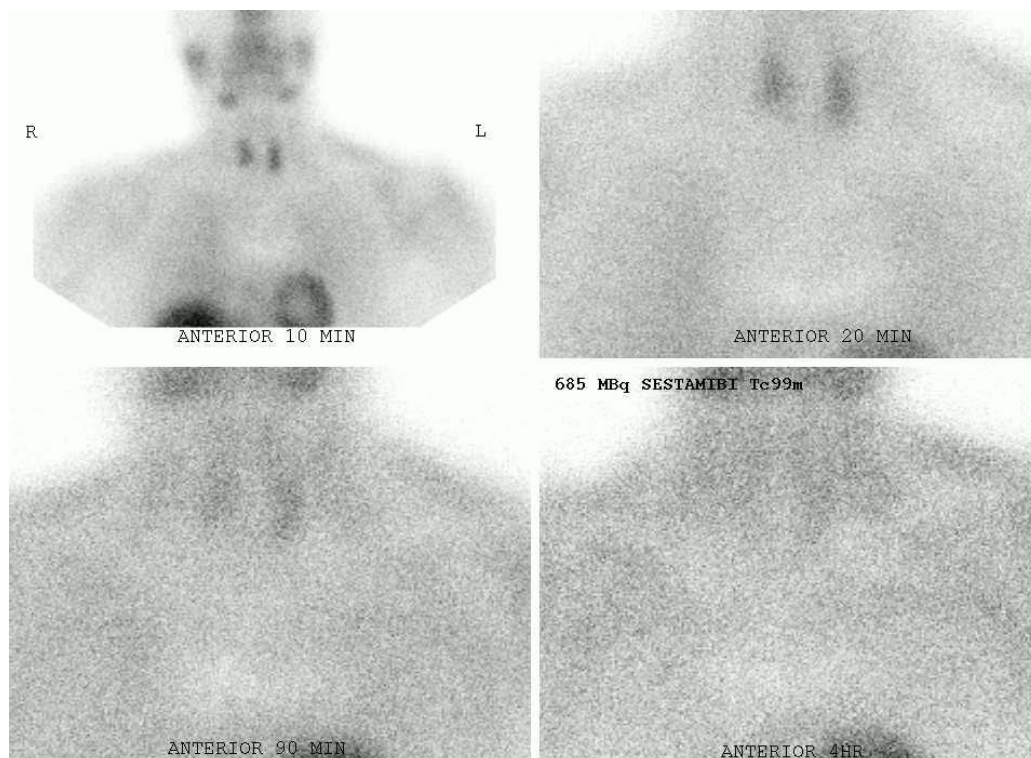
There are normally four parathyroids, lying posterior to the thyroid, although there may be ectopic parathyroids anywhere between the lower border of the thyroid and the aorto-pulmonary window. The parathyroids control calcium metabolism. When pathological, there may be generalised hyperplasia, discrete adenomata or carcinoma.

### How to perform the Nuclear Medicine test

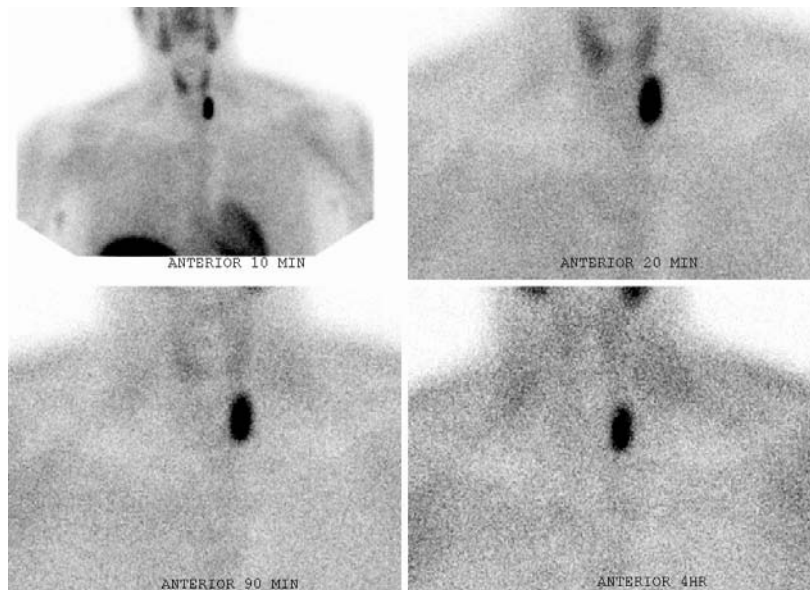
There are several ways of imaging the parathyroids. The commonest is using  $^{99m}\text{Tc}$  sestamibi, administered dose 900 MBq, and the principle here is that the sestamibi is taken up by the thyroid and parathyroids, but is cleared by the thyroid and normal parathyroids quicker than from parathyroid tumours. The test cannot differentiate parathyroid adenoma from carcinoma. Diffuse parathyroid hyperplasia is not visualised. The neck is imaged at 10, 20, 90 and 240 mins after injection. Some surgeons like SPECT of the neck (done at about 60 mins) to give them the depth of the parathyroid adenoma.

The 10 minute image should include the whole thorax in case of ectopic parathyroids.

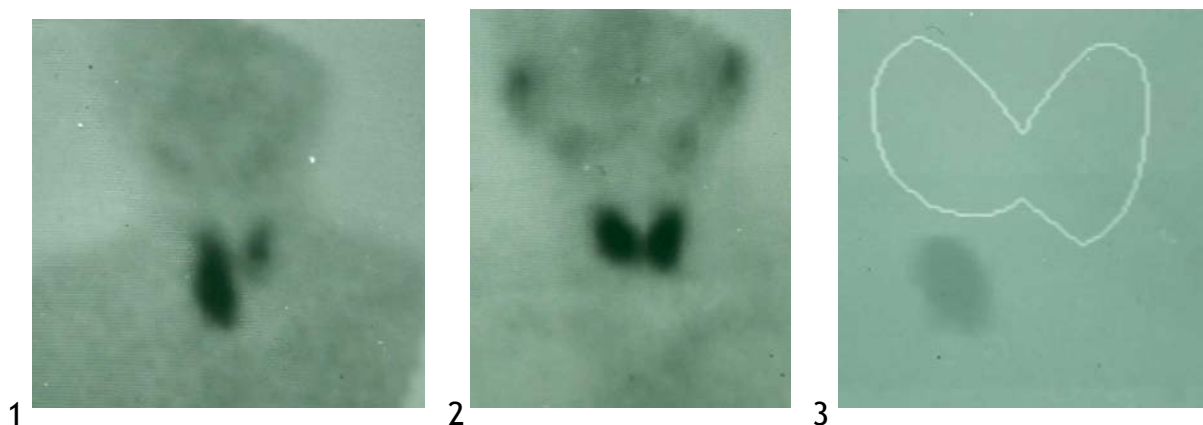
Below is a normal study.



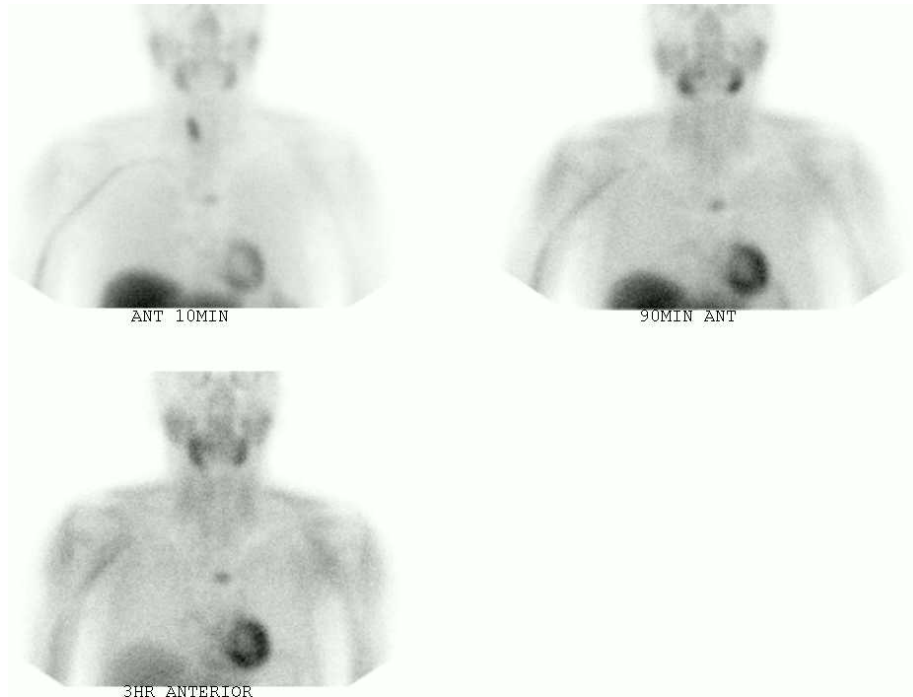
These images show an obvious abnormal left lower parathyroid gland.



The parathyroids can also be imaged using subtraction techniques with  $^{99m}\text{Tc}$ -sestaMibi to visualise both thyroid and parathyroids and  $^{123}\text{I}$  to visualise the thyroid alone (which is more expensive than just using  $^{99m}\text{Tc}$ -sestaMibi and not significantly better) or with  $^{201}\text{Tl}$  to visualise both thyroid and parathyroids and  $^{99m}\text{Tc}$  to visualise the thyroid. This examination is rather difficult in that the head and neck have to be kept totally still. The Tl is injected first as it has a lower energy, followed by the Tc. The results are satisfactory, but more time-consuming than using sestaMibi.



1 = Tl and Tc, 2 = Tc alone, 3 = subtraction showing right lower adenoma



The images above show that the patient has had a left hemi-thyroidectomy, and that there is an ectopic parathyroid in the mid-thorax, which was found to be lying at the aorto-pulmonary window.

### **Indications**

Hypercalcaemia

### **Patient preparation.**

Nil

### **Contraindications**

Pregnancy

### **Diagnostic algorithms**

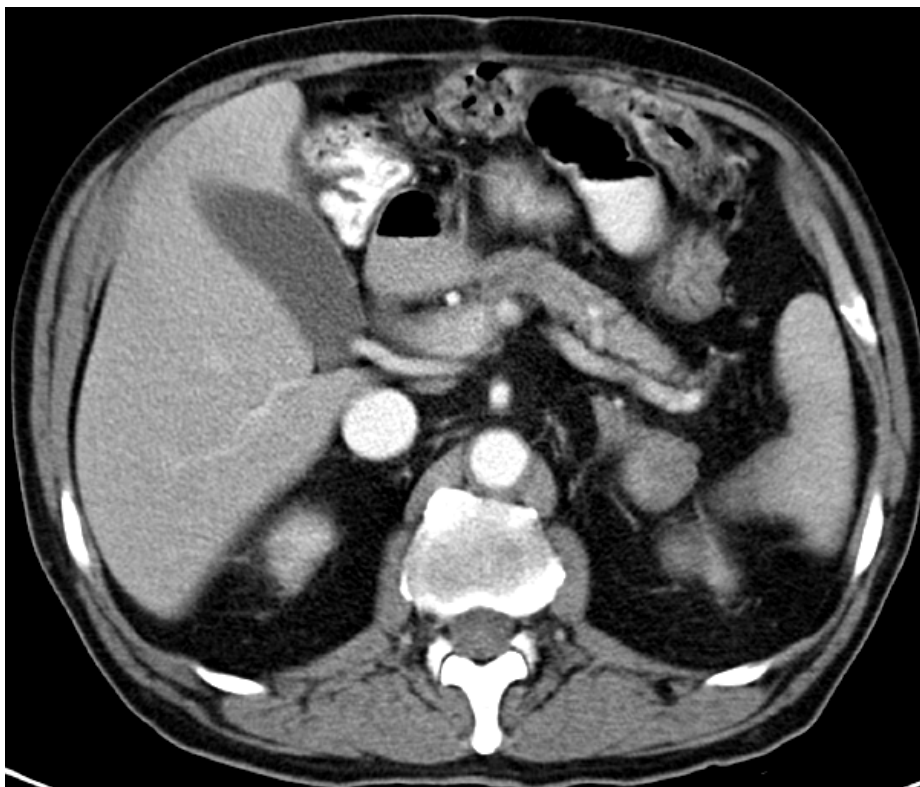
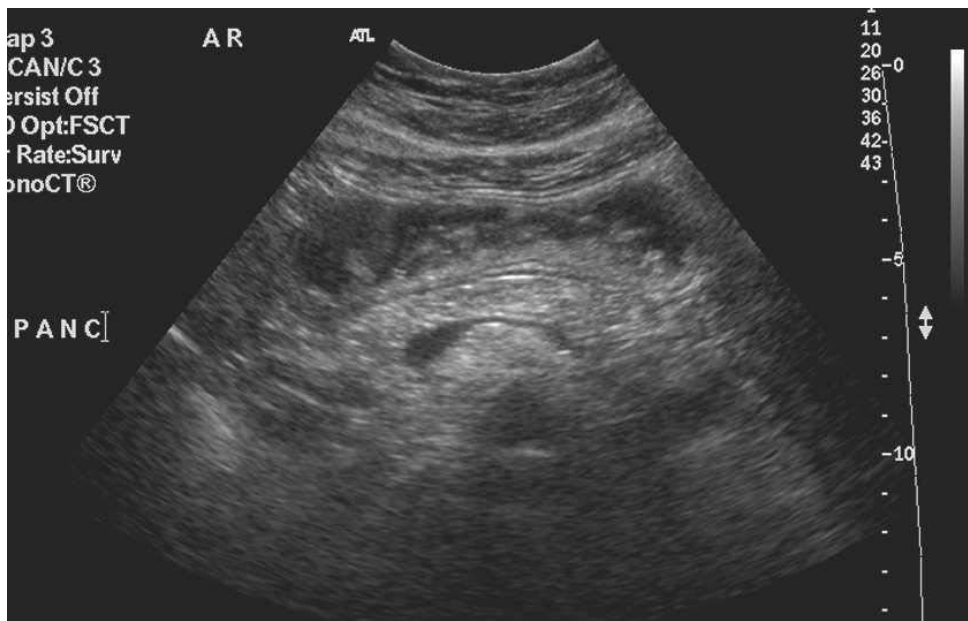
Biochemistry to confirm hypercalcaemia

SestaMibi imaging

Ultrasound

Angiography in cases of intrathoracic adenomata

**Pancreas.** The pancreas is best imaged with Ultrasound, CT or MRI.



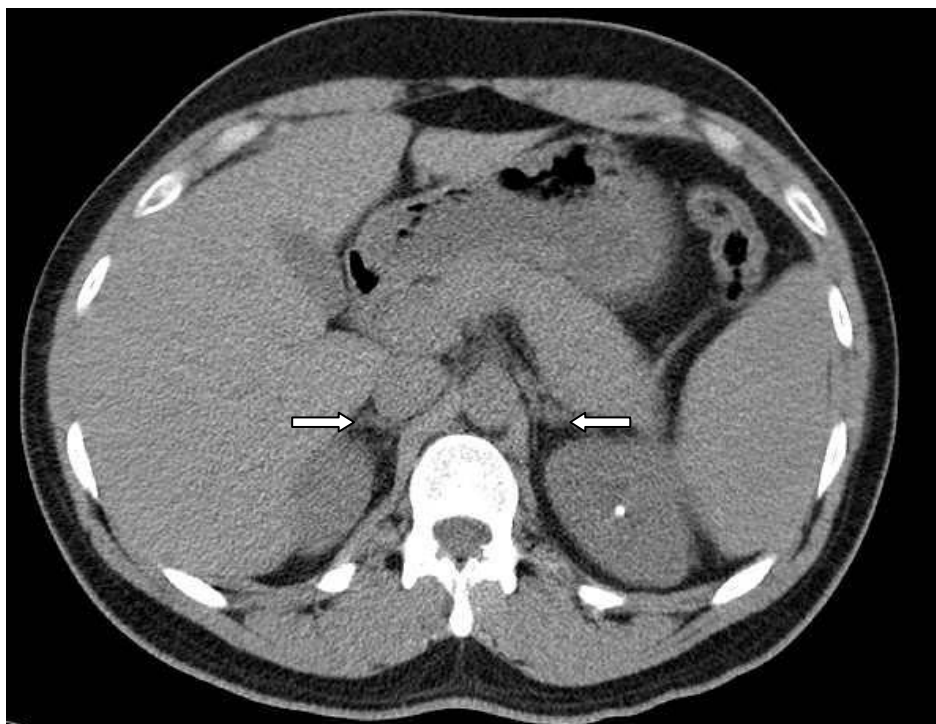
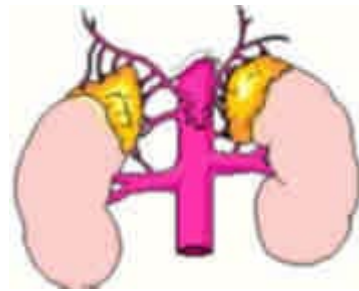There is no place for Nuclear Medicine in pancreatic imaging nowadays, although it used to be imaged with  $^{75}\text{Se}$ .



## Adrenals.

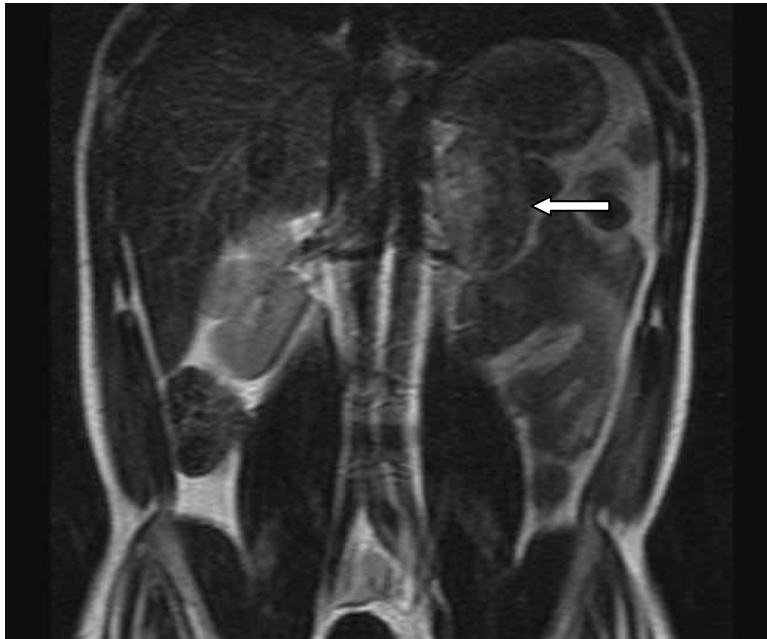### Principles

The adrenals are best imaged on CT and MRI. The anatomy of the adrenal is shown here. The adrenals are roughly triangular in shape and measure about 1 cm in height and 5 cm in length. The gland consists of the outer cortex and inner medulla. The cortex produces the steroid hormones such as cortisone and aldosterone, as well as sex hormones, and the medulla produces epinephrine and norepinephrine.



This CT image shows the normal adrenals (arrowed).

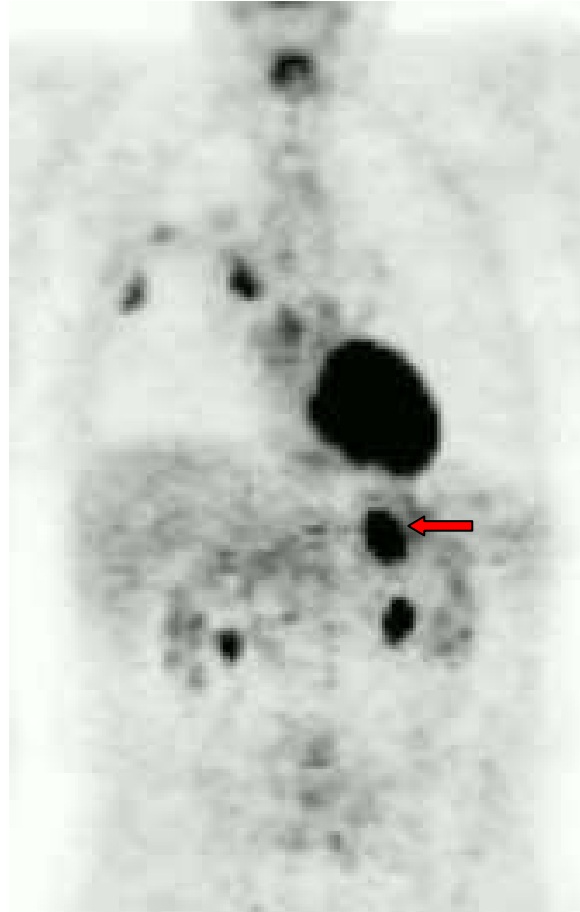
The adrenals are also seen on MRI, best when there is adrenal pathology, as below, showing an enlarged left adrenal with a phaeochromocytoma (arrowed) .



Nuclear Medicine imaging has a part to play when an adrenal mass is discovered, and the question is whether the mass is a secondary malignant tumour, or a primary adrenal tumour.

As the adrenal gland is a common site for metastases, especially from bronchial carcinoma, a PET or PET/CT scan will show whether there is metabolic activity in the adrenal, suggesting a deposit.






This PET scan shows a peripheral bronchial carcinoma in the right lung, with hilar nodes and uptake in an enlarged left adrenal gland (arrow). In endocrine disease, the adrenal cortex, which produces cortisol and aldosterone, can be imaged with  $^{131}\text{I}$ -iodocholesterol, and the medulla which produces catecholamines, with  $^{123}\text{I}$ -MIBG.

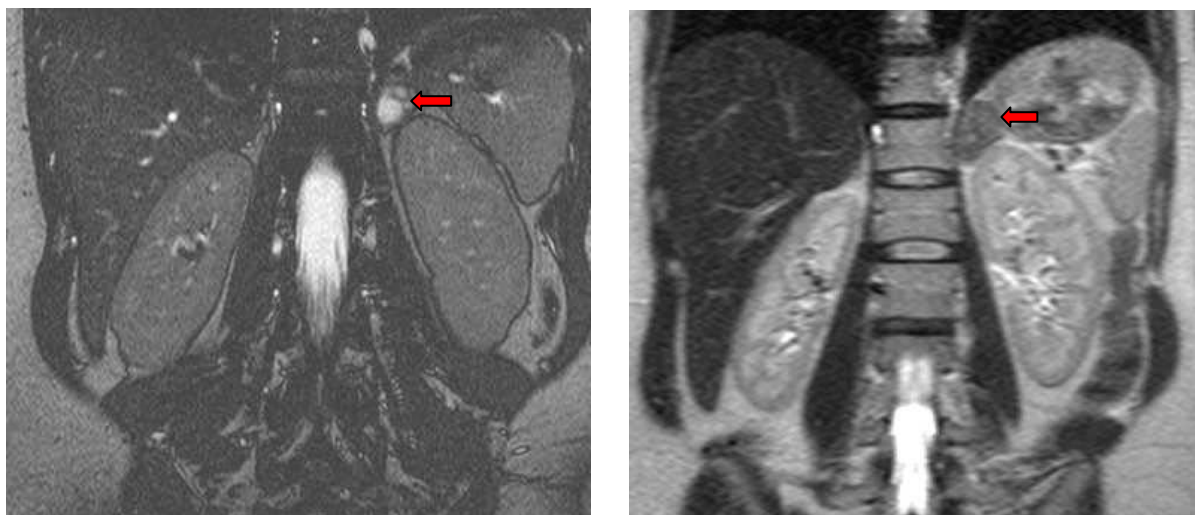
### How to perform the Nuclear Medicine tests

PET or PET/CT. 400 MBq  $^{18}\text{F}$ -FDG is injected with the patient lying quiet and still in a darkened room. Imaging is commenced 1 hour after injection.

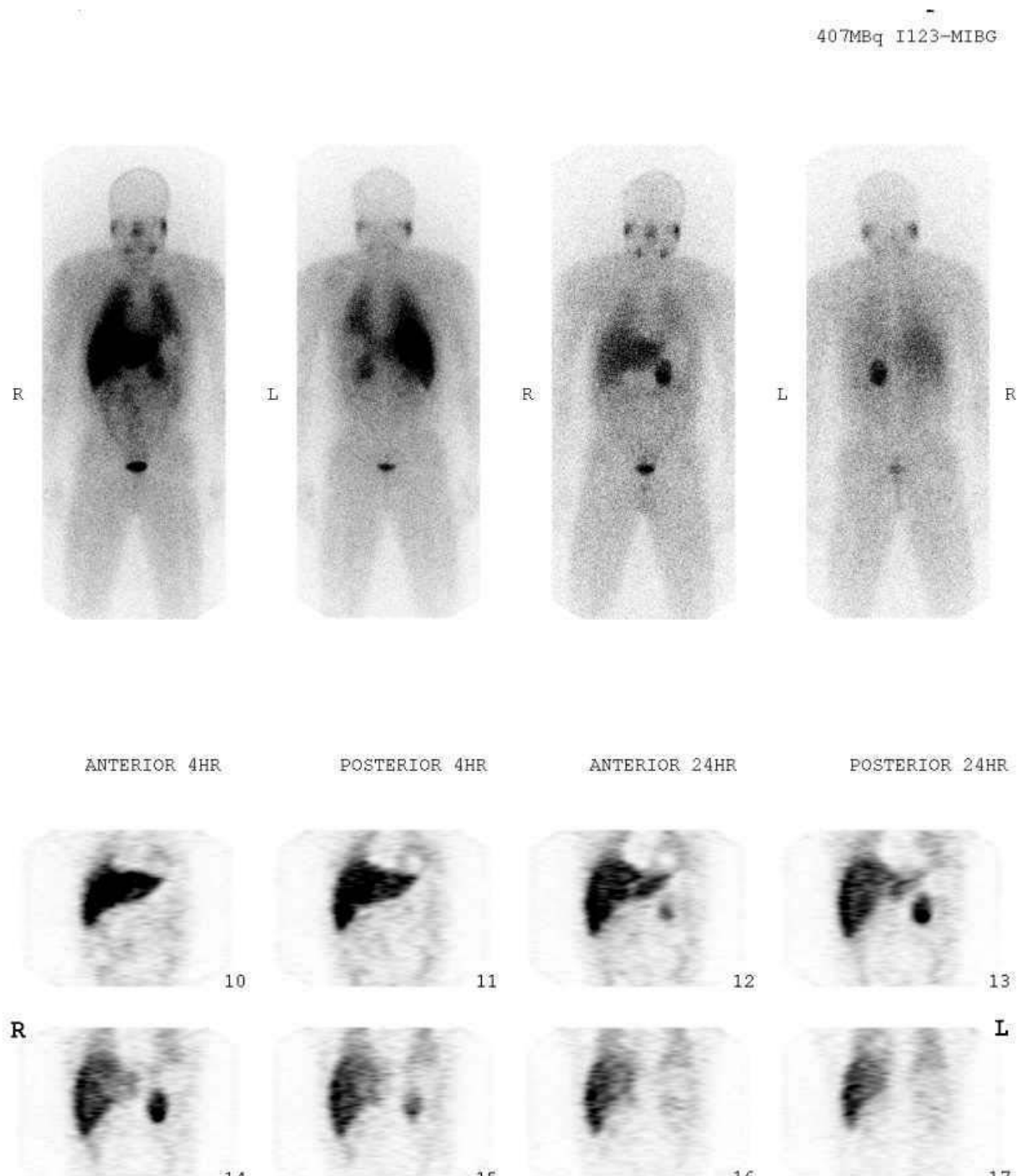
$^{131}\text{I}$ -iodocholesterol. Used to image adrenal cortical tumours, especially Conn's, over 11 days, as these images show. During the study the kidneys are also imaged using DMSA, in order to locate the upper pole and so relate it to any adrenal activity. LK and RK represent to tops of the kidneys. The reason  $^{131}\text{I}$  is used is that it has a long  $t_{1/2}$  of 8 days, which is necessary for a test taking 11 days. These images show a lesion in the left adrenal. Administered dose is 20 MBq.



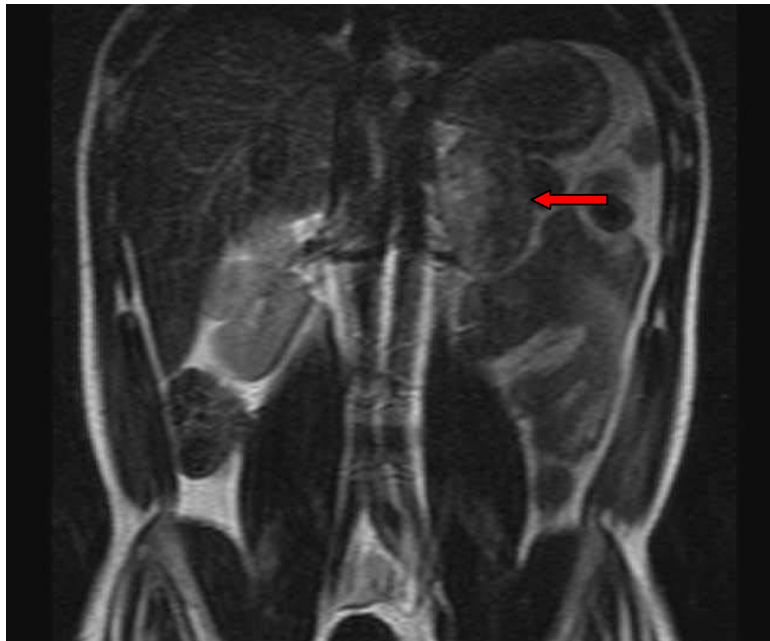The lesion can also be shown well on MRI (arrowed).



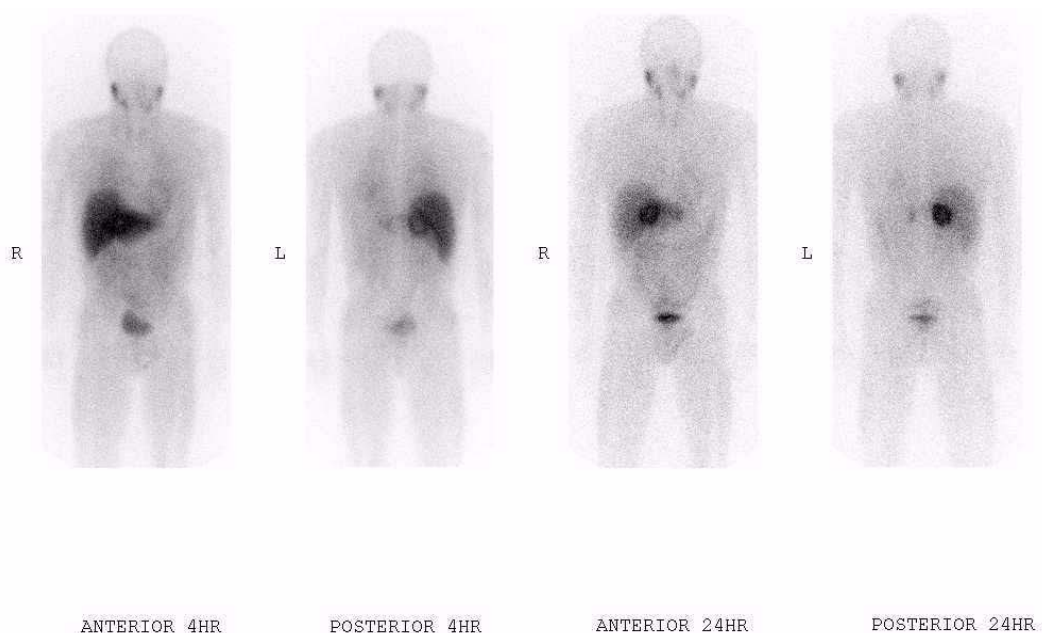
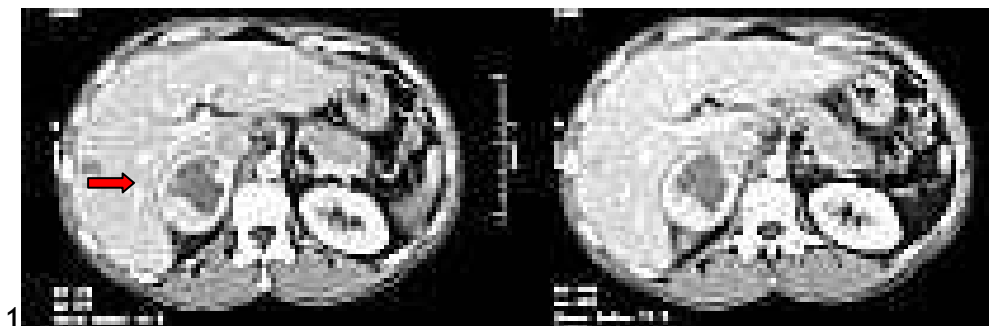
$^{123}\text{I}$ -MIBG. This is used to image tumours of the adrenal medulla, notably pheochromocytoma. 400 MBq is injected, and the images obtained at 4 and 24 hours, both planar and SPECT.



The presence of the tumour may be confirmed on MRI.



Below is another example, shown on CT (1) and  $^{123}\text{I}$  MIBG imaging (2 and 3).



2

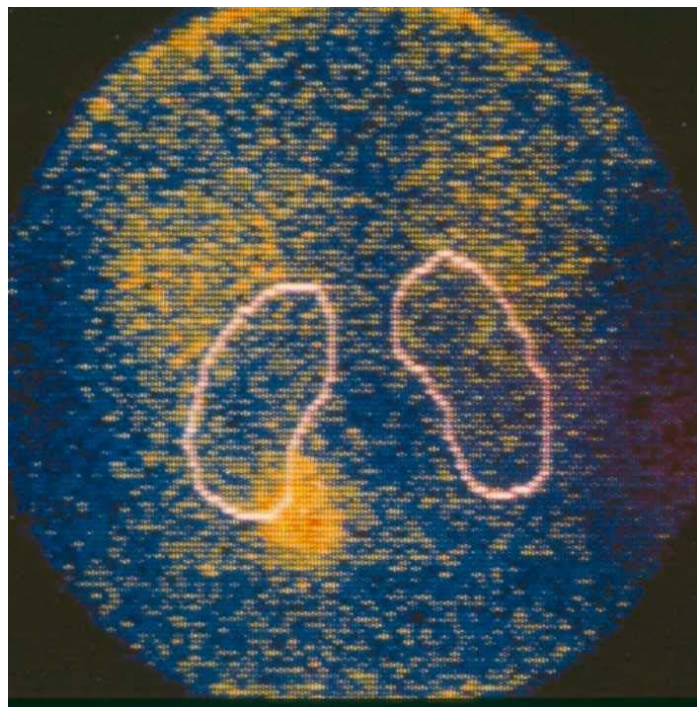
3

R



The whole body image, (2), clearly shows the adrenal lesion, and the tomographic slices below (3) show the necrotic centre, as on the CT (1).

Nuclear medicine imaging is extremely useful in identifying ectopic adrenal tumours, as below, where the phaeochromocytoma lies below the kidney.



### Patient preparation

When using  $^{131}\text{I}$  or  $^{123}\text{I}$ , the thyroid is blocked with potassium iodide.

### Indications

Biochemical abnormalities suggesting an adrenal tumour, or incidental finding of an enlarged adrenal on CT or MRI.



## Diagnostic algorithm

Biochemistry

CT/MRI

PET/CT if tumour suspected

$^{131}\text{I}$ -iodocholesterol if Conn's suspected

$^{123}\text{I}$ -MIBG if phaeochromocytoma suspected

**Ovaries and testes.** There is no place for Nuclear Medicine in imaging these, which are best done with Ultrasound, though there is much use made of MRI in imaging gynaecological disease.

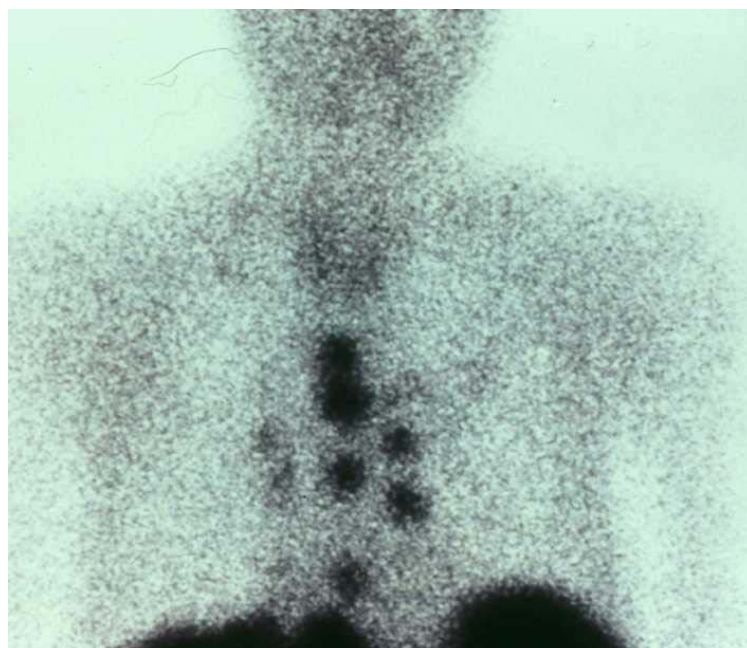
## Neuroendocrine tumours.

### Principles

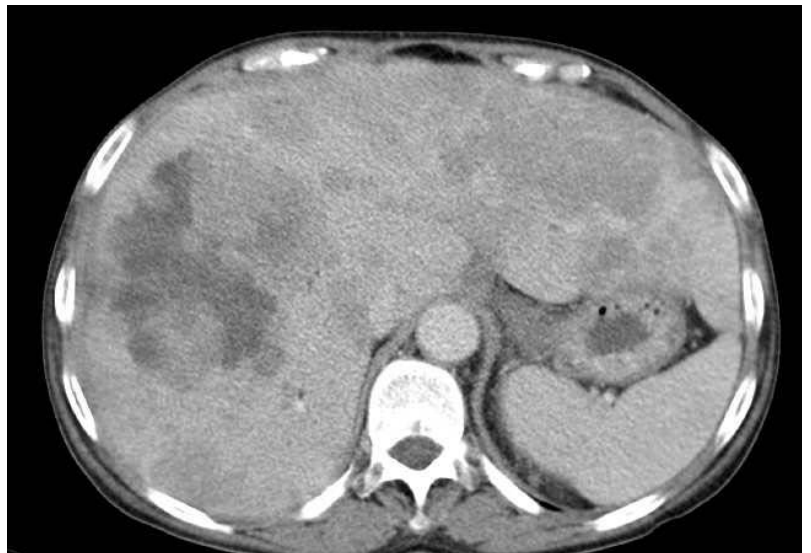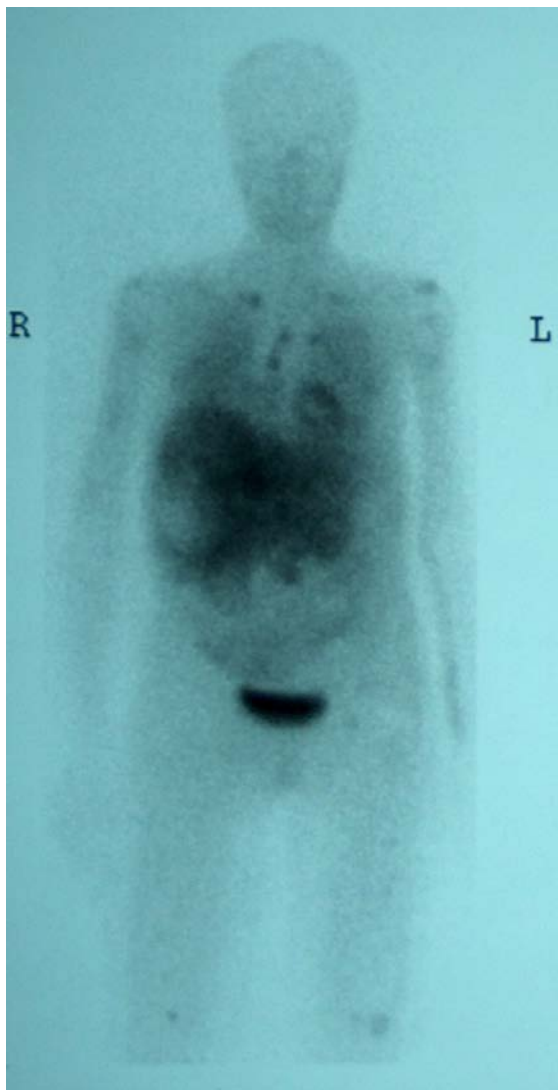
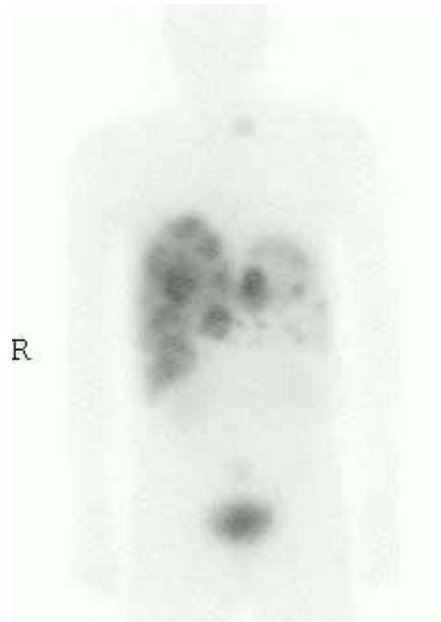
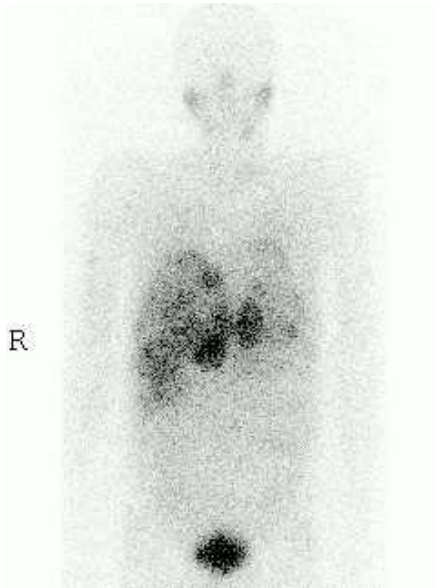
The commonest neuroendocrine tumours are carcinoid, phaeochromocytoma, Conn's, gastrinoma and VIPoma. They present clinically with hormonal and constitutional abnormalities, and are diagnosed biochemically. Since they can occur anywhere, physiological imaging using Nuclear Medicine techniques is more helpful initially than anatomical imaging with CT or MRI.

### How to perform the Nuclear Medicine tests

Carcinoid is best imaged using a labelled somatostatin analogue such as  $^{111}\text{In}$ -octreotide. The administered dose is around 200 MBq.



The above image shows the widespread carcinoid deposits in the thorax. Carcinoid can also be imaged with  $^{123}\text{I}$ -MIBG (administered dose 400 MBq), and the two images below are of the same patient; the image on the left is taken with  $^{111}\text{In}$ -octreotide and that on the right with  $^{123}\text{I}$ -MIBG. Not all carcinoids take up both agents, but should the lesions be seen using  $^{123}\text{I}$ -MIBG, then there is the possibility to treat the disease with  $^{131}\text{I}$ -MIBG.





The CT and whole body images above show a patient with carcinoid with hepatomegaly and a large necrotic lesion in the liver, as well as deposits in the thorax.

The adrenal neuroendocrine tumours have been discussed under 'Adrenal Imaging'.

Gastrinoma and VIPoma are best imaged with CT, and may need angiography and venous sampling. These specialised tests need to be discussed with the appropriate radiologist.

### **Diagnostic algorithm**

Biochemistry

Somatostatin analogue imaging and MIBG imaging to assess possibility of therapy

CT/MRI

Vascular intervention

### **Contraindications**

Pregnancy

## **GASTRO-INTESTINAL IMAGING**

There are two main subdivisions - bowel and hepato-biliary.

### **a) Bowel Imaging**

#### **Principles**

The bowel is imaged radiographically using barium sulphate liquid and air to get a double contrast study, either of the stomach and small bowel, or of the colon.



These normal images show the upper oesophagus (on the left) and the stomach.

Nowadays, the stomach and oesophagus are best visualised endoscopically, as is the colon. Virtual colonoscopy using CT is also employed.

Upper gastrointestinal bleeding may result from varices, ulcers (both benign and malignant), arteriovenous malformations or Meckel's diverticulum. Lower gastrointestinal bleeding may result from polyps, tumours or inflammatory bowel disease.

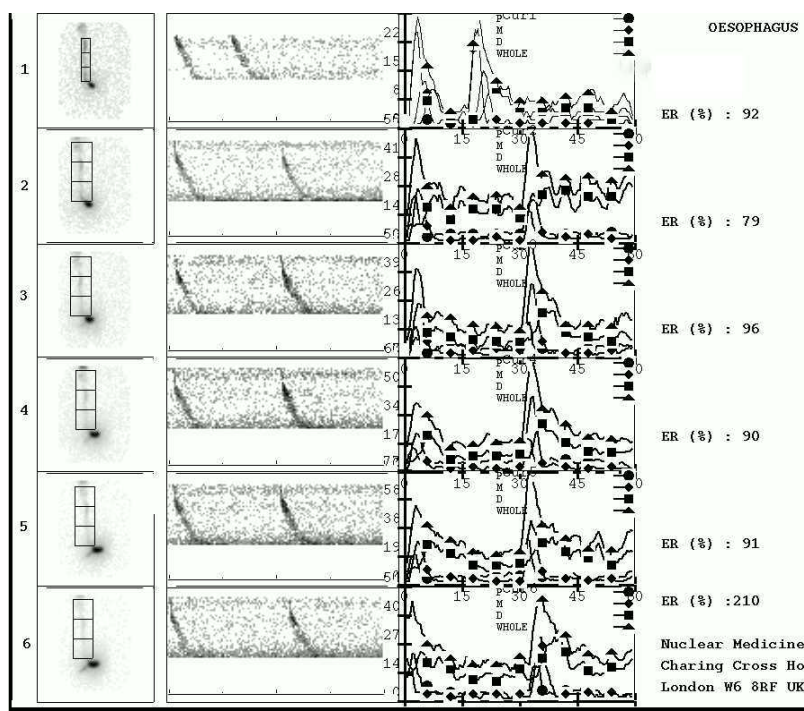
#### **Indications**

Nuclear Medicine studies have a place to play in upper GI work in oesophageal transit studies and gastric emptying studies, in assessing sites of inflammatory bowel disease, both in the small and the large bowel, and in cases of GI blood loss from arteriovenous malformations, Meckel's or inflammatory bowel disease.

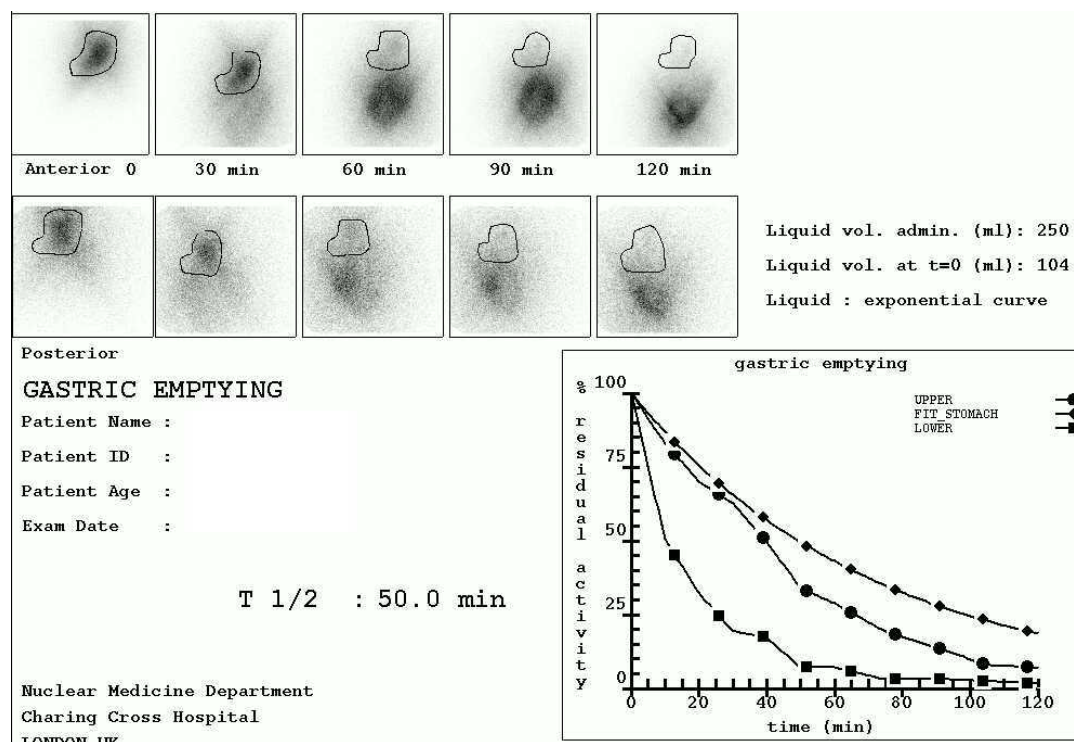
PET/CT is now widely used in the evaluation of oesophageal and gastric cancer.

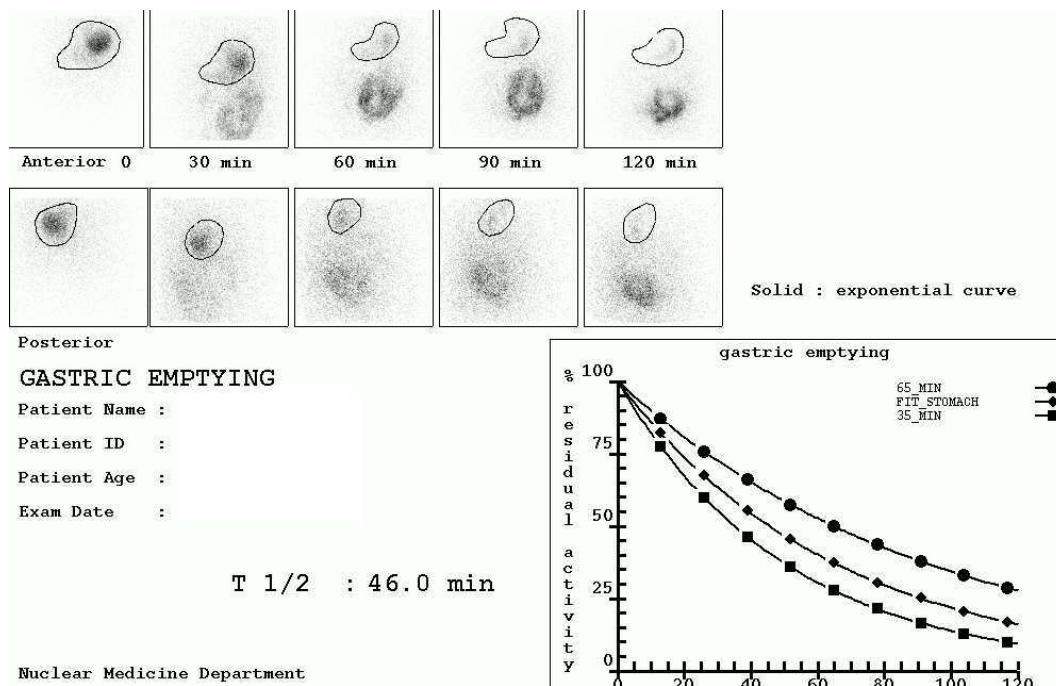
#### **How to perform the Nuclear Medicine tests**

In oesophageal transit studies, the patient repeatedly swallows a bolus of liquid labelled with 12 MBq  $^{99m}\text{Tc}$ -DTPA whilst seated in front of the gamma camera, and the acquisition allows calculation of the transit time.



Gastric emptying studies involve the patient eating and drinking, the food labelled with 12 MBq  $^{99m}\text{Tc}$  colloid for the solid and 12MBq  $^{111}\text{In}$ -DTPA for the liquid, and again images obtained at ½ hour intervals. The emptying time for solid and liquid is then calculated.

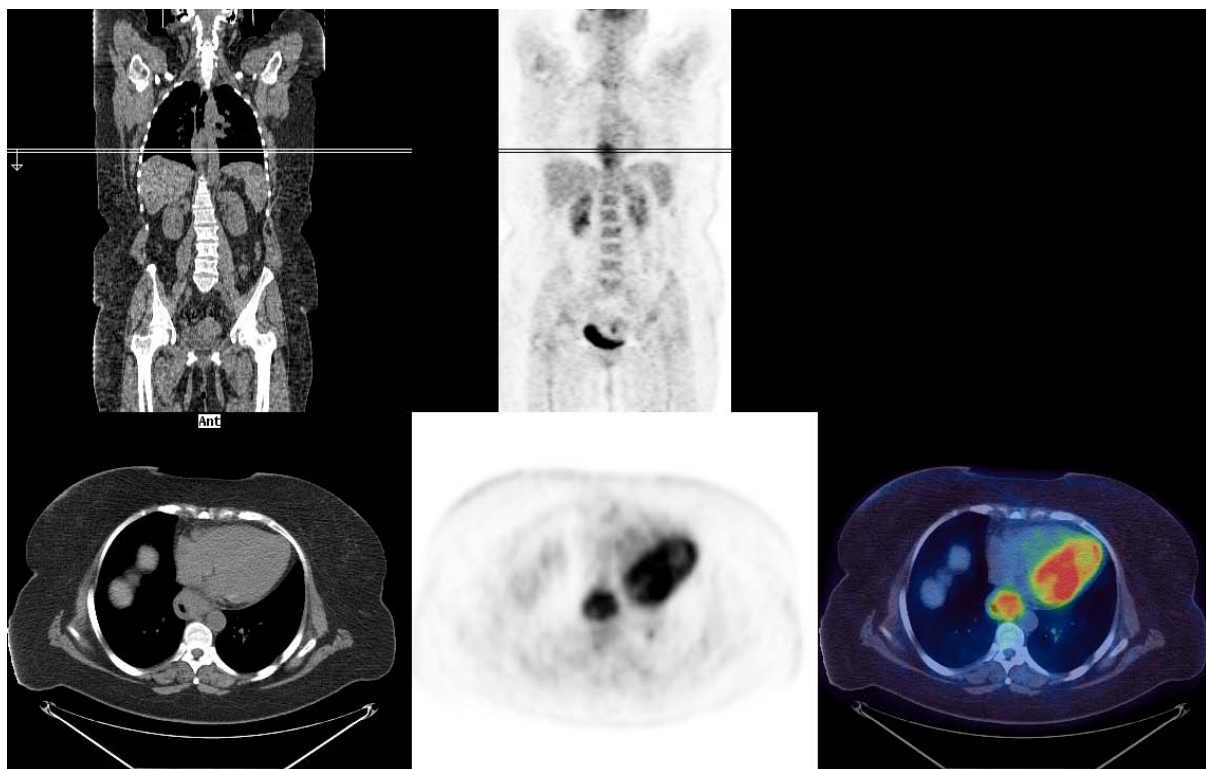




Normal  $t_{1/2}$  for liquid is <30 mins and for solids <90 mins.

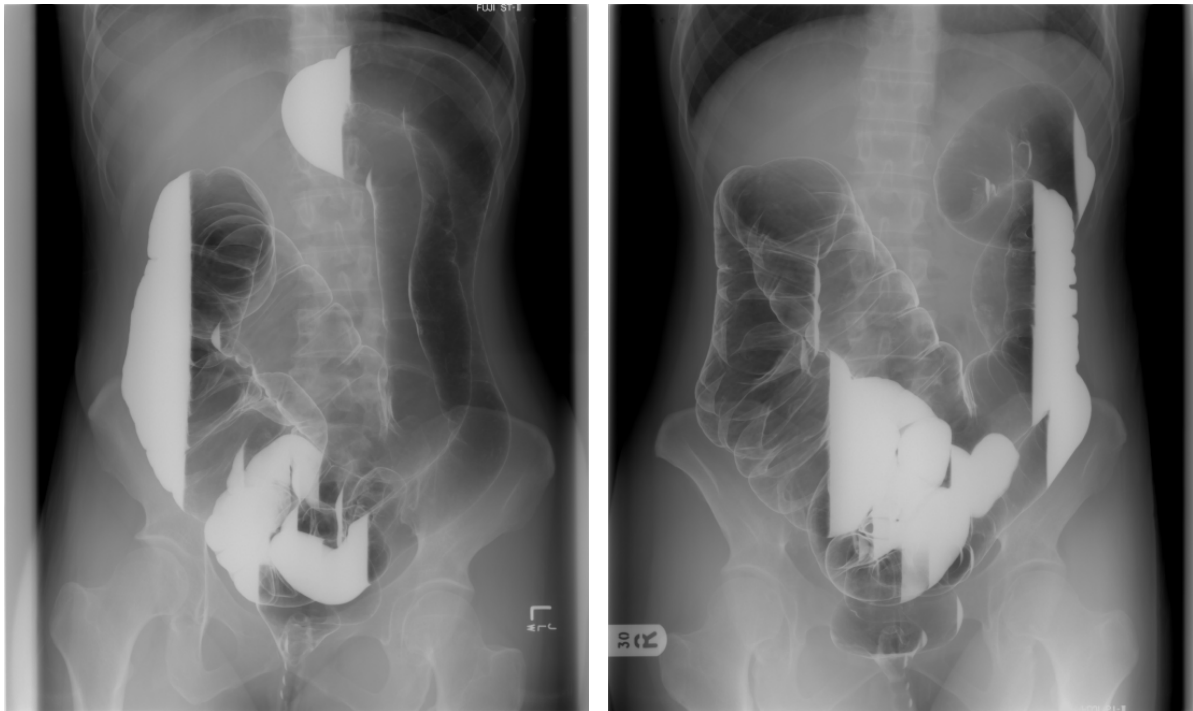
These studies are used in cases of diabetes where there are neurologic problems involving the oesophagus and stomach.

PET/CT studies follow the normal protocol, injecting 350 MBq  $^{18}\text{F}$ -FDG with the patient lying quietly in a darkened room, and the images acquired after 60 mins.

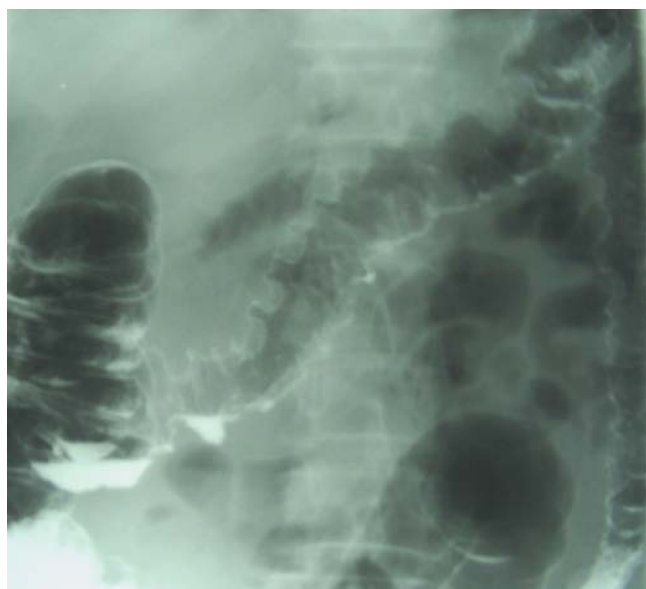


These images clearly demonstrate the thickened irregular oesophagus with intense metabolic activity, typical of a carcinoma. An added advantage is that any metastases are easily identified.

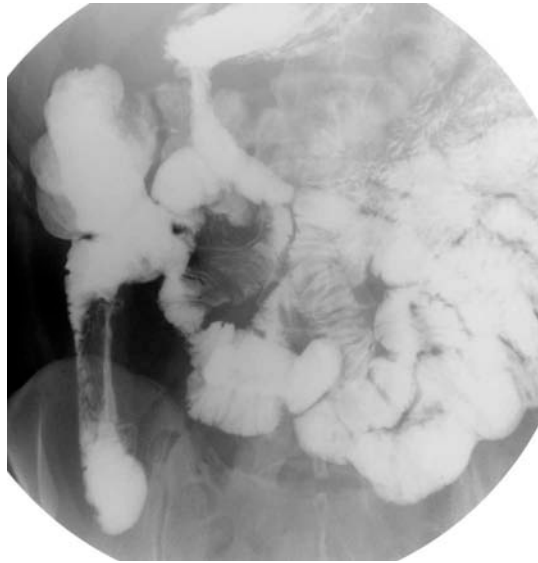
Inflammatory bowel disease is usually investigated radiologically with barium studies, or colonoscopy. This latter allows biopsies to be taken.



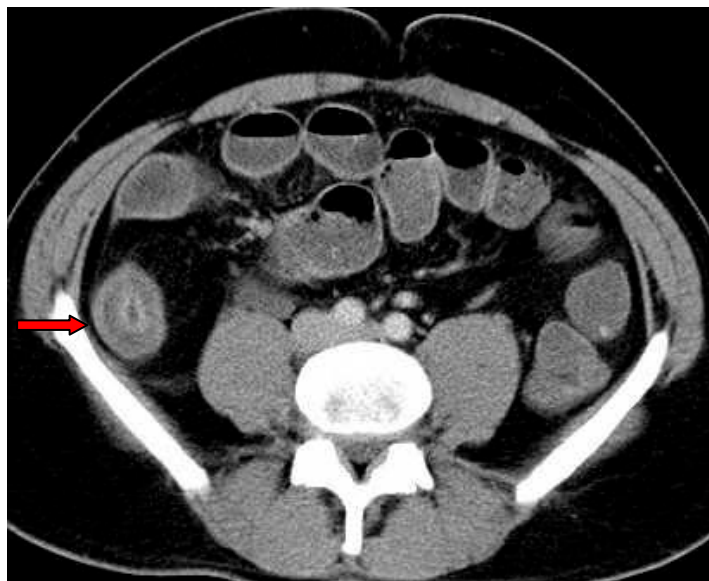
These are 2 lateral decubitus views from a barium enema.



Barium studies can show the extent of disease such as Crohn's, above, in the transverse colon, but cannot show the amount of active disease, and for this, a Nuclear Medicine labelled white cell study is performed.



This barium follow-through image shows the typical stricture of Crohn's disease in the terminal ileum. This is confirmed on CT where the thickened bowel wall is clearly seen (arrow)

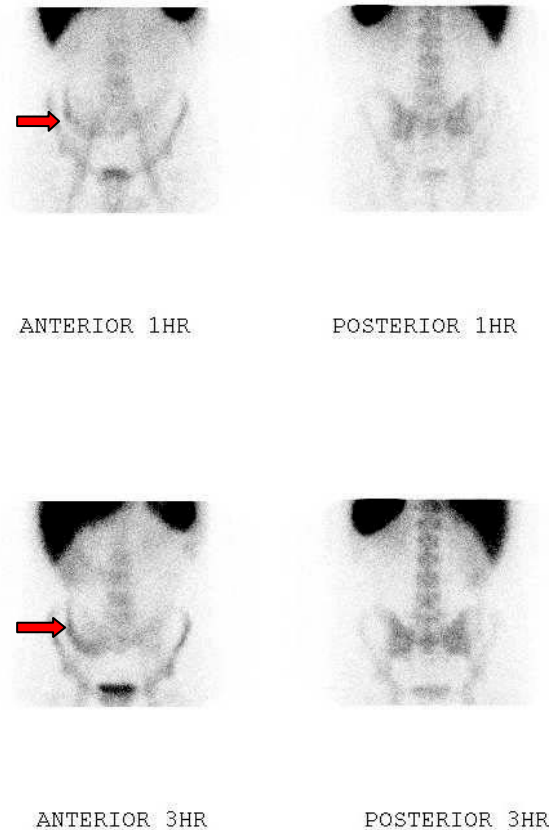


The extent of the active disease can best be shown with a labelled white cell study using  $^{99m}\text{Tc}$ -HMPAO, as in the images below. The administered activity is 200 MBq and images obtained at 1 and 3 hours after injection. The abnormal area is arrowed.

$^{99m}\text{Tc}$ -HMPAO preparation is complicated, in that 60ml blood is taken from the patient into a tube containing ACD. This is sent to the radiopharmacy where it is spun down, the white cells separated and labelled, and then washed repeatedly to remove any excess isotope. The labelled white cells in saline, which are about 6ml



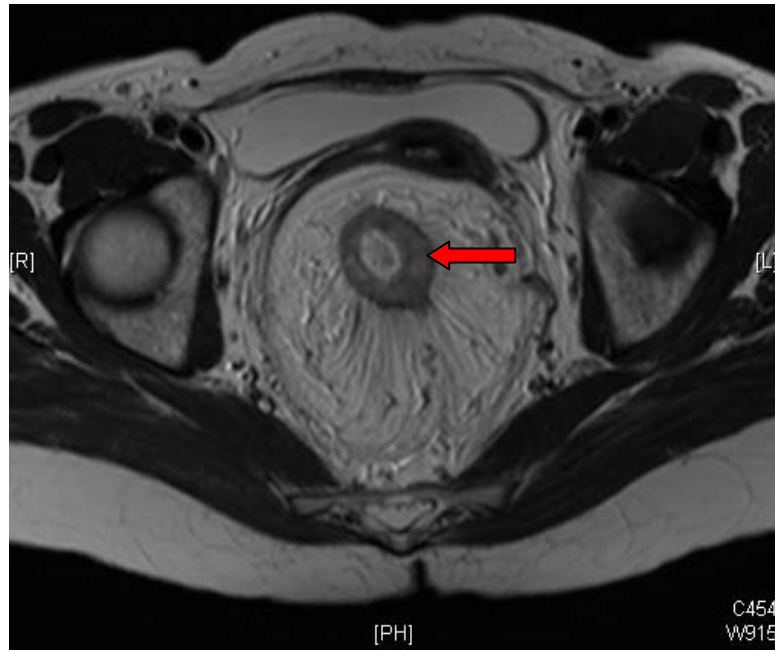
in volume, are drawn up into a syringe and re-injected into the patient. To avoid any error, the patient's details are sent with the original blood sample and are on the returned labelled white cell syringe. Also, it is prudent to have the same member of staff take the original sample and give the second injection of the labelled cells. The whole preparation time is about 3 hours.



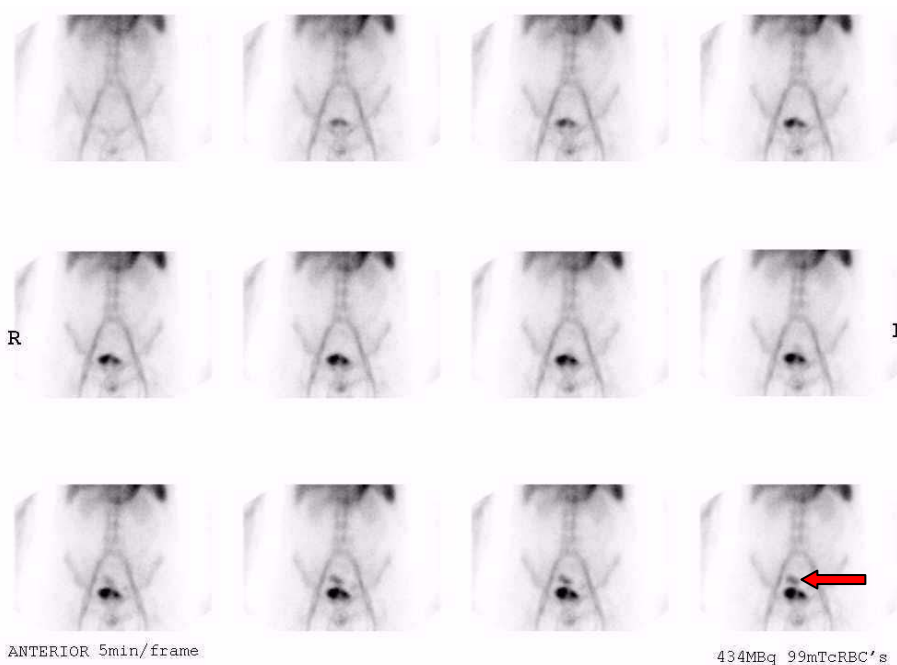
The above HMPAO images confirm the disease in the terminal ileum shown on the barium and CT is active.

Rectal Crohns can also be shown using MRI with an endo-rectal coil. The image below again shows the thickened rectal wall (arrow).



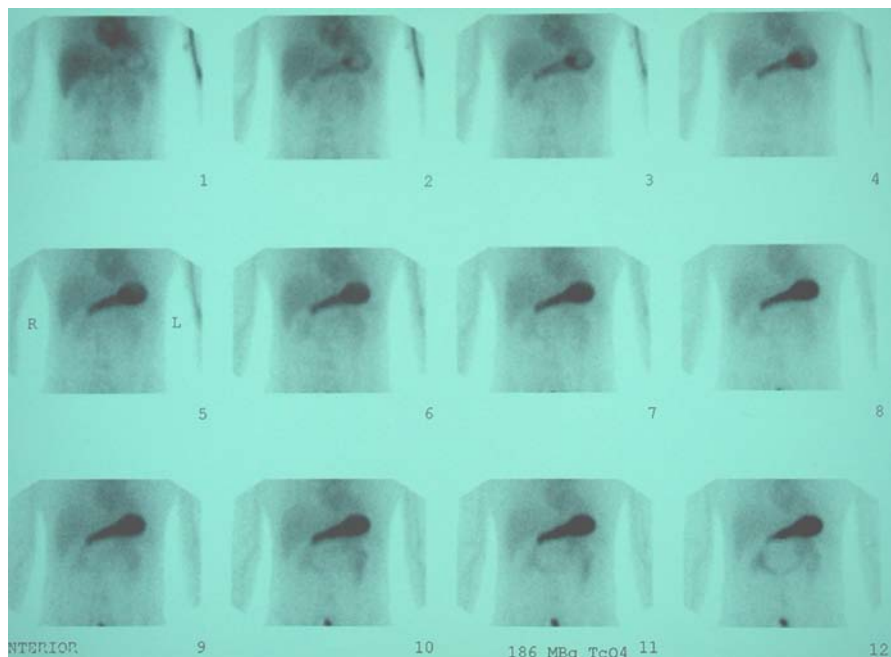


Blood loss imaging from arteriovenous malformations is occasionally investigated using red cells labelled with  $^{99m}\text{Tc}$ , as for MUGA studies. The administered dose is 400 MBq. The rationale is that there will be leakage of labelled red cells into the bowel at the site of the malformation, and serial imaging will show an increased activity (arrow).

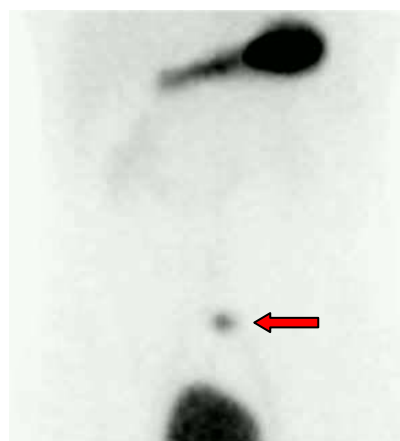


This series of images show accumulation of activity in the pelvis, above the bladder.

Meckel's diverticulum is an outpouching of the distal ileum and may bleed causing anaemia in children and young adults. However, only those diverticula containing functioning gastric mucosa bleed, and a barium follow-through may identify the diverticulum, but will not identify those with functioning gastric mucosa. To show these, a Nuclear Medicine scan using 400 MBq  $^{99m}\text{Tc}$  as pertechnetate is performed. This shows all functioning gastric mucosa, so an  $\text{H}_2$  antagonist such as cimetidine is given to reduce stomach activity.



These images show the stomach, and a small focus in the pelvis. A separate image of the lower abdomen confirms a Meckel's diverticulum with functioning gastric mucosa (arrowed), lying above the bladder.



## **Patient preparation**

For oesophageal transit and gastric emptying studies, nil by mouth for 6 hours prior to the test. For labelled white cell studies for inflammatory bowel disease, there is no special preparation. For Meckel's imaging, nil by mouth for 6 hours and cimetidine prior to the test. Nil by mouth for 6 hours before PET/CT.

## **Contraindications**

Pregnancy

## **Diagnostic algorithms**

Upper GI - endoscopy

Oesophageal transit and gastric emptying in special cases

PET/CT in cases of tumour

Lower GI - barium studies or colonoscopy

Labelled white cell studies

Blood loss studies

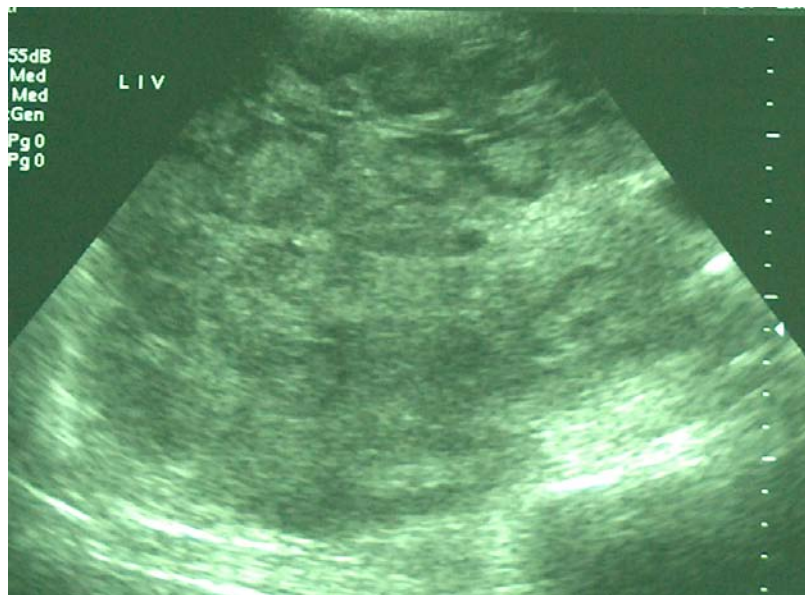## **b) Hepato-biliary imaging**

### **Principles**

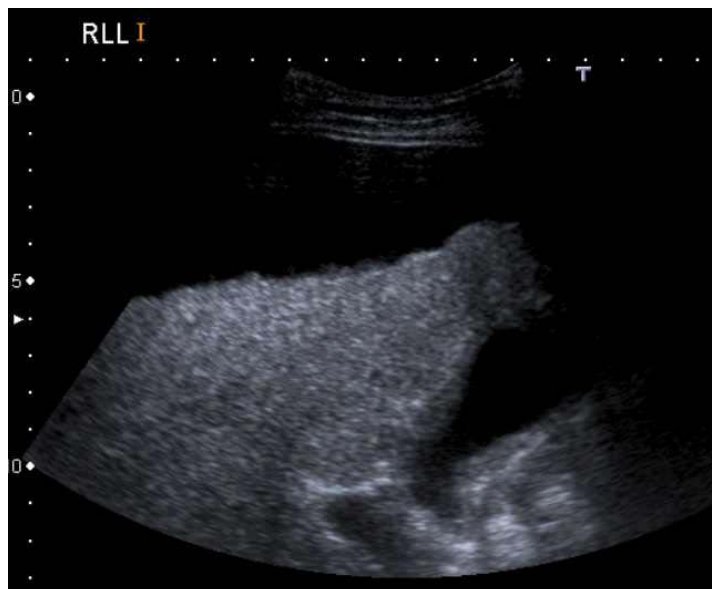Historically, the liver was imaged with  $^{99m}\text{Tc}$  labelled sulphur colloid, but this is not used now. The liver is best imaged with Ultrasound or CT. However, Nuclear Medicine is used in liver imaging with PET or PET/CT.

The spleen can be imaged with denatured red cells or sulphur colloid labelled with  $^{99m}\text{Tc}$ .

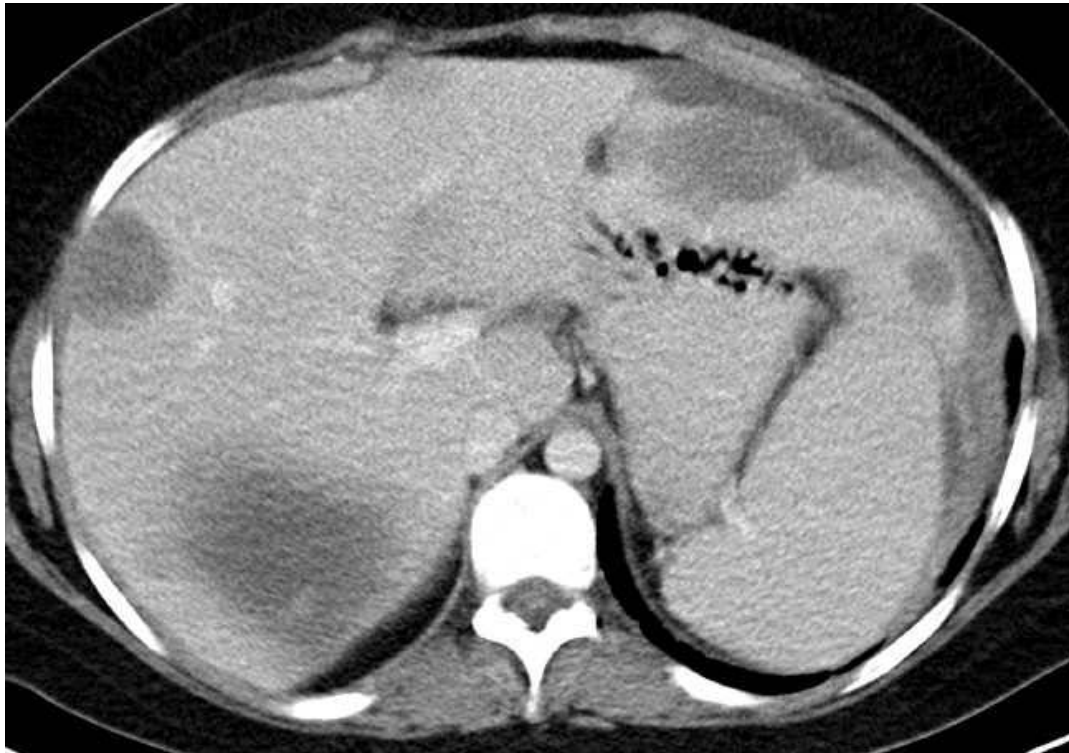
Nuclear Medicine liver imaging is now largely concerned with biliary dynamics.



This ultrasound image clearly shows well defined metastases.



This Ultrasound image clearly shows a knobby shrunken liver surrounded by ascites (fluid=black). The diagnosis is cirrhosis of the liver.



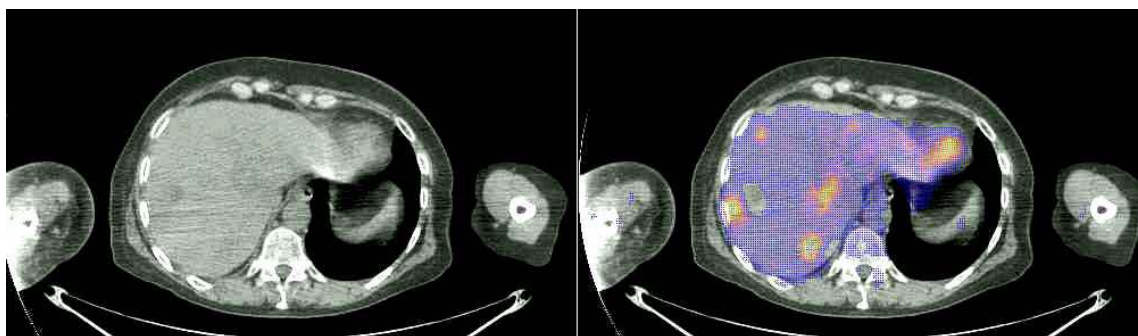
This CT slice clearly shows the liver and spleen, with several low density lesions in the liver. These are metastases.

#### How to perform the Nuclear Medicine tests

PET/CT uses  $^{18}\text{F}$ -FDG (350 MBq). The images are acquired 60 mins after injection.

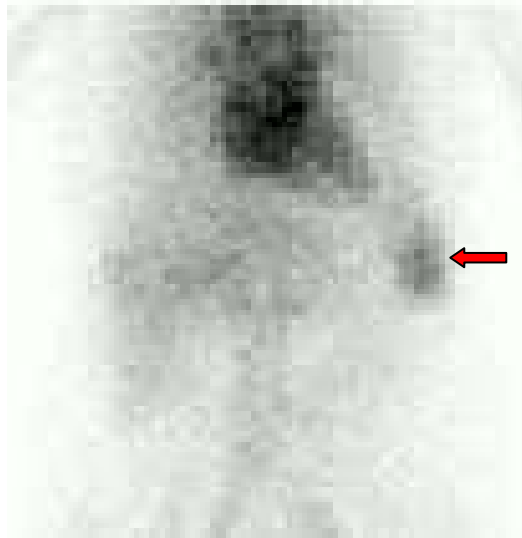
The denatured red cells are labelled with  $^{99\text{m}}\text{Tc}$ , administered activity 100 MBq, and the images acquired after 15-30 mins.

PET/CT images superimpose the PET (metabolic images) on the CT, and in the example below clearly show the widespread liver metastases which are not well seen in the CT alone. The isotope used is  $^{18}\text{F}$ -FDG, a glucose analogue. Note that the one lesion in the right lobe of liver on CT that does not take up FDG is a haemangioma.



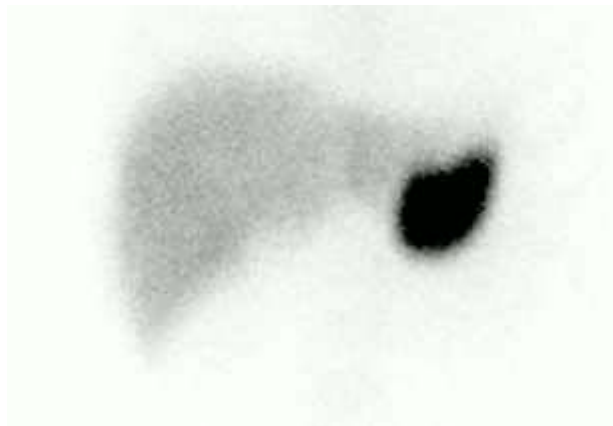
Courtesy of Dr Gary Cook, Royal Marsden Hospital, London

The spleen is normally imaged on Ultrasound or CT, but can be visualised using either  $^{99m}\text{Tc}$ -labelled colloid or denatured red cells if there has been splenic trauma or a splenunculus is suspected.



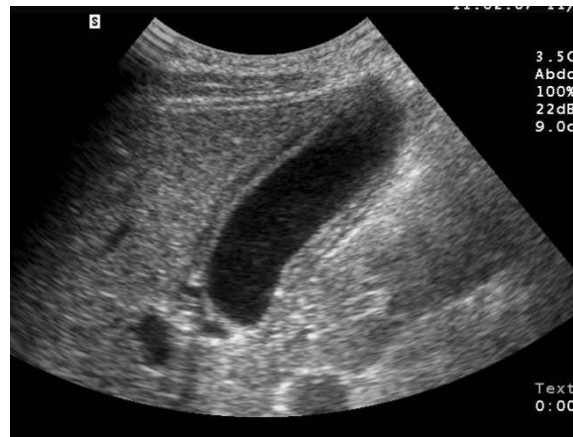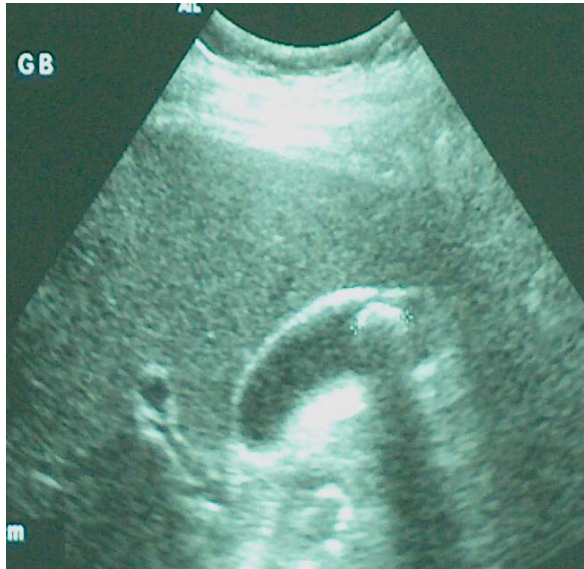This image using denatured red cells shows uptake in the LUQ due to a splenunculus (red arrow).

This image shows activity in the lower part of the spleen only, after trauma.

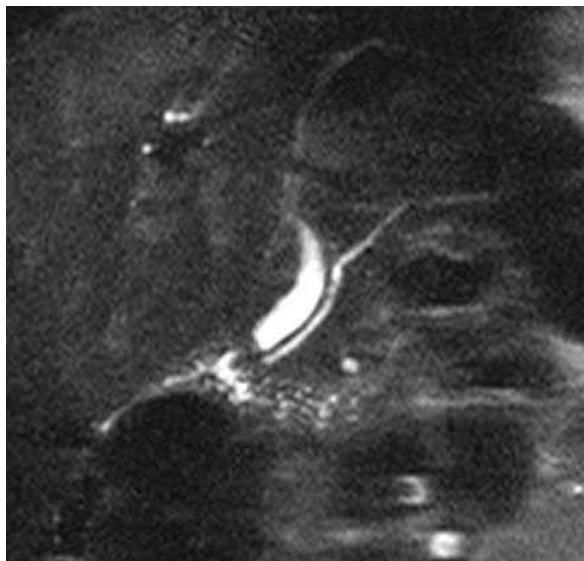




Biliary tract and gall bladder are now almost always imaged using Ultrasound, which will demonstrate thickening of the wall, stones or fluid around the gall bladder. The left image shows a white gallstone, casting an acoustic shadow. The right image shows thickening of the gall bladder wall.



The biliary tree is most elegantly demonstrated using MRI.



### Principles and Indications

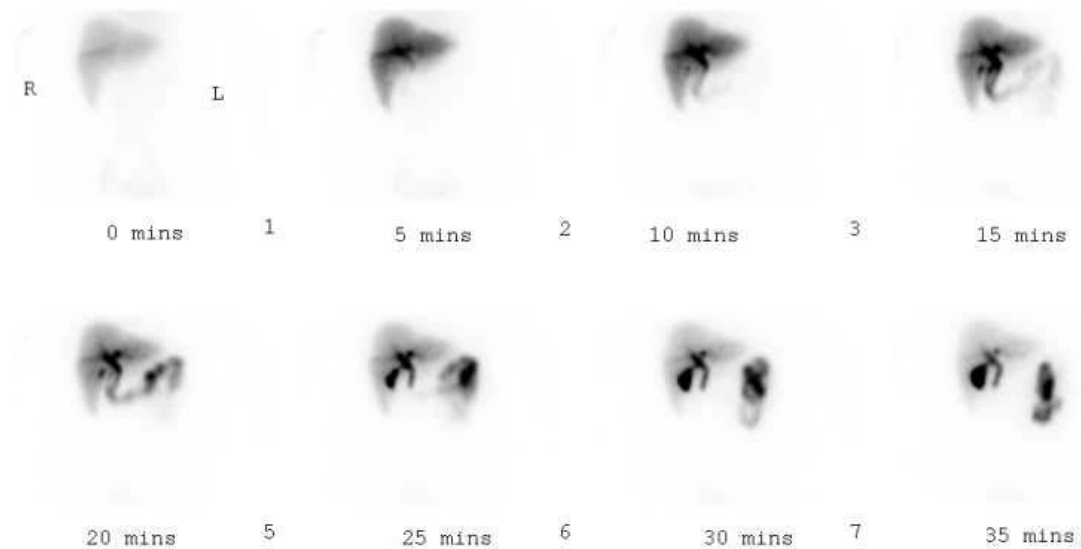
The only role for Nuclear Medicine is to demonstrate leaks from the biliary tree after surgery, using  $^{99m}\text{Tc}$ -HIDA.




## How to perform the Nuclear Medicine tests

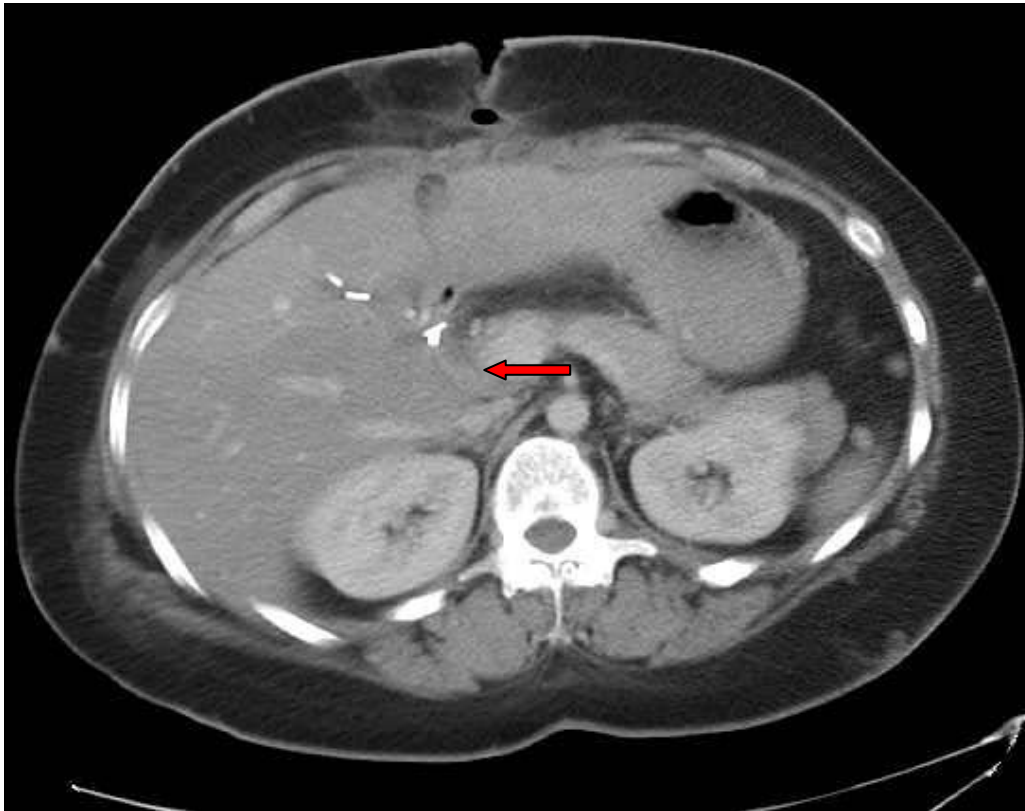
HIDA is a bilirubin analogue, and so if labelled with  $^{99m}\text{Tc}$  (150 MBq), then after i.v injection, sequential imaging will demonstrate the biliary tree and gall bladder.

The image below is a normal HIDA scan showing activity passing down the CBD into the gall bladder and duodenum.



This set of images is from a patient who had an endoscopic cholecystectomy but persisted in draining bile. There is no activity seen in the CBD. A CT showed that a clip had been put across the CBD at surgery (arrowed).





### **Contraindications**

None

### **Patient preparation**

No special requirements

### **Diagnostic algorithms**

#### **a) Liver**

Ultrasound

CT

PET/CT in cases of liver tumours, either primary or secondary

#### **b) Gall bladder**

Ultrasound

#### **c) Biliary tree**

Ultrasound and MRI

HIDA imaging post surgical complications

## **HEAD AND NECK, AND BRAIN IMAGING**

### **Principles**

Nuclear Medicine imaging of the head and neck is quite separate from brain imaging. Head and neck imaging is mostly concerned with malignancy, but there is also a role for imaging in the investigation of epiphora.

### **Indications**

Most Nuclear Medicine head and neck imaging relates to tumour work, and is mainly done with PET or PET/CT, although sometimes conventional bone imaging is used. As with all PET/CT scans, an added advantage is that the data can be transferred to radiotherapy simulators allowing very accurate field planning.

### **How to perform the Nuclear Medicine tests**

PET/CT is performed in the standard way, images being acquired 60 mins after the administration of 350 MBq  $^{18}\text{F}$ -FDG.

Lacrimal drainage imaging uses one drop of  $^{99\text{m}}\text{Tc}$  as pertechnetate (4 MBq) instilled into each eye, the surplus wiped away, and images obtained using a pinhole collimator. Initially, 16 10second frames are acquired, followed by images at 5, 10, 15 and 20 mins.

### **Contraindications**

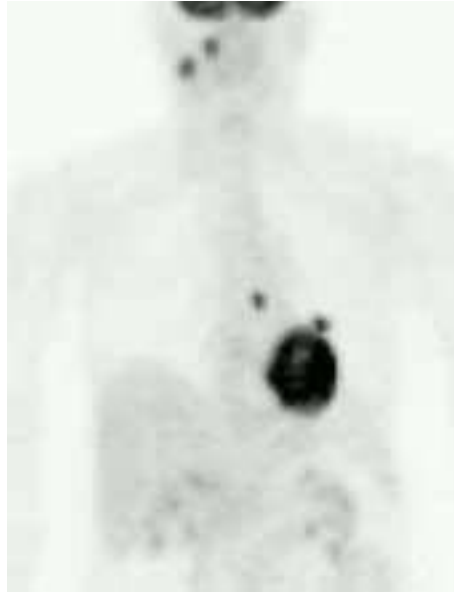
Pregnancy

### **Patient preparation**

Nil by mouth for 6 hours for PET/CT studies; no special preparation for lacrimal drainage studies.

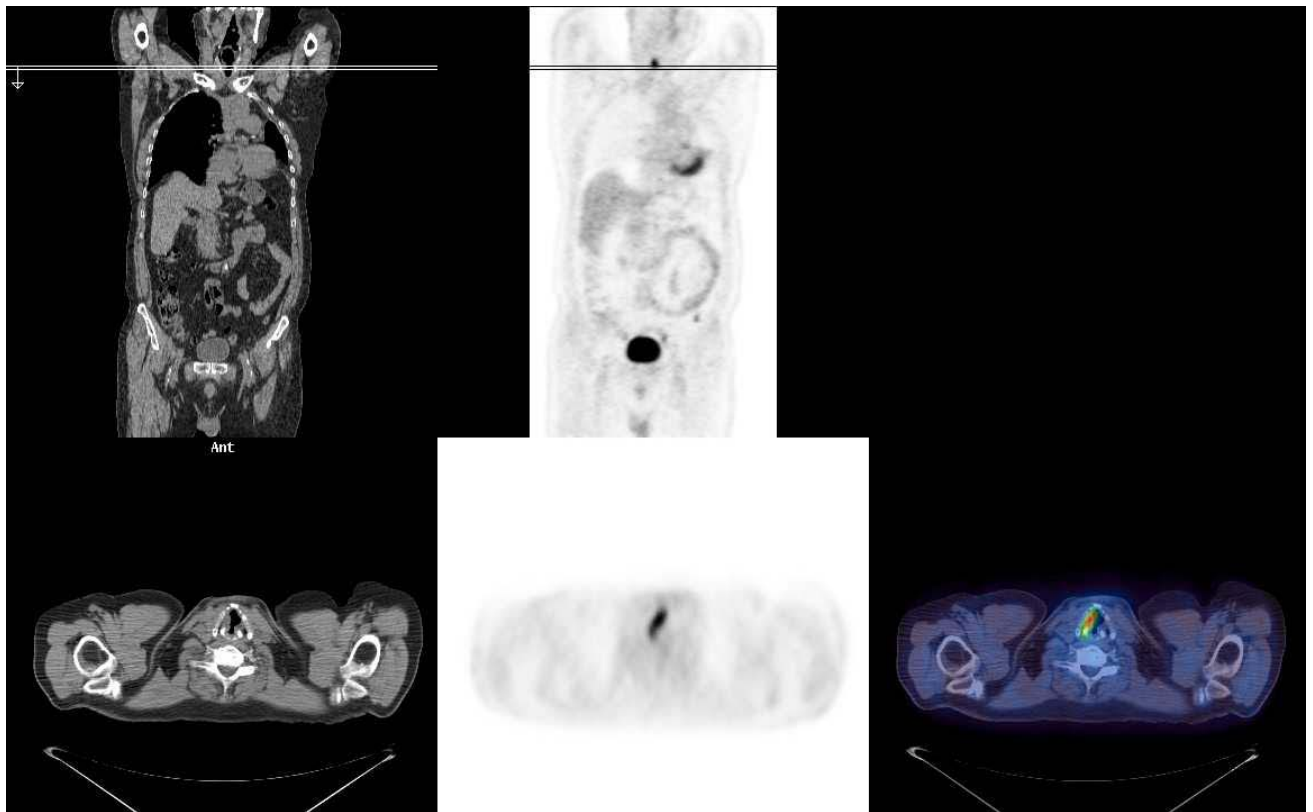
### **Examples**

Head and neck lesions may involve the vocal cords, larynx or lymph nodes. Presentation may be with alteration in voice or lumps in the neck.



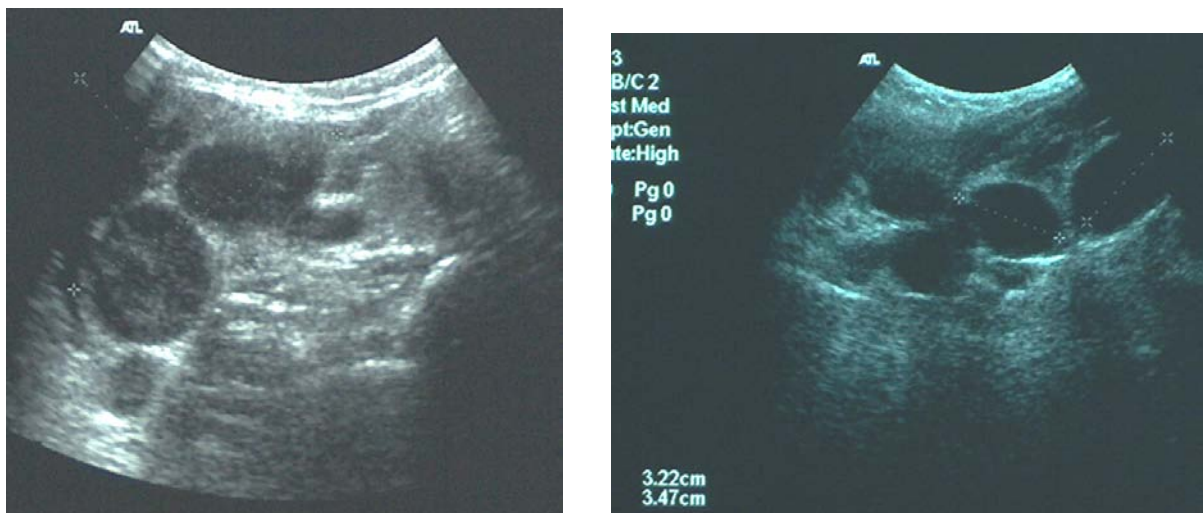
This patient presented with a lump in the neck, and the PET scan identified the lump, the primary in the tongue, and also a totally unexpected breast cancer with internal mammary node deposits. This shows the value of PET in finding tumours.

Another patient presented with irregularity of voice, and laryngoscopy showed an abnormality of the vocal cords. The PET/CT images below clearly show the abnormal FDG uptake in the right side of the neck, and the CT shows the swollen irregular right vocal cord. The composite image shows that the metabolic abnormality is confined to the one vocal cord. The appearances are those of a malignancy, and the diagnosis was confirmed on biopsy.

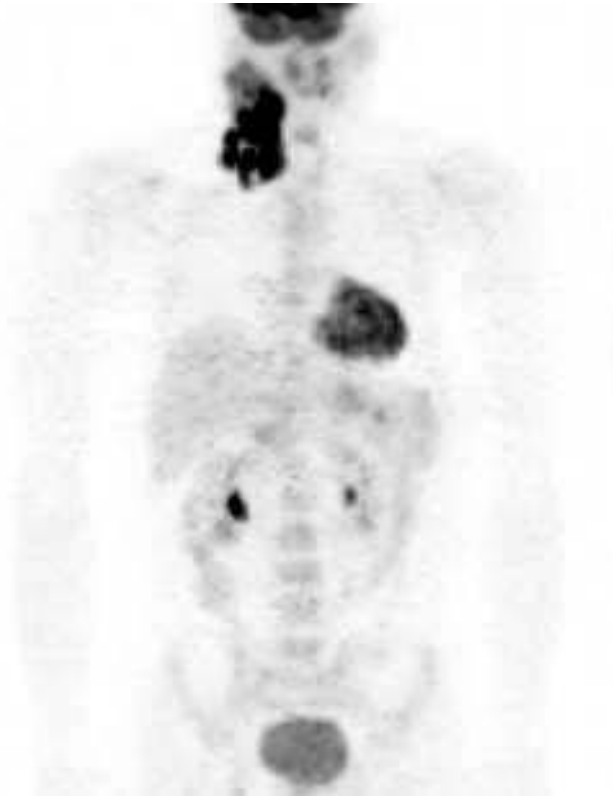

Courtesy of Dr Teresa Szyszko, Dept of Nuclear Medicine, St Thomas's Hospital, London

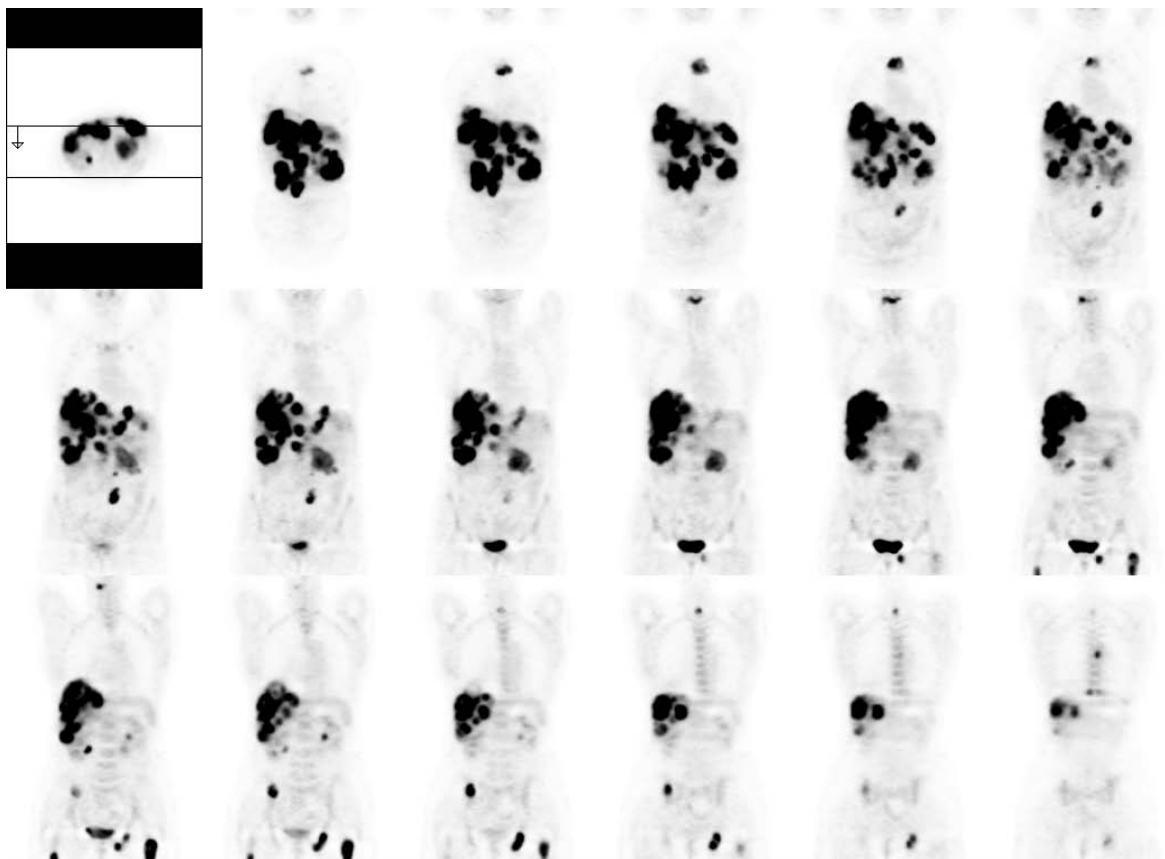
A more common cause of enlarged neck lymph nodes is lymphoma, either HD or NHL. These are best investigated with PET and Ultrasound, which allows the nodes to be easily delineated and biopsied.



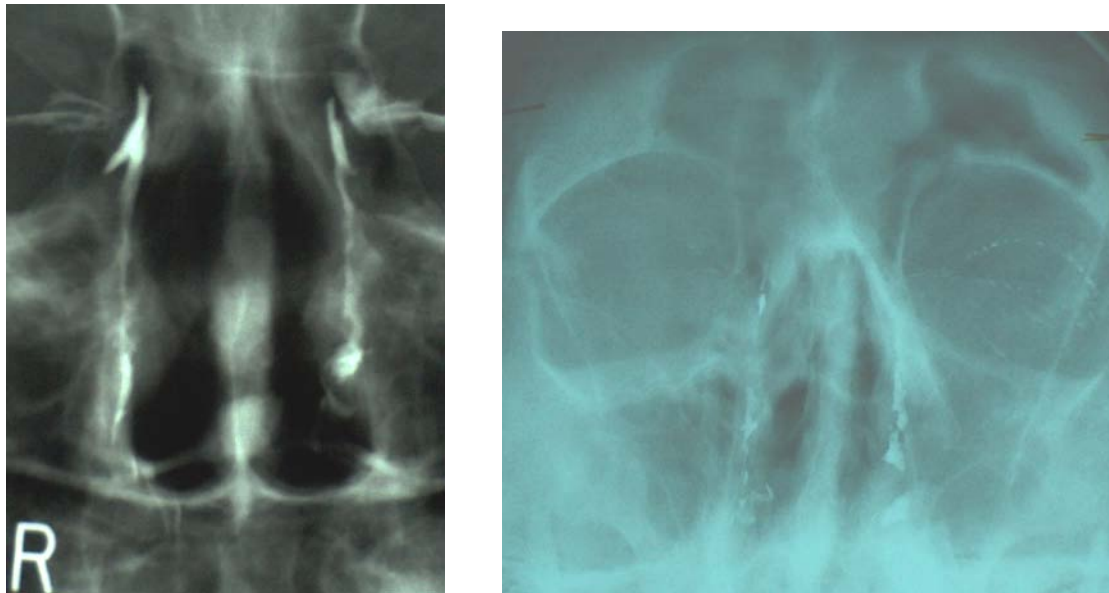
The Ultrasounds clearly show the enlarged, low-echo nodes.



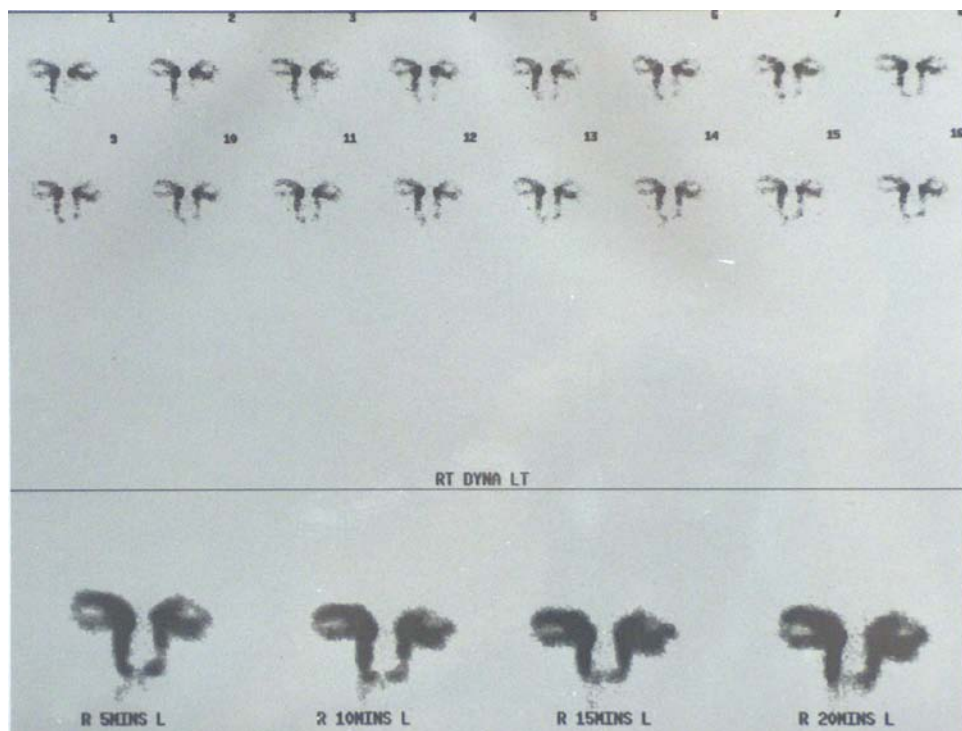
The PET study clearly shows the enlarged nodal disease in the right side of the neck. PET or PET/CT is also important in staging the disease, as below, which is stage 4b.



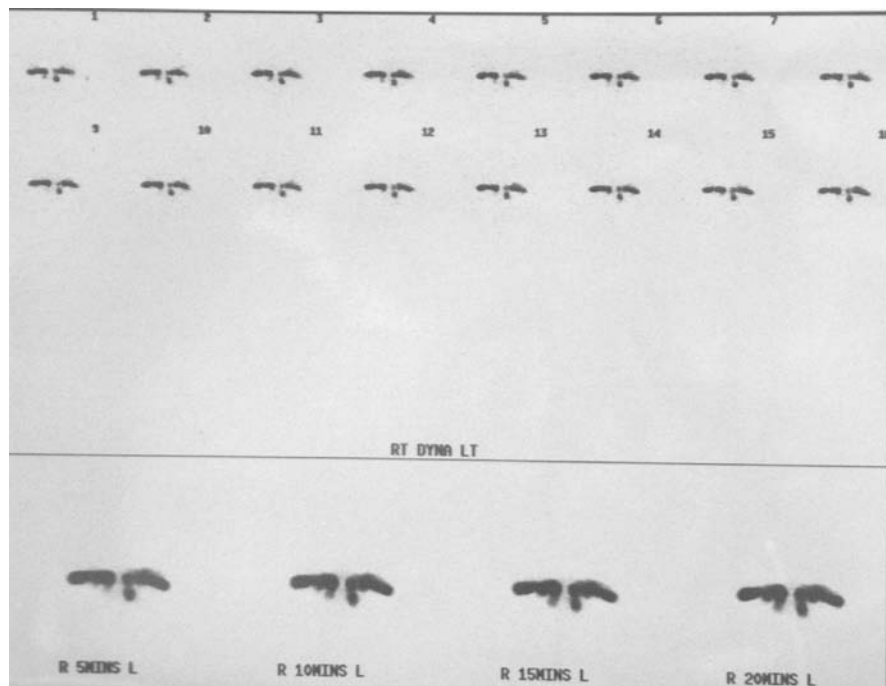
One other use of Nuclear Medicine in the head is in the investigation of epiphora. Usually, the lacrimal ducts are investigated radiologically, but as the contrast is injected under pressure, a false impression of patency may arise. A much more physiological approach is to instil a drop of  $^{99m}\text{Tc}$  as pertechnetate in each eye and image the clearance. This will show whether the duct is patent or blocked. This test is much more acceptable to patients.



The x-rays above show patent lacrimal ducts on the left and blocked on the right.





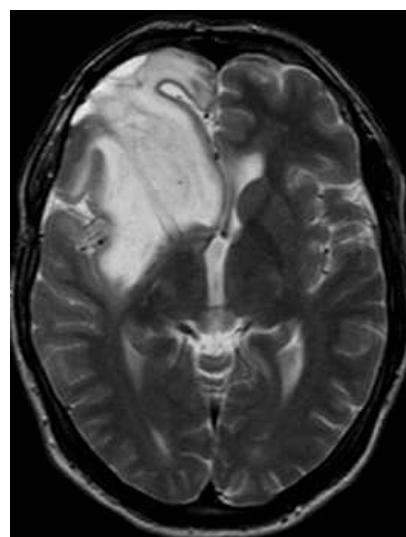
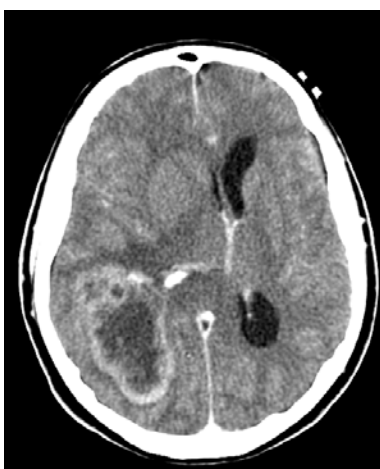

The upper Nuclear Medicine image shows normal bilateral drainage and the lower Nuclear Medicine image shows bilateral block.

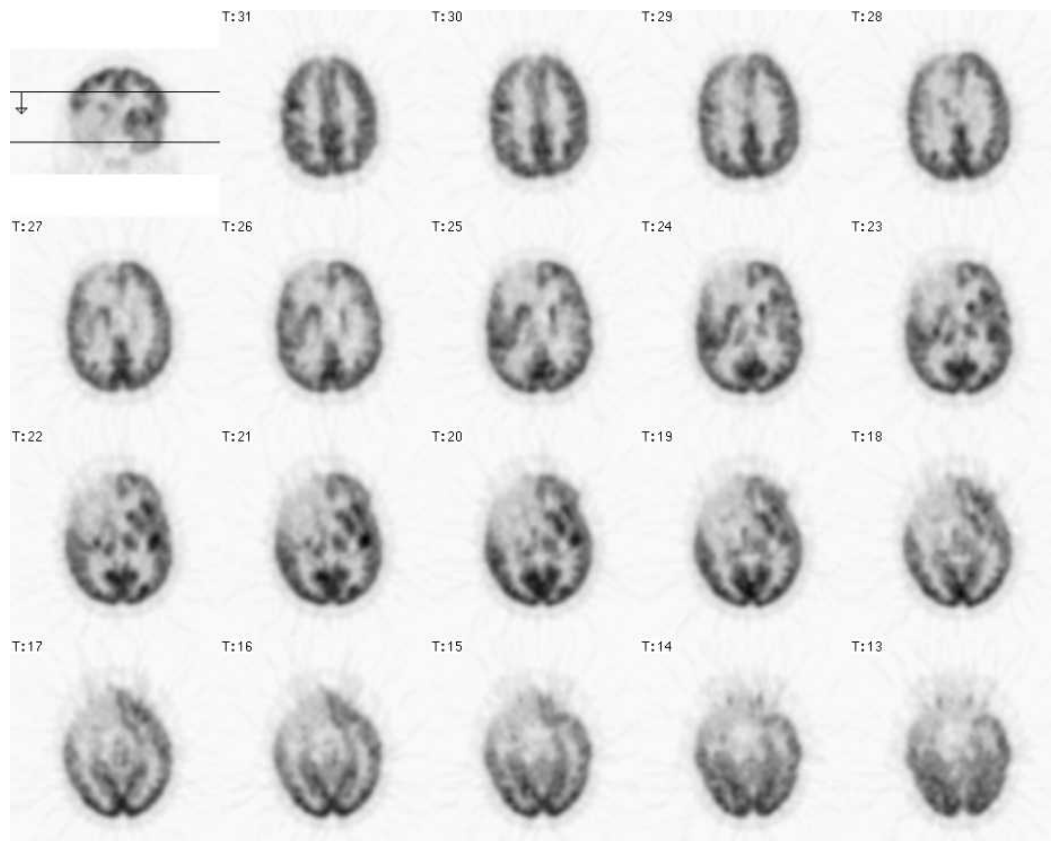
Brain imaging used to be performed using  $^{99m}\text{Tc}$  as pertechnetate, but this is no longer done, as the brain is best imaged with CT or MRI. However, there are well-defined uses of Nuclear Medicine techniques in imaging the brain.

#### a) Tumour

PET is invaluable in imaging and following up primary brain tumours to assess the results of treatment, especially when there is change on the CT or MRI.



These images of a glioma show the extent, but cannot determine whether there is active disease. This is done using PET using 250 MBq  $^{18}\text{F}$ -FDG.

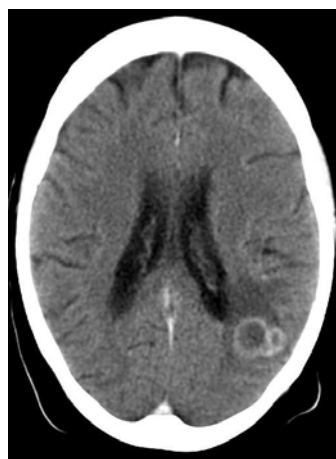

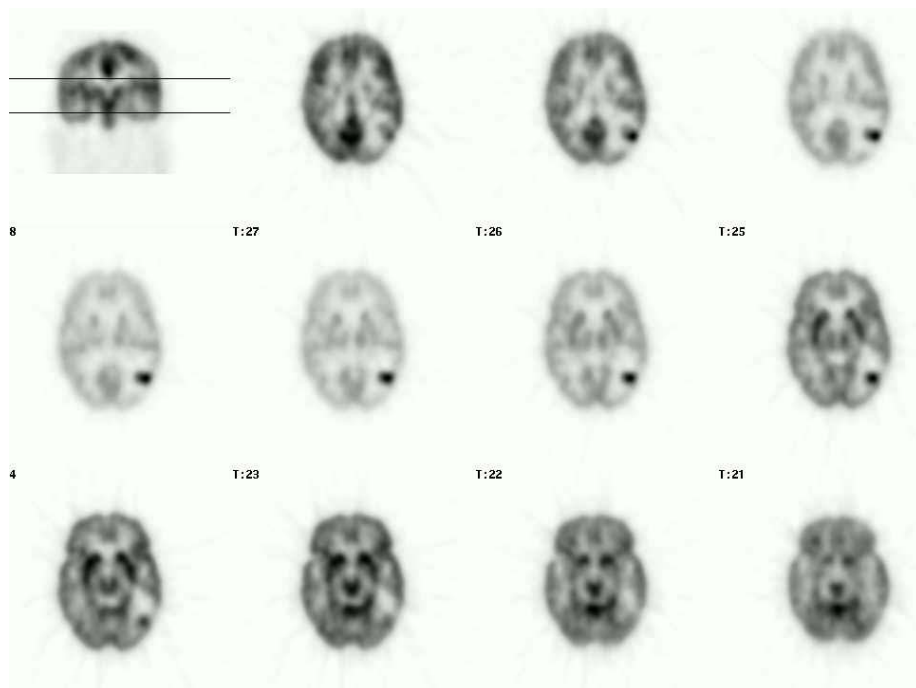
These images clearly show that there is no metabolic activity within the tumour.

#### b) Intracranial inflammatory disease

There is a role for PET in the diagnosis of intracranial infection or tumour in patients who are HIV+.

This patient had an enhancing ring abnormality on CT, which could either be infection with toxoplasmosis or tumour.

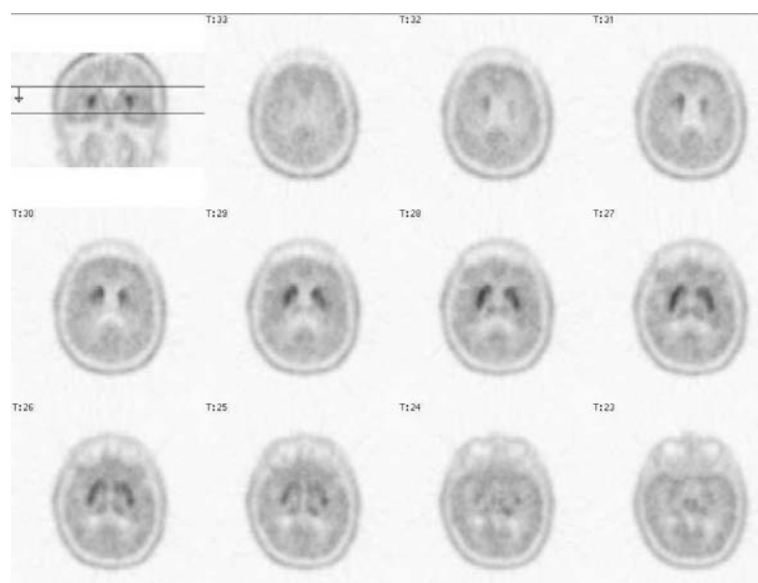




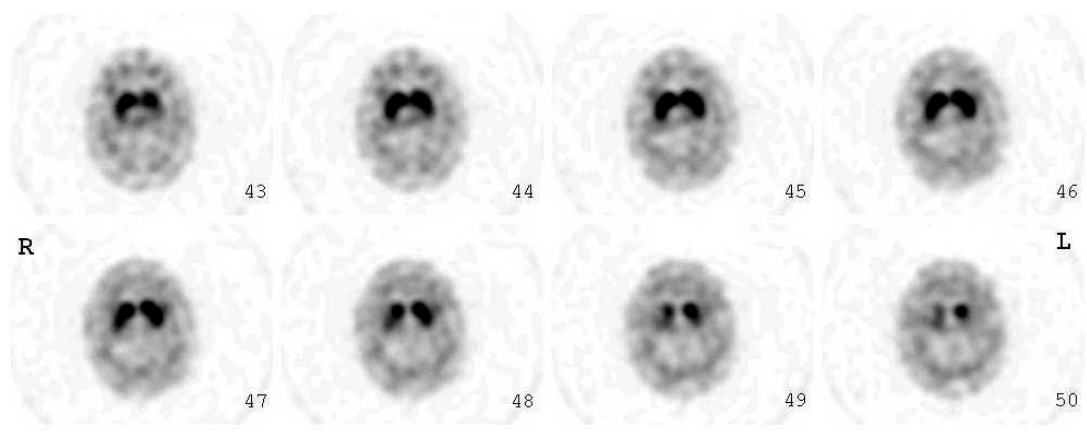
The PET confirmed abnormal uptake due to tumour (a lymphoma).

### c) Movement disorders

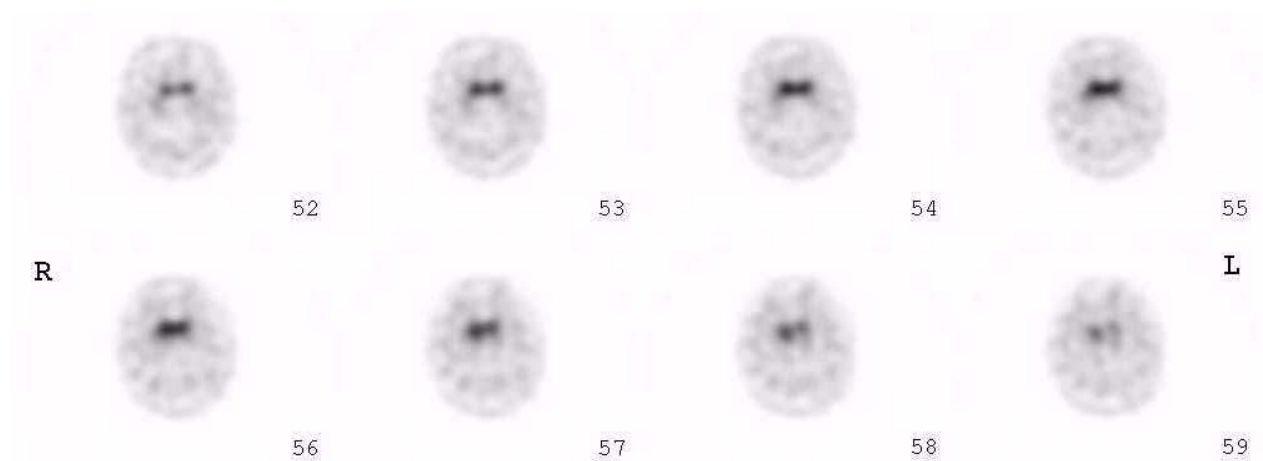
Parkinson's disease is due to depletion of dopamine transporters in the basal ganglia, and so by imaging them, a diagnosis may be made, long before the disease progresses, and so allowing treatment. The basal ganglia can be imaged using 250 MBq  $^{18}\text{F}$ -DOPA, using PET, or with 185 MBq  $^{123}\text{I}$ -ioflupane (FP-CIT), a cocaine analogue.



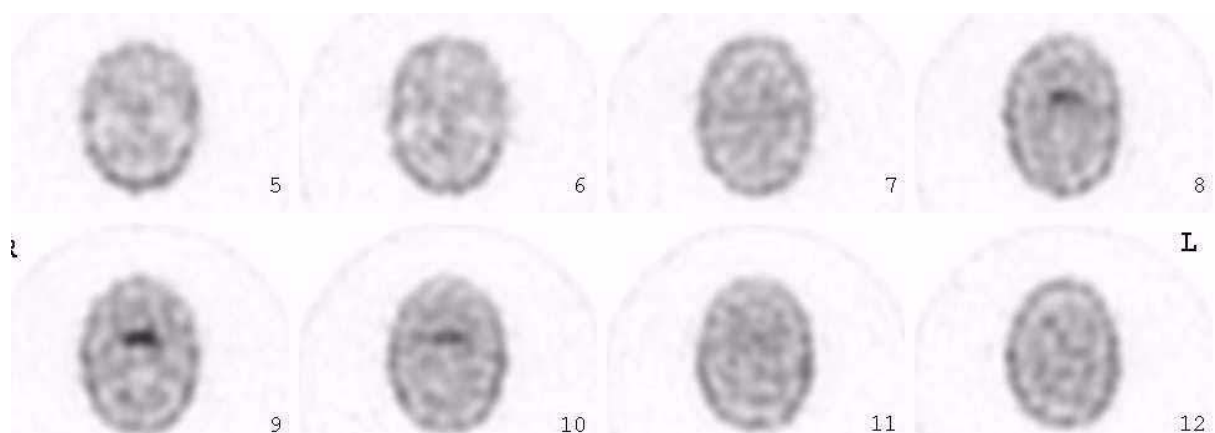
This is a normal F-DOPA scan to show the basal ganglia.



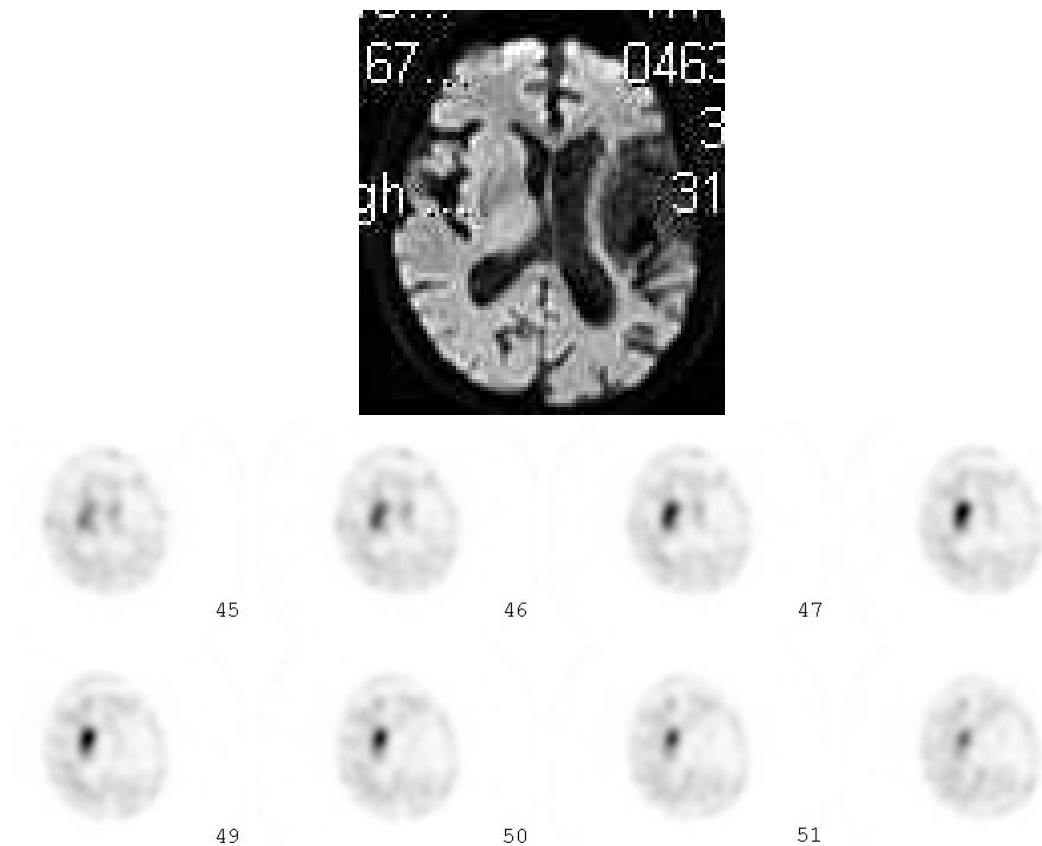
This is a normal FP-CIT scan, showing the typical crescentic uptake in the basal ganglia. As Parkinson's disease progresses, there is loss of activity in the putamen, and this may be unilateral or bilateral.



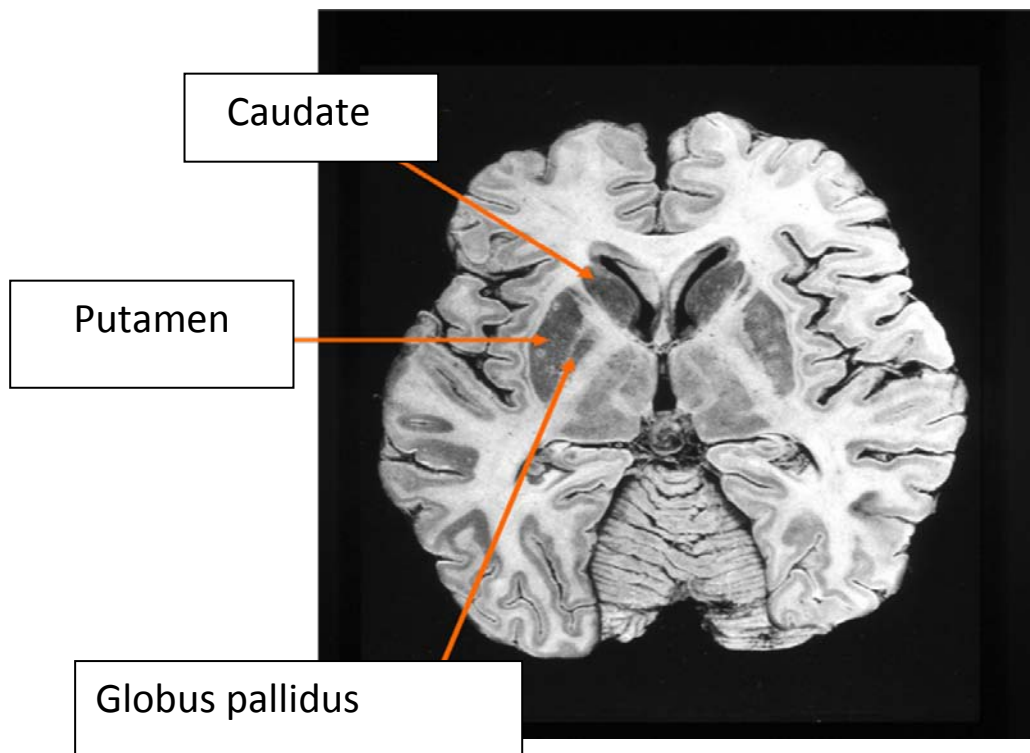
The above image shows loss of activity in the putamen bilaterally, and the image below shows even greater loss, indicating further deterioration of disease.



However, there may be loss of uptake not related to Parkinson's disease. The patient below had a stroke involving the left internal capsule.



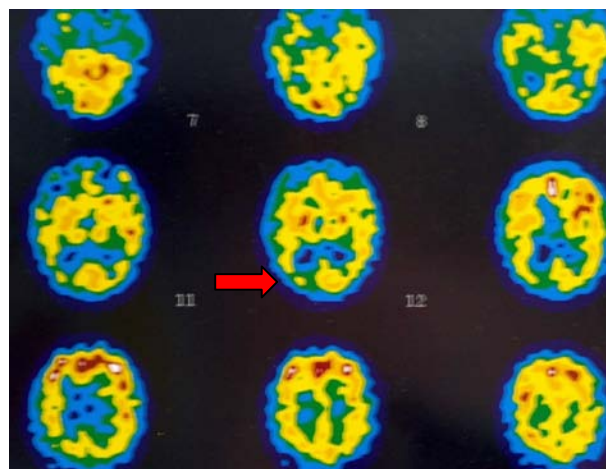
The anatomy of the basal ganglia is shown here.



#### d) Dementias

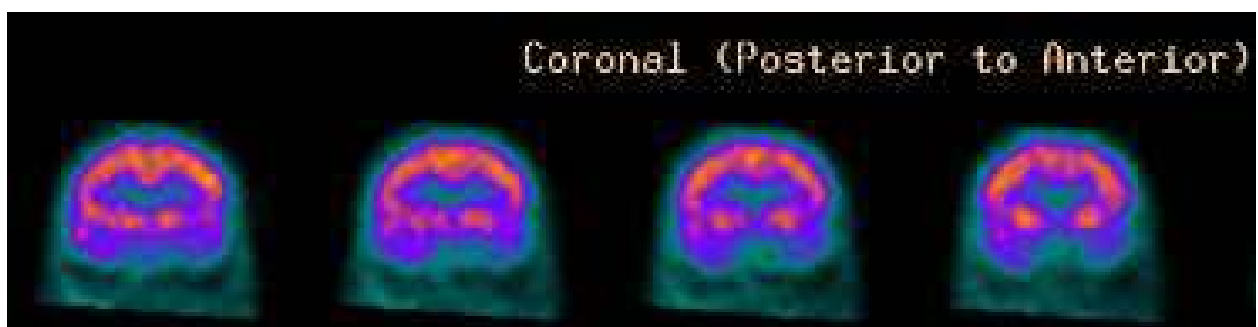
Dementia is increasing in extent of occurrence, and accurate diagnosis needs to be made to ensure the correct treatment. There are several types of dementia - commonly, Alzheimer's, Dementia with Lewy Bodies (DLB) and Multi-infarct dementia (MID). It is important to make the correct diagnosis, as Alzheimer's treatment will make DLB much worse.

In Alzheimer's there is diminished blood flow to the parieto-occipital areas, and this can be shown using 500 MBq  $^{99m}\text{Tc}$ -HMPAO to visualise the cerebral blood flow pattern.

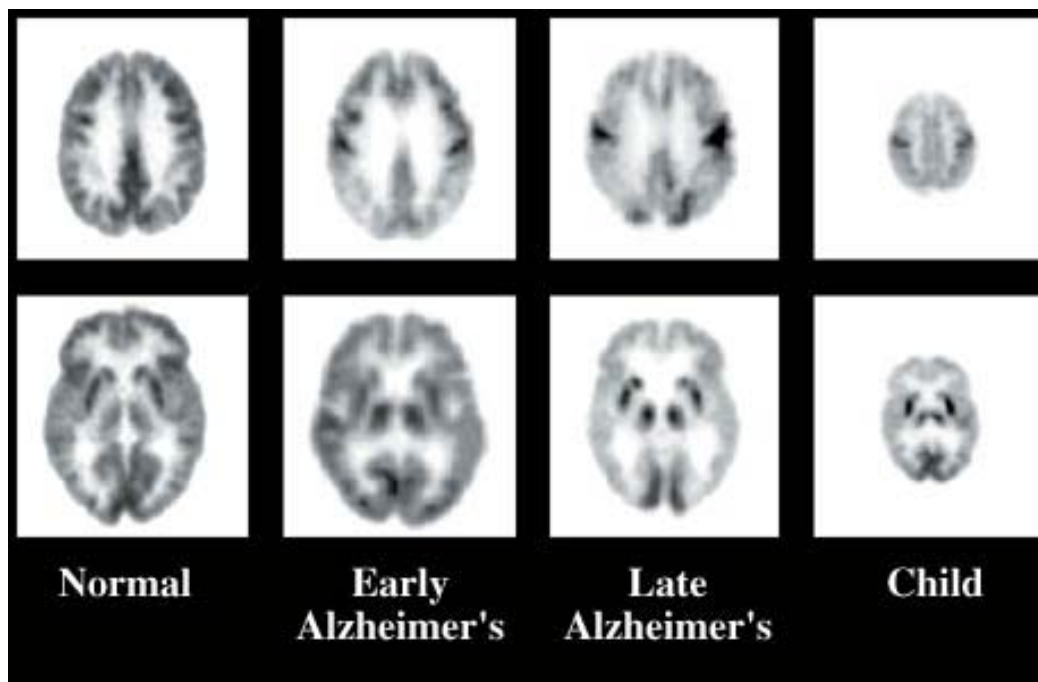


This scan shows diminished blood flow in the right parieto-occipital area (arrow) in a patient with Alzheimer's. The FP-CIT scan in Alzheimer's is normal.

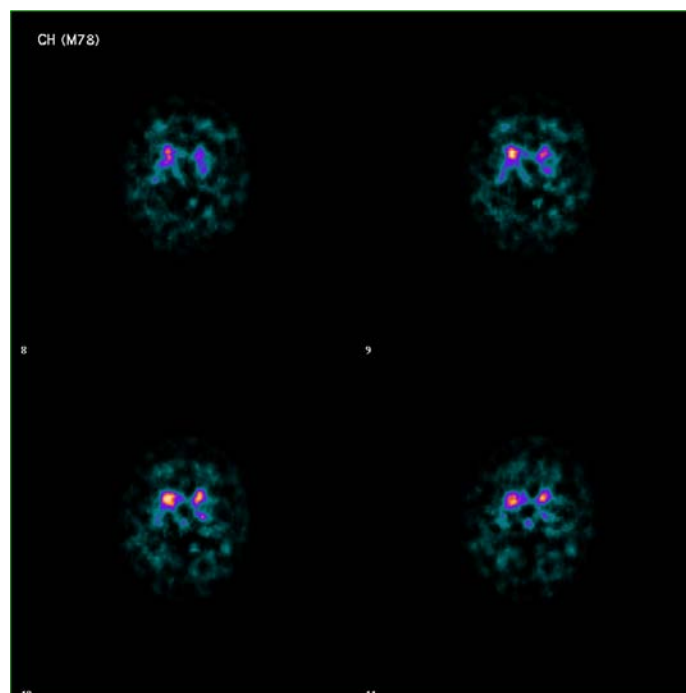
Early frontal lobe hypofunction, as shown below, with consequent memory loss can be shown using cerebral blood flow studies, and may be a precursor of Alzheimer's.



PET can also be used to show cerebral blood flow and function.



DLB shows normal cerebral blood flow, but there is loss of uptake in the basal ganglia on FP-CIT scanning, below.



Courtesy of Dr Paul Kemp, Southampton University Hospital

Although the appearances of the scan are those of severe Parkinson's disease, clinically there was no tremor or evidence of Parkinson's disease. There had been

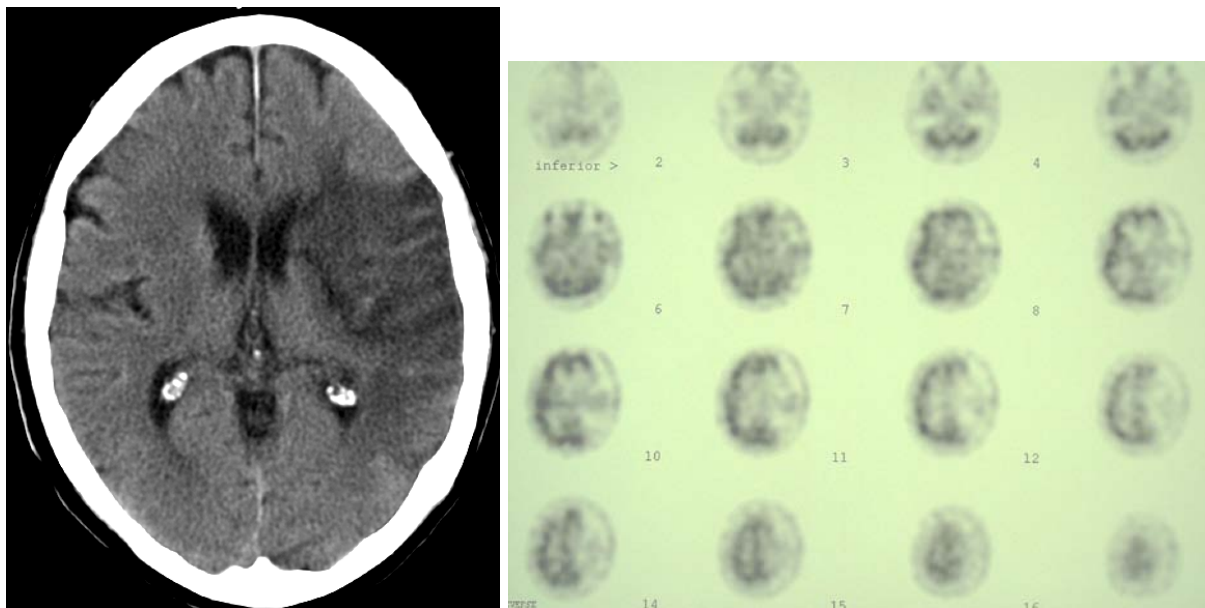


symptoms for three years with confusion, difficulty in language and counting and visual hallucinations.

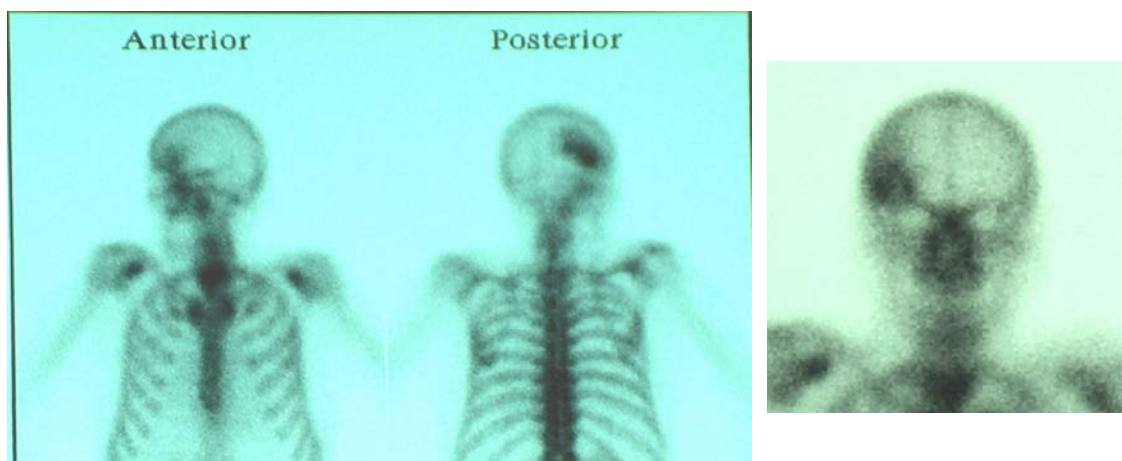
MID is diagnosed on MRI or CT.

e) Cerebral blood flow studies

These are also used to assess the extent of CVA damage, and also in complicated neurological cases pre-operatively and immediately post-operatively to indicate any surgical damage.

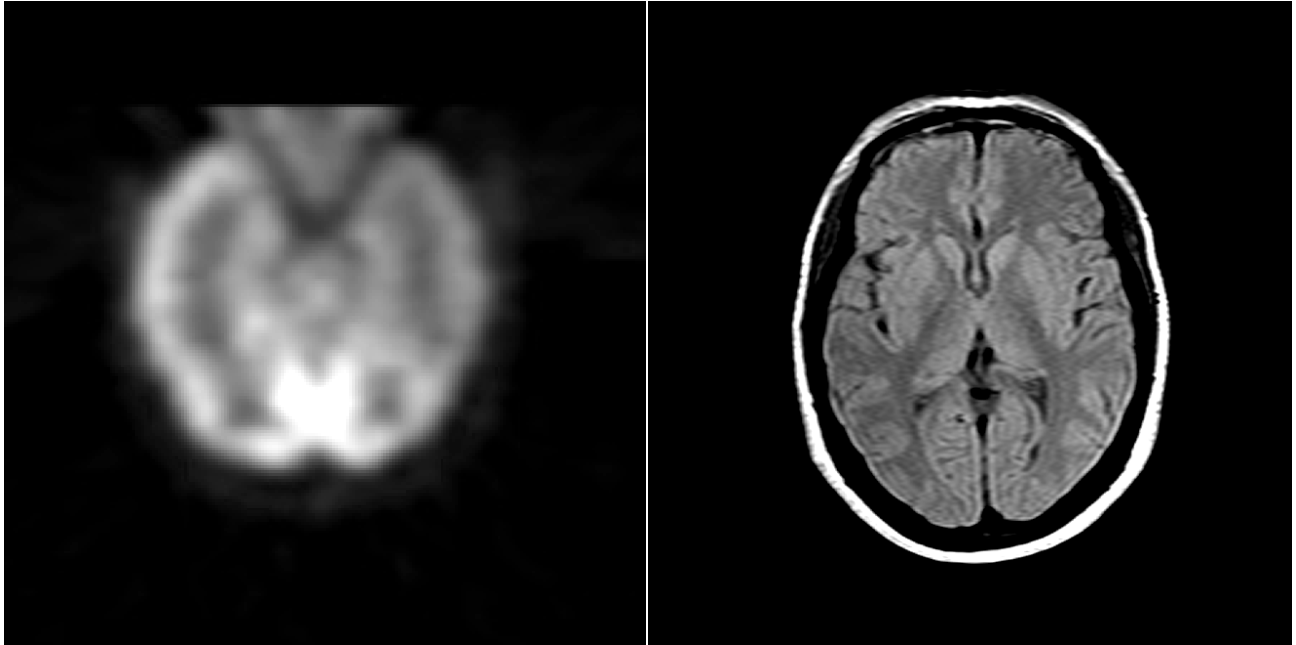


Interestingly a recent CVA may also show on a conventional bone scan, because the cerebral damage allows the bone agent to cross the blood/brain barrier, as shown below.



#### f) Epilepsy

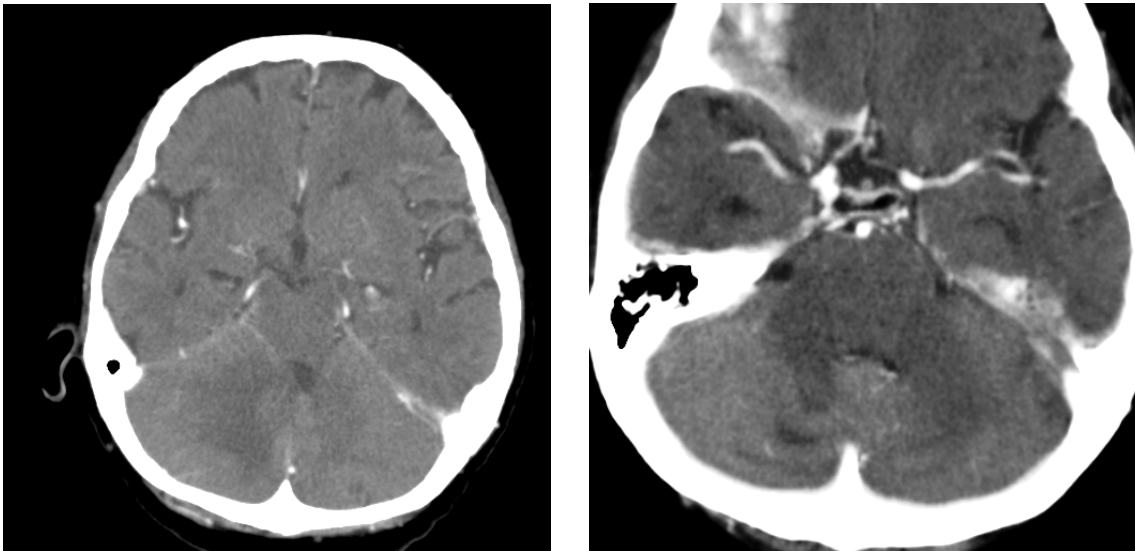
Epilepsy is a socially severe disorder, especially in children, and mapping the metabolically abnormal area using PET, and correlating it to the MRI, allows the neurosurgeon to plan operative procedures.



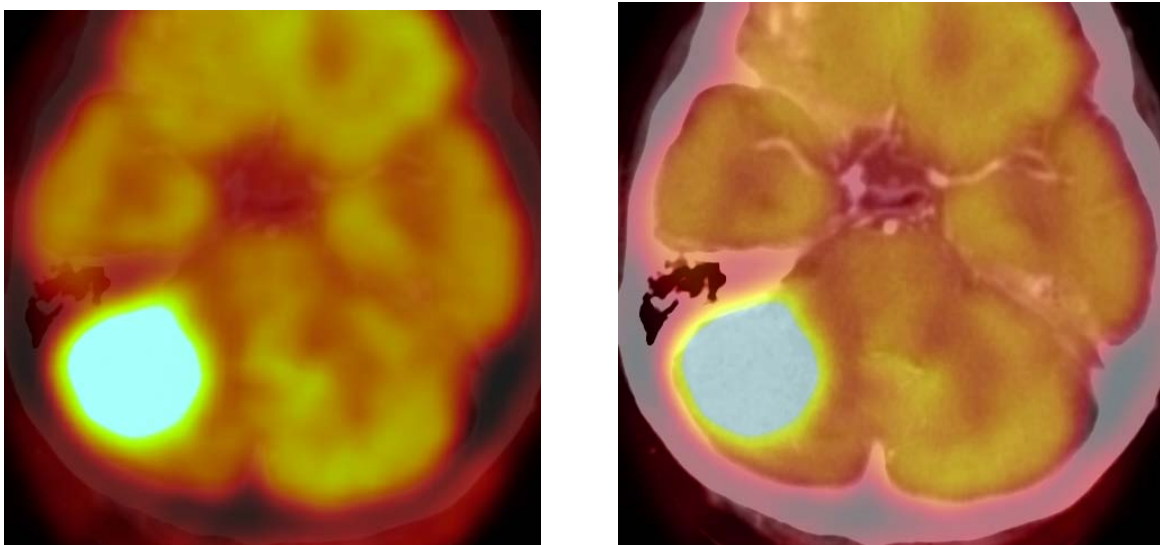
Courtesy of Dr Tom Nunan, Dept of Nuclear Medicine, St Thomas's Hospital, London

The FDG PET scan above shows reduced uptake in the left temporal lobe in a patient with intractable epilepsy. The scan is performed interictally, and the MRI may show a discrete focus or scar as the cause of the epilepsy. Ictal scanning will show markedly increased activity at the epileptic focus, and merging the image with the MRI helps the surgeon even more.

Occasionally, unexpected lesions are found when the patient is being investigated for unrelated symptoms.



This patient presented with migraine, and the CT suggested a diffuse lesion in the right cerebellum. A PET/CT scan was performed.



Courtesy of Dr Iva Kantorová, PET Centre, Na Homolce Hospital, Prague

This showed intense uptake in the cerebellum, due to a glioma.

### Diagnostic algorithms

Neck - voice problems

Laryngoscopy +/- biopsy

PET/CT

Neck - 'lumps'

Ultrasound

CT

PET/CT

Epiphora

Lacrimal drainage studies

Brain - tumours and inflammation

MRI

PET

Brain - movement disorders

FP-CIT scanning with  $^{123}\text{I}$  ioflupane

Brain - dementia

Cerebral blood flow studies with  $^{99\text{m}}\text{Tc}$  HMPAO in Alzheimers

FP-CIT scanning with  $^{123}\text{I}$  ioflupane in DLB

CT in MID

Brain - vascular

CT/MRI

Cerebral blood flow studies with  $^{99\text{m}}\text{Tc}$  HMPAO especially pre-operative

Brain - epilepsy

MRI

PET

## *LUNG AND CHEST*

### **Principles**

There are two main diseases that can be diagnosed by imaging the lungs using Nuclear Medicine techniques - pulmonary embolism and tumours. There are other problems that may be investigated, such as sarcoid, pulmonary hypertension, regional lung function preoperatively and ciliary clearance, but these are much less frequently performed.

### **Pulmonary embolism**

#### **Indications**

Pulmonary embolism arises when a blood clot obstructs one or several of the major pulmonary arteries. The symptoms are usually shortness of breath, pleuritic chest pain and haemoptysis, and there may well be underlying predisposing factors such as patient immobility, recent surgery, underlying malignancy or use of the oral contraceptive pill.

#### **How to perform the tests**

The study is performed as soon as symptoms arise, by injecting  $^{99m}\text{Tc}$  labelled microspheres or MAA with the patient supine. The administered dose is 80MBq. These particles are about 40 $\mu\text{m}$  diameter and lodge in the peripheral pulmonary capillaries. They are then imaged, and give a picture of the blood distribution within the lungs. If there is a block in the pulmonary arterial tree, then there will be a defect in the image.

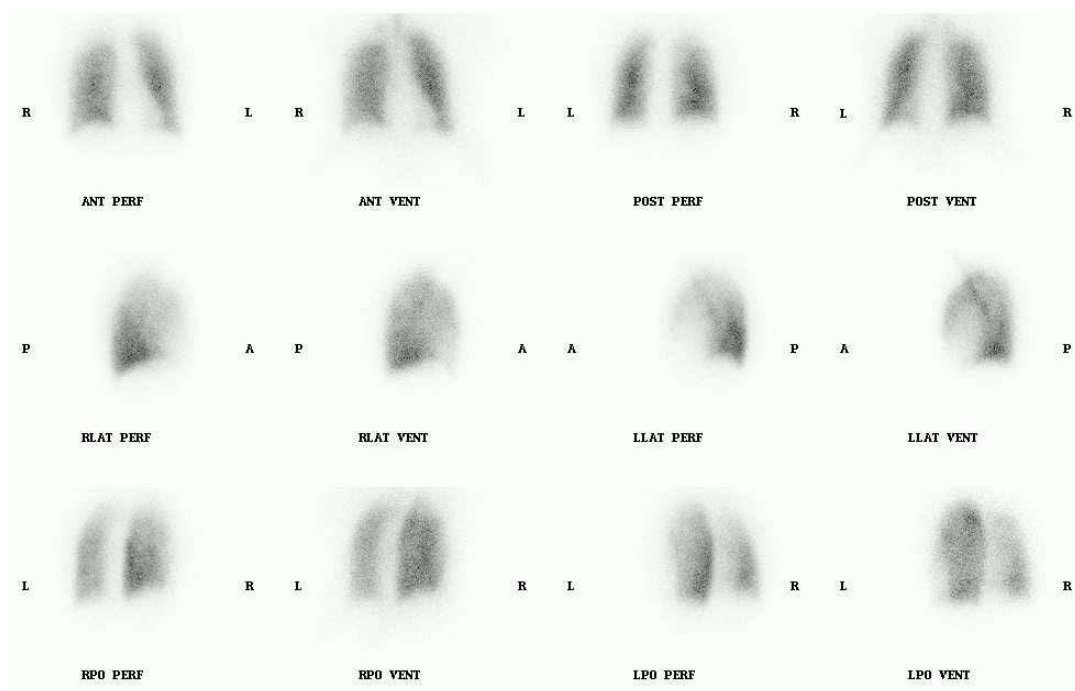
At the same time, the lungs are ventilated with a radioactive gas or aerosol, and images also obtained. They are compared with the perfusion images, and to make the diagnosis of pulmonary embolism, there must be a perfusion defect with no ventilation defect.

The study may well become inaccurate if the patient is imaged after, say, 10 days as the clot will retract, allowing the microspheres to pass, giving a false negative result.

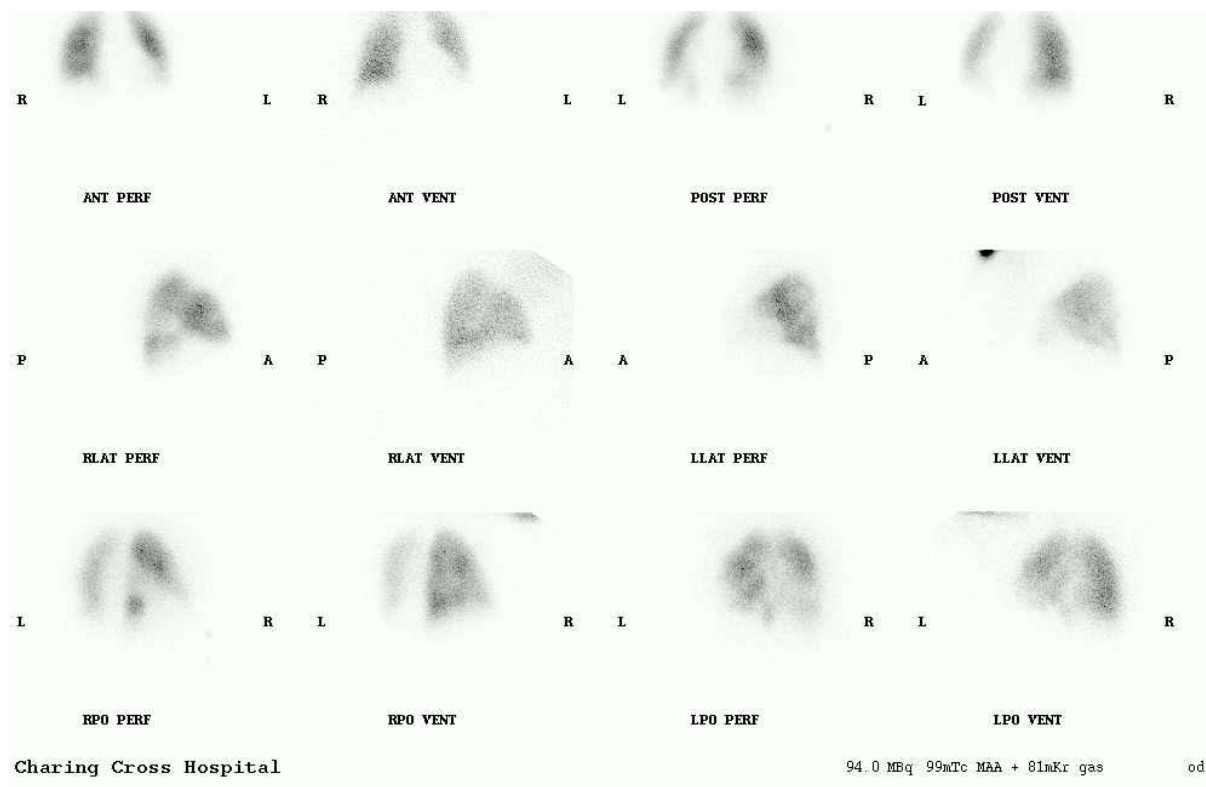
The ventilation is best performed using  $^{81m}\text{Kr}$  gas, which has a  $\gamma$  energy of 190KeV, and so can be imaged coincidentally with the Tc which has a  $\gamma$  energy of 140KeV. Kr has a  $t_{1/2}$  of 13 secs, so there is no danger of contamination either of the camera or the room, and no radiation risk to the staff. There are other isotopes that can be used for ventilation imaging. In the US,  $^{133}\text{Xe}$  is used, but this has a  $t_{1/2}$  of 5.25 hours and so has significant contamination problems. It is also possible to

produce a Tc-labelled gas (Technegas®) which can be used, but there are logistical problems, and there is also the problem of using the same isotope in two different forms to image the patient at the same time. The particles of the gas can also be sucked into the cooling system of the gamma camera, thus contaminating it and rendering it useless for about 24 hours. However, technegas is extremely good at measuring ciliary clearance.

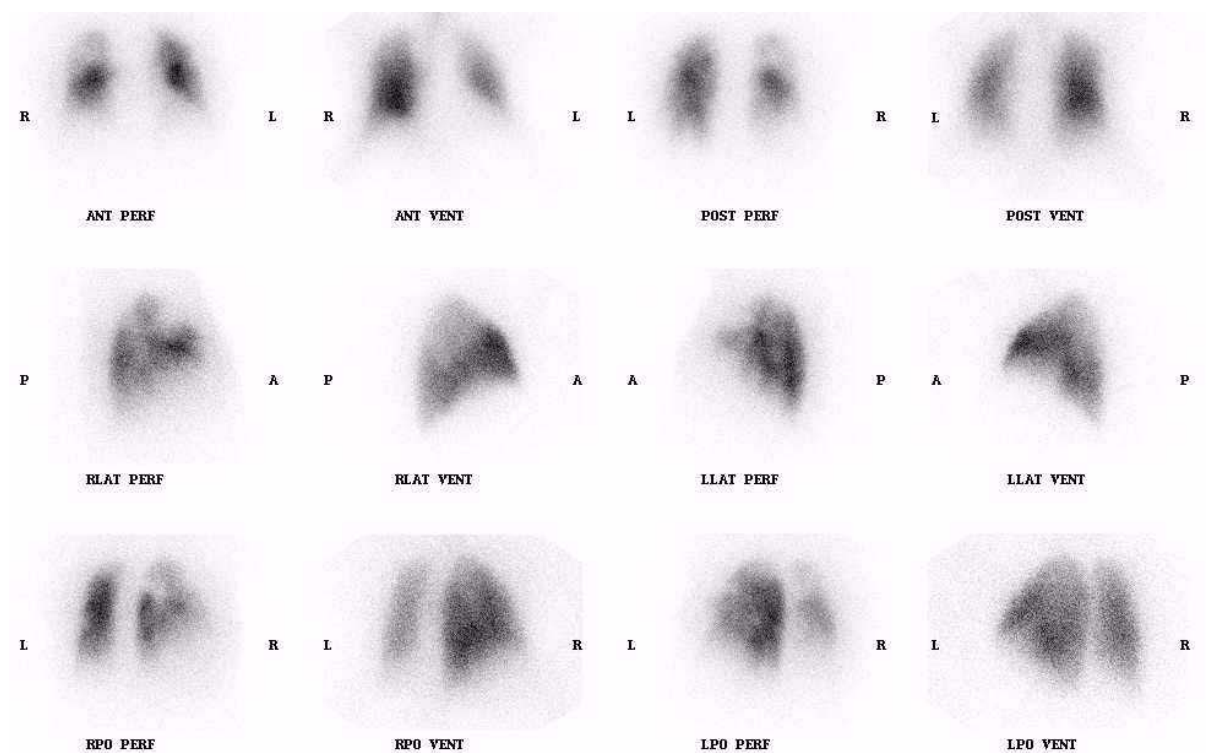
As well as planar imaging, as shown below, it is also possible to image the lungs with SPECT, and this may show up smaller pulmonary emboli more clearly.



These images show the normal appearances of the pulmonary perfusion, and also the ventilation. There are no unmatched defects.

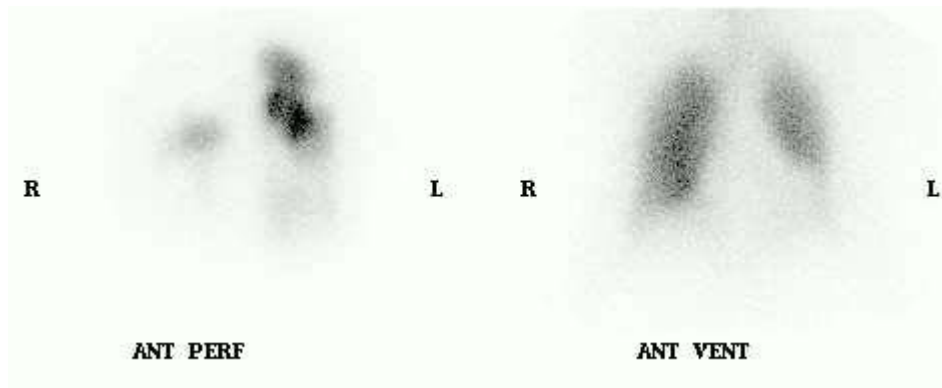


These images show a large perfusion defect at the right base, not matched on the ventilation scan, typical of a pulmonary embolus. The heart is also enlarged.



These images show multiple pulmonary emboli in a patient with known temporal arteritis.





This image shows even more extensive pulmonary emboli.

### Contraindications

Pregnancy is not a contraindication, as the risk of an untreated pulmonary embolism exceeds the radiation risk to the foetus, and all the injected microspheres are trapped in the lungs.

Do not inject the microspheres into an existing intravenous line, as there is always some blood clot at the end of the line, and the microspheres will adhere to this clot, and then break off, leading to clumping in the lungs.

Should the patient have a right to left shunt, care must be taken and a smaller number of microspheres injected, to minimise systemic distribution.

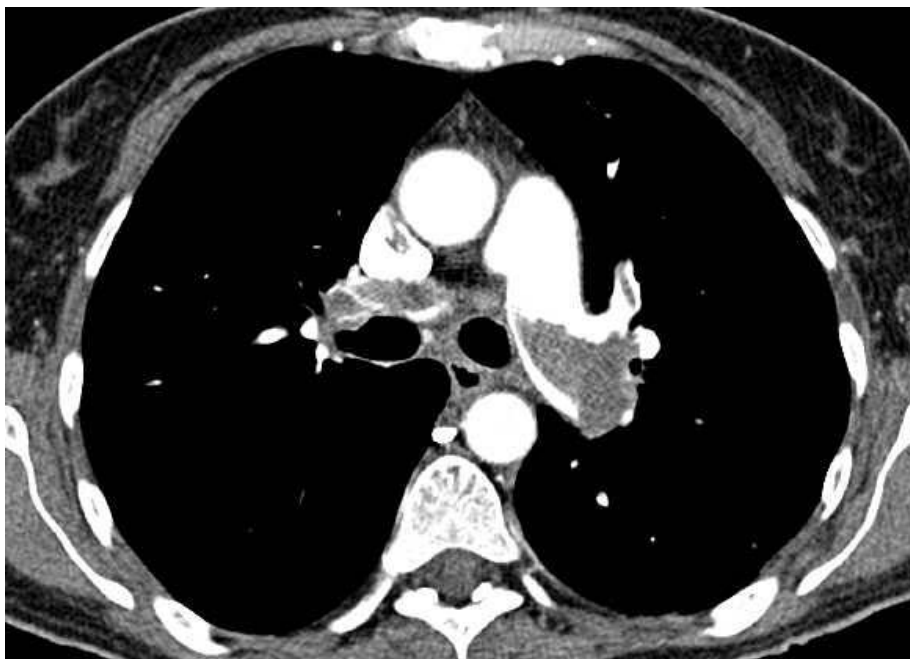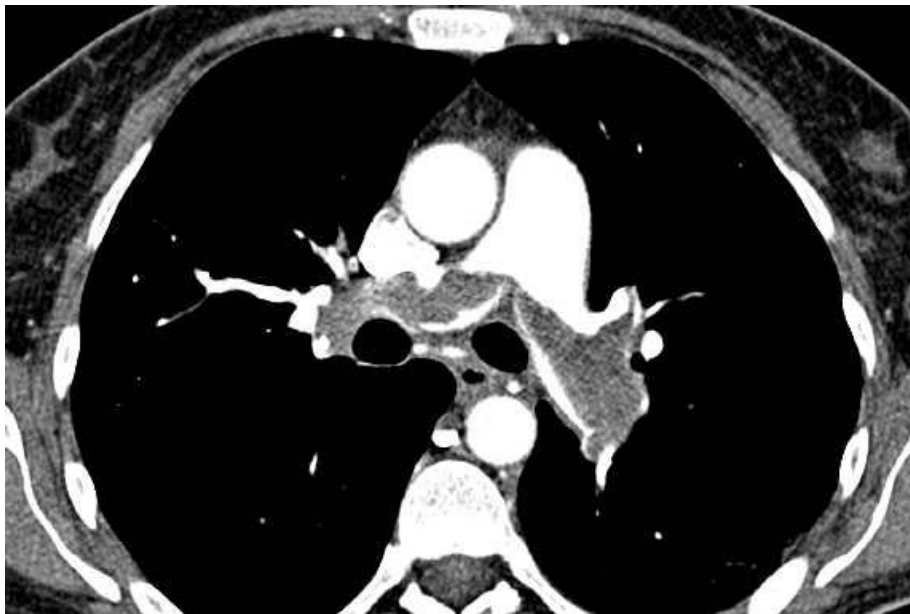


This image shows the head of a patient with a right to left shunt after a lung scan.

## Patient preparation

None

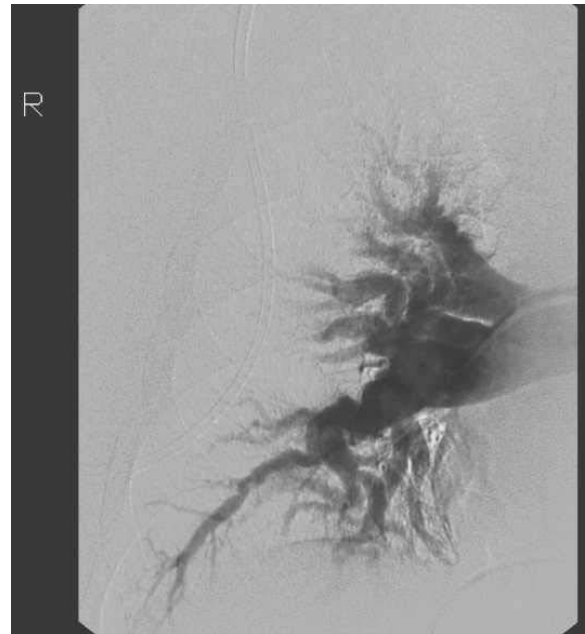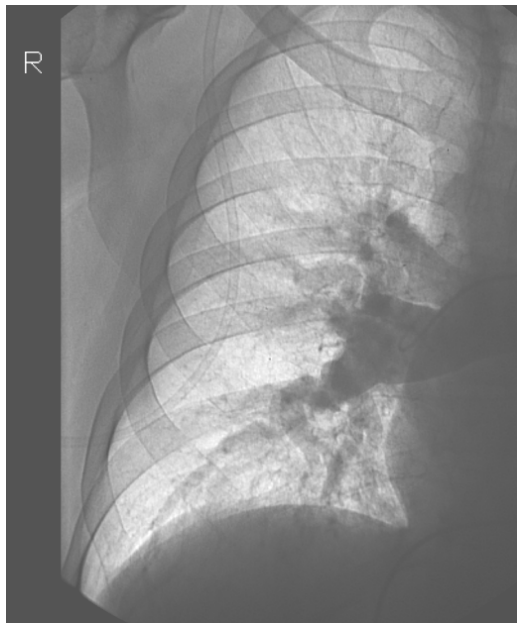
However, there are problems with Nuclear Medicine imaging of pulmonary emboli, the main one being that the isotopes have a limited life and availability, and so cannot be used out of normal radiopharmacy working hours. For this reason, CT pulmonary angiography has largely taken over from lung scanning as it can be performed at any time, shows the important pulmonary emboli and also gives extra information about the lungs and the chest.



These two images clearly show the large central emboli.

The 'gold standard' of investigation is the pulmonary angiogram, which is done as a subtraction study, but is rarely performed now.

The images below show a typical right lung study. The left lung would have to be studied separately, and the radiation dose from these studies is significantly more than from a lung scan or a CTPA.



## Lung tumours

Lung tumours are either primary lung cancers or secondaries from a large number of primaries that metastasise to the lung.

### Indications

Primaries are best imaged and staged with PET/CT or PET, which are the chosen methods of investigating solitary pulmonary nodules. The lesion is usually first detected on a plain chest x-ray but this is not very accurate in staging. CT may be performed separately to aid biopsy.

### How to perform the tests

PET/CT is performed using 400 MBq  $^{18}\text{F}$ -FDG injected with the patient lying quiet and still in a darkened room. Imaging is commenced 1 hour after injection.

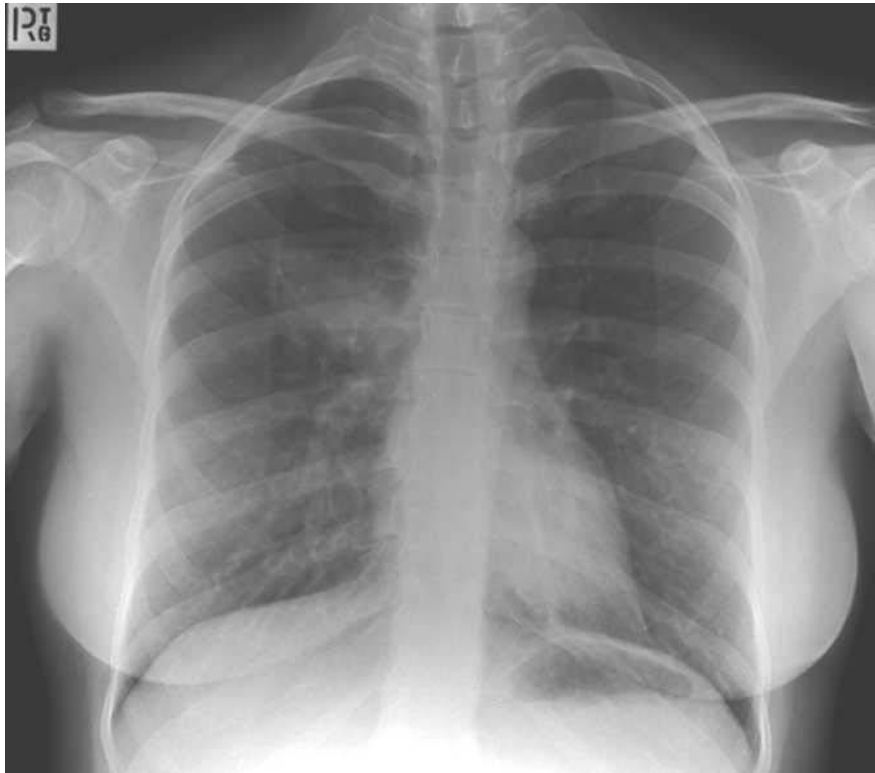
Lung cancers can also be imaged with somatostatin analogs, such as depreotide, which can be labelled with 600 MBq  $^{99\text{m}}\text{Tc}$ .

### **Patient preparation**

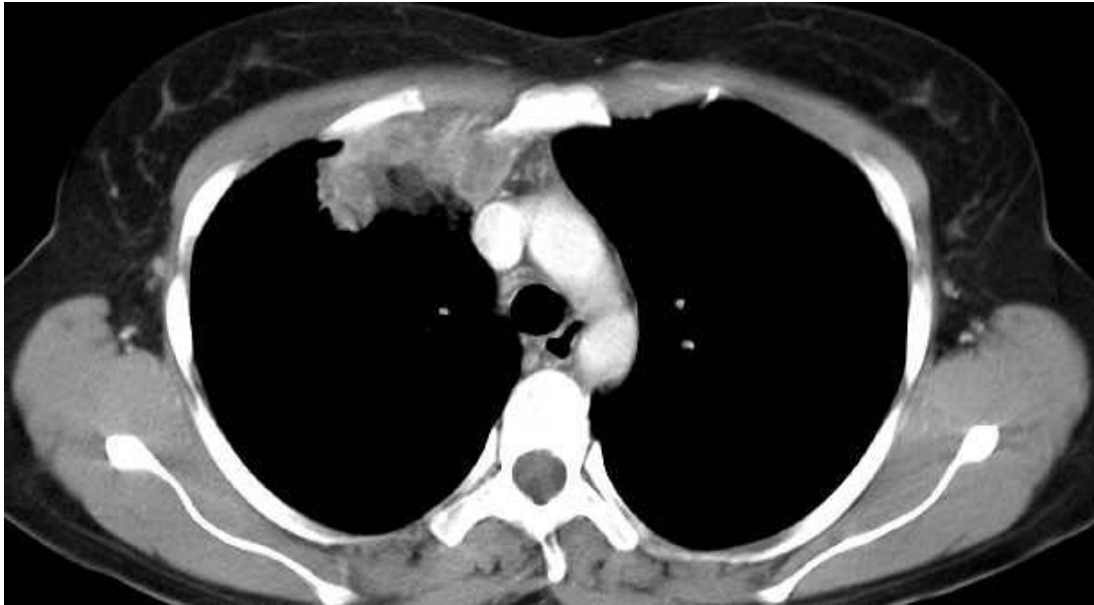Nil by mouth for 6 hours prior to a PET/CT scan, otherwise none.

### **Examples**

Primary lung lesions.

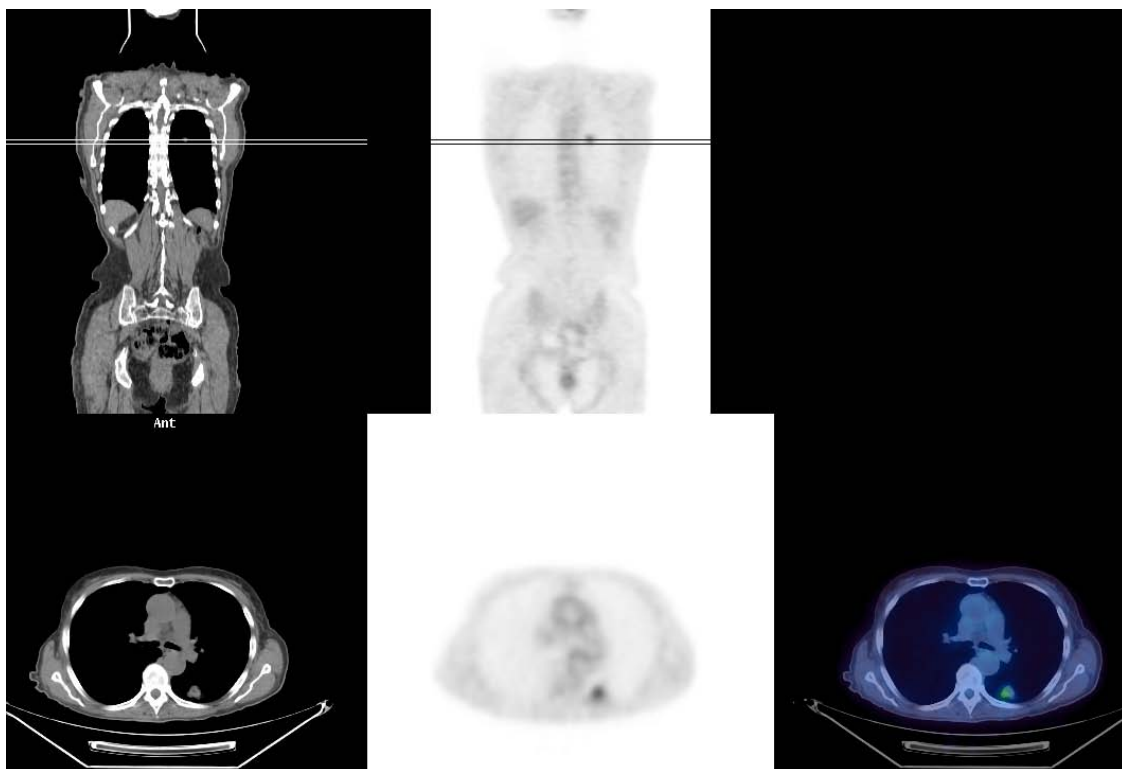


There is a soft lesion arising from the right hilum, but the x-ray is otherwise not very helpful. This lesion could easily be missed, especially if smaller.



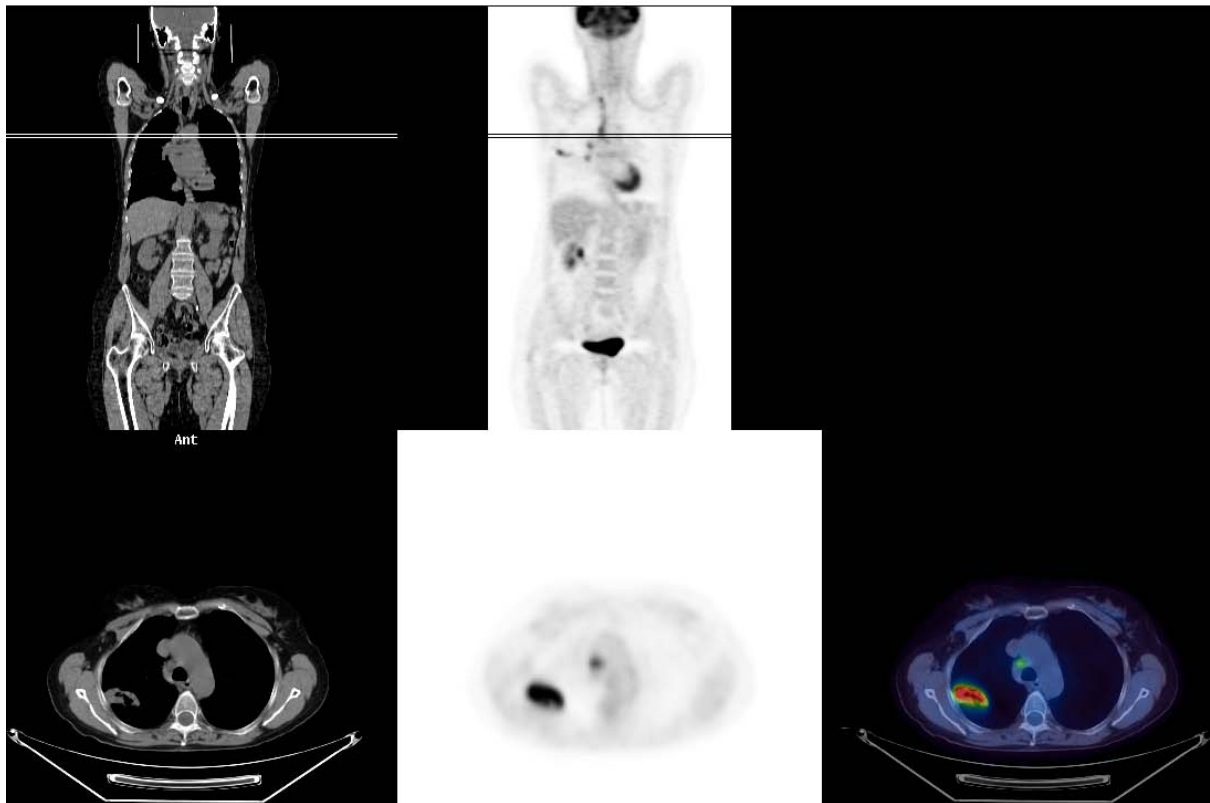
The CT clearly shows the extent of the lesion, and also indicates that it is well-placed for percutaneous biopsy. This is needed to obtain tissue diagnosis.

PET/CT not only identifies the lesion anatomically, but also shows the extent of metabolic activity.



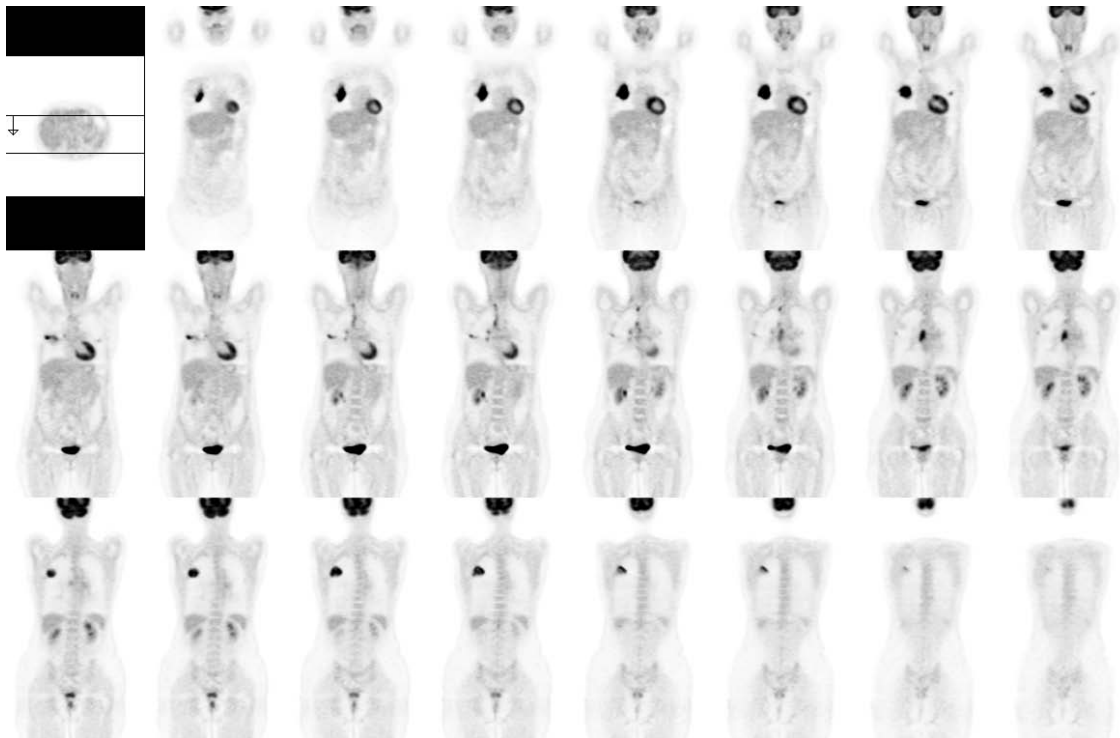
Courtesy of Dr Teresa Szyszko, Dept of Nuclear Medicine, St Thomas's Hospital, London

The image above shows a well-defined lesion posteriorly on the left, with no evidence of metastatic spread, and so is operable.



Courtesy of Dr Teresa Szyszko, Dept of Nuclear Medicine, St Thomas's Hospital, London

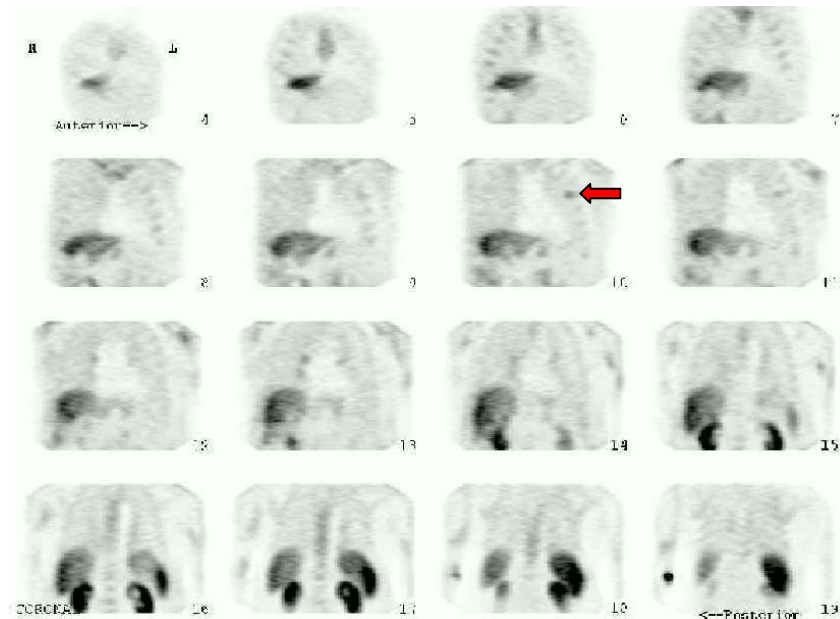
This image shows that the lesion lying laterally on the right is invading the chest wall and also has metastatic spread to the hilum and right paratracheal nodes, making the lesion inoperable.



This overview image confirms that the lesion is inoperable.

The importance of accurate diagnosis with PET/CT or PET is that it may alter the staging of the cancer, and thus the treatment. Obviously, there are huge implications for the patient in this, in that inappropriate operations may be avoided, and the patient can immediately be started on chemotherapy or palliative care. There are significant cost implications and PET/CT prevents waste of resources.

Somatostatin receptor imaging has the advantage of using  $^{99m}\text{Tc}$  as the isotope, and so can be performed at any centre with a SPECT gamma camera.

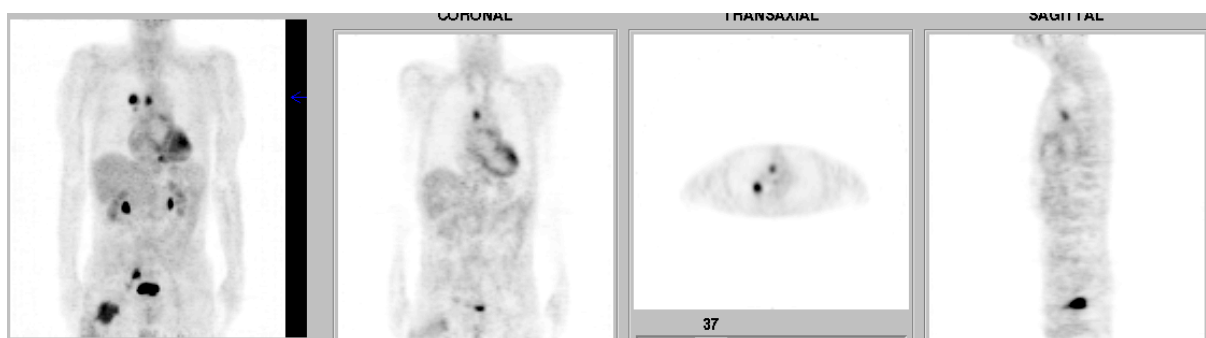


These SPECT images show the lesion in the left mid-zone (arrow), but the images are not as good as PET.

### Secondary malignant lung disease

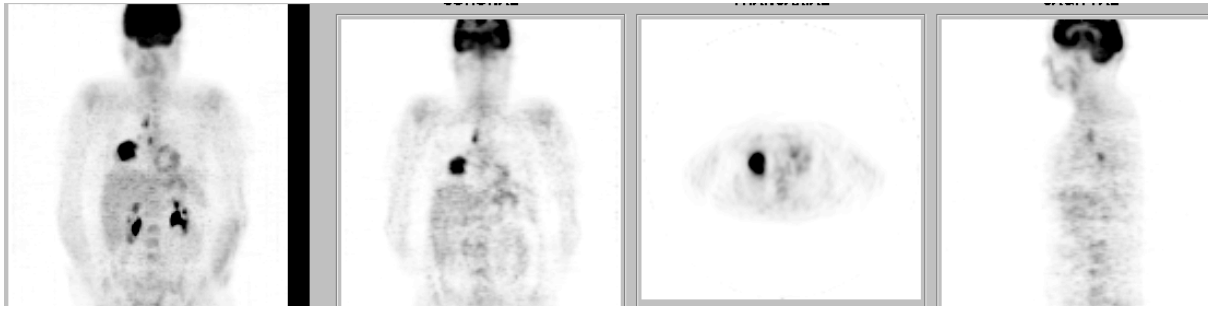
This is usually found on routine chest x-ray or CT where the primary is known elsewhere in the body, such as colorectal disease.

PET/CT may also show metastatic disease where present.



This PET scan clearly shows the right lung cancer with metastases at the right hilum and also in the right upper femur.

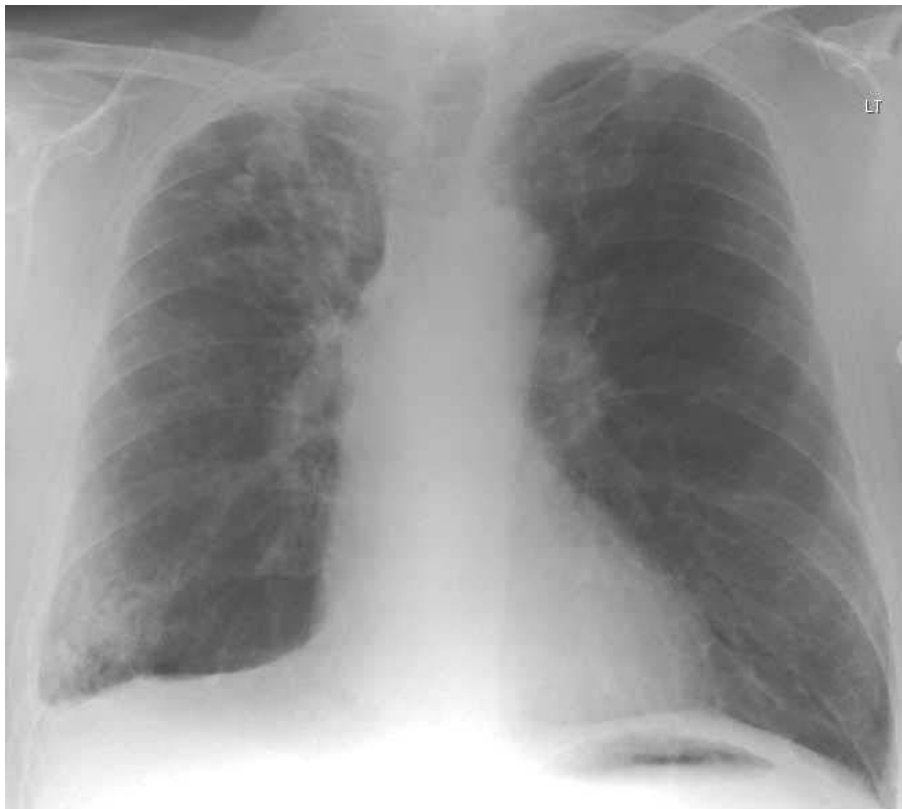



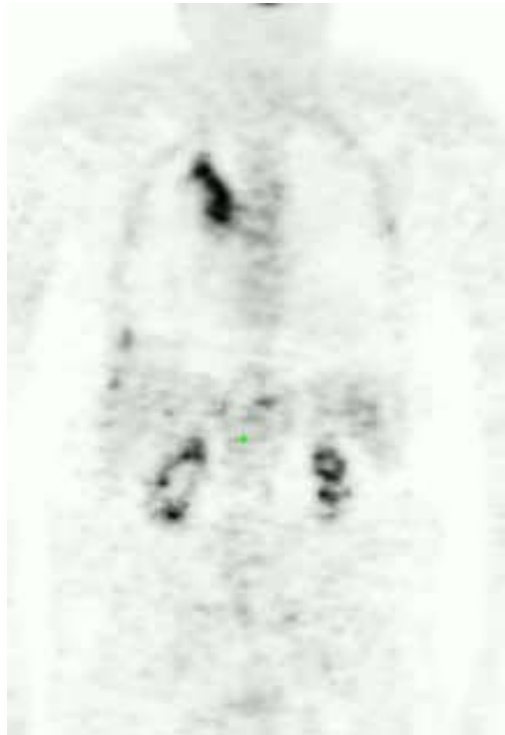
Again, a lung cancer with metastases in the hilum and subcarinal nodes.

### Other lung disease

- a) Infection is usually diagnosed on conventional x-ray, but can also be shown rather well on PET.

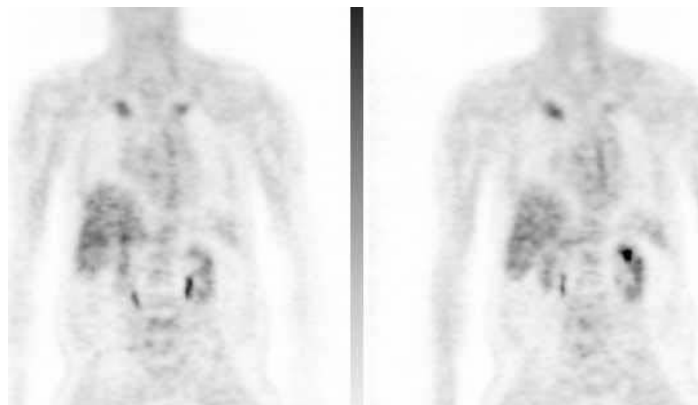
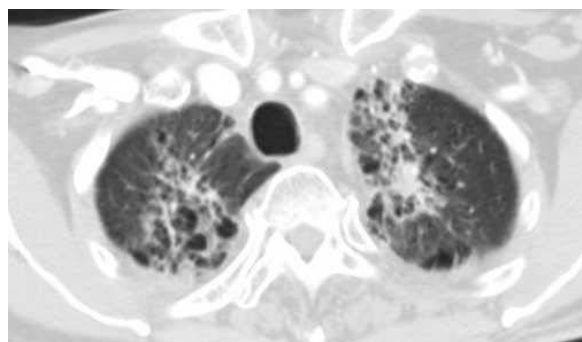
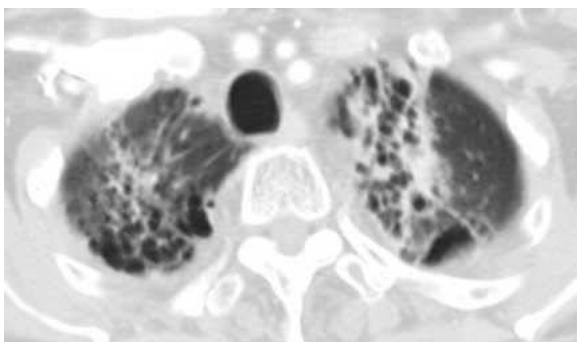


This x-ray shows soft shadowing in the right apex, typical of TB, but activity of disease cannot be ascertained. For this reason, a PET scan is helpful.

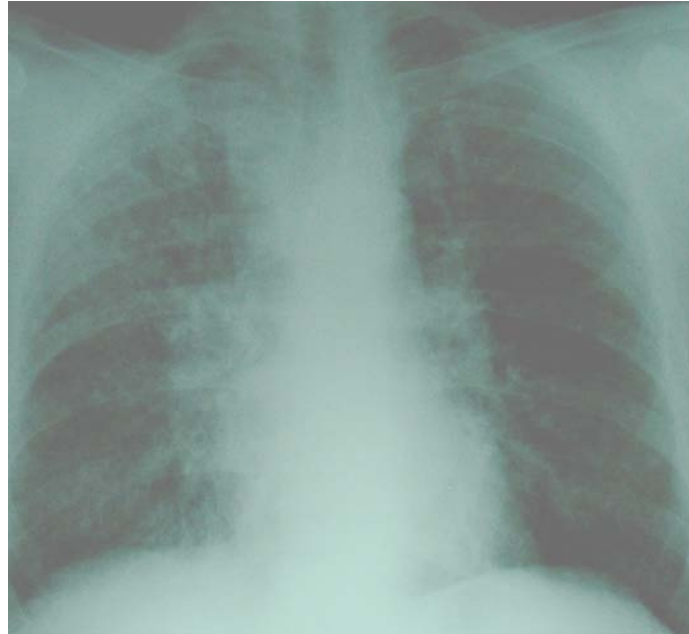

The PET image clearly shows the increased activity due to infection.

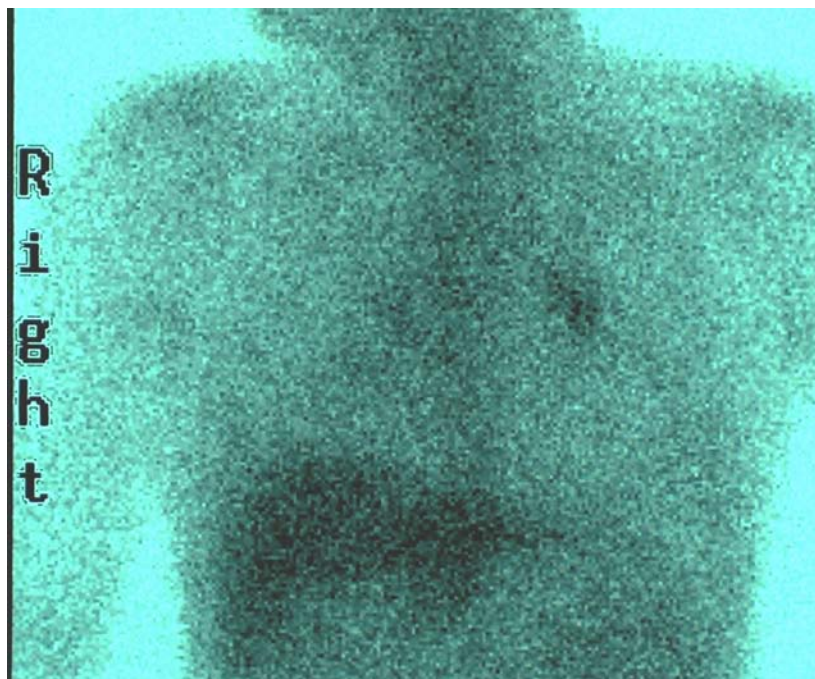
- b) Bronchiectasis (here, on CT) is a destructive lesion of the lungs which is associated with infection, and it is necessary to delineate the extent of the disease prior to considering surgery. For this, PET is very helpful.



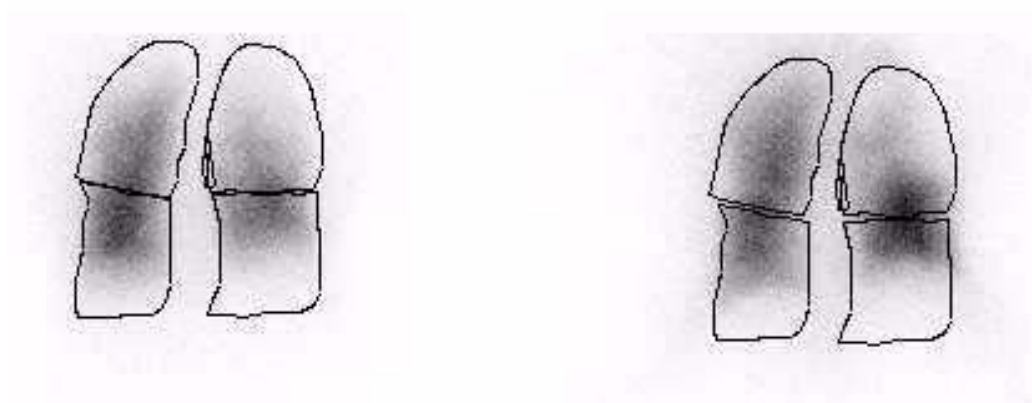
- c) Sarcoid, using  $^{67}\text{Ga}$  or  $^{18}\text{F}$ -FDG PET. The administered dose of  $^{67}\text{Ga}$  citrate is 150 MBq. The images are obtained 48 and 72 hours after administration, as there is significant bowel activity early on. The use of PET/CT is becoming more common in benign lung disease such as sarcoid.



The chest x-ray shows obvious bilateral hilar lymphadenopathy, but the image using  $^{67}\text{Ga}$  shows obvious uptake in the enlarged left hilar nodes only, indicating where the disease is active.



- d) Regional lung function is sometimes requested prior to lobectomy, and is calculated from a normal perfusion scan using  $^{99m}\text{Tc}$  microspheres.



LUNG ANALYSIS	
Left Total Counts :	238771.00000
Right Total Counts:	189071.00000
SEGMENTAL	
LUL (%)	: 50.180700
LLL (%)	: 49.819300
RUL (%)	: 50.236700
RLL (%)	: 49.763300
-----	
TOTAL	
Left Lung (%)	: 55.808200
Right Lung (%)	: 44.191800

### Diagnostic algorithms

#### Pulmonary embolism

- CTPA
- Conventional Nuclear Medicine lung scanning

#### Solitary pulmonary nodule

- PET/CT
- Biopsy

#### Metastatic lung disease

- Plain chest x-ray
- CT
- PET/CT

#### Infections

- Plain x-ray
- CT, including HDCT
- Appropriate Nuclear Medicine investigation

#### Regional lung function

- Perfusion lung scan

## *PAEDIATRIC IMAGING*

### **Principles**

Specialist paediatric imaging is used in certain specific paediatric problems, and is best performed in paediatric centres, where there is the appropriate expertise. This is particularly so for paediatric PET/CT. Current thinking is that there is no need for sedation of the patients.

### **Indications**

The main Nuclear Medicine imaging is renal, followed by skeletal and tumour imaging. Fuller indications are given below, under each heading.

Other imaging can be performed, as in adult practice, but of course the administered dose is reduced to allow for the smaller size of the patient.

The Paediatric Task group of the EANM has prepared a paper outlining the dosage schedule for different aged patients.

### **How to do it**

Skill is needed in cannulating veins in children, especially in babies and toddlers, and it is helpful to use a local anaesthetic cream at the injection site, and to inject the patient in a room away from the Nuclear Medicine equipment if possible.

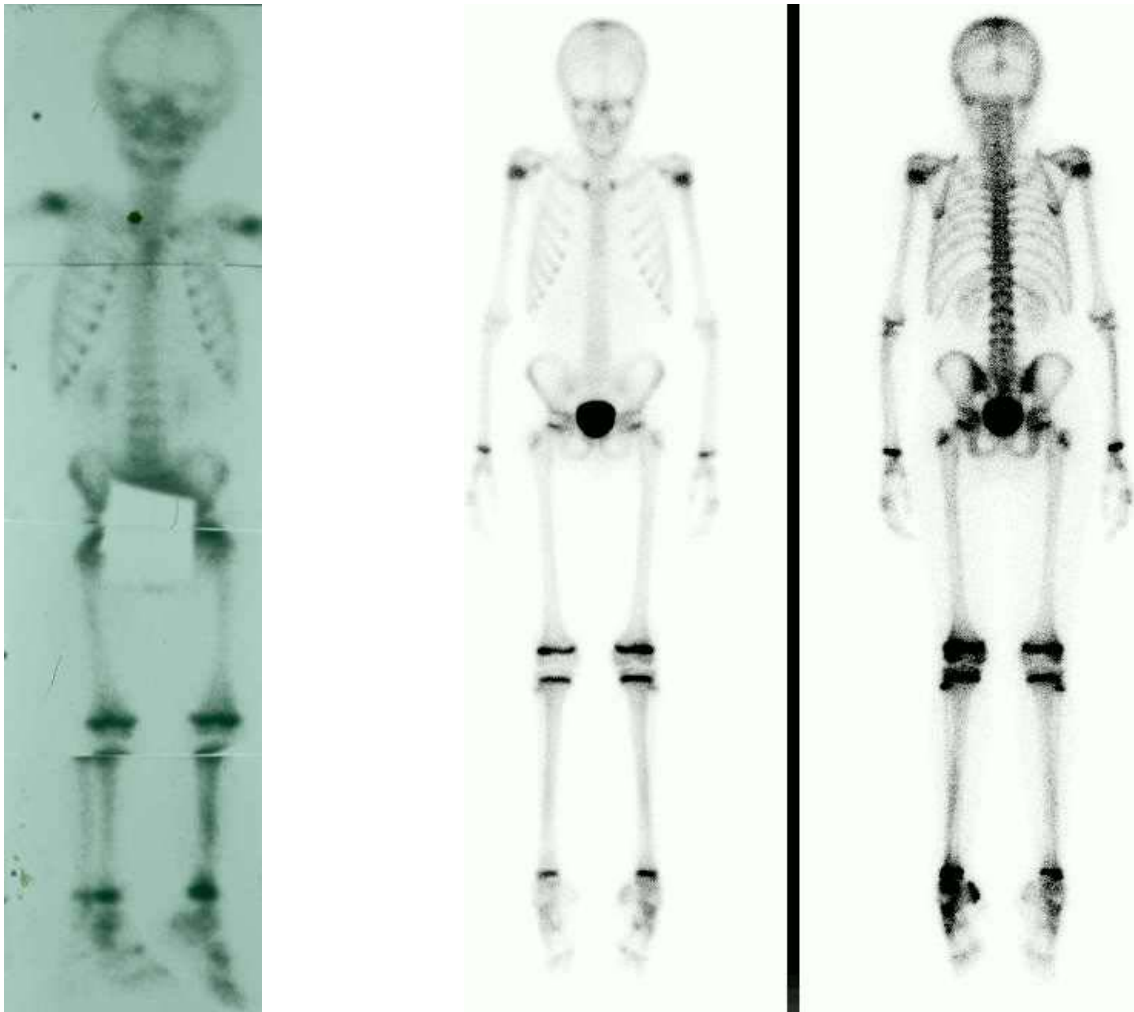
### **Contraindications**

None.

### **Examples**

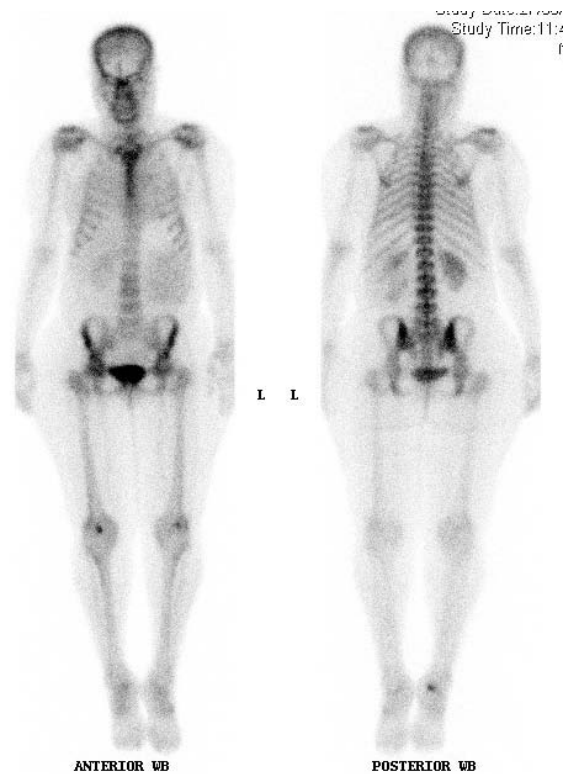
Renal imaging in paediatrics is largely DMSA static imaging to assess scarring, and dynamic scanning with MAG3 to assess obstruction. Radionuclide cystography may be used to assess reflux. These are covered in the following section on Renal Imaging.

The paediatric skeleton is significantly different from the adult.



The image on the left is a small child, aged 3, and that on the right a child of about 12. The immediate obvious difference from an adult skeleton is the epiphyseal plates, which are metabolically extremely active, being the growing plates for the bone. Note also that the cranium is proportionately much larger than the face, and the cranium grows at a much slower rate, and reflects brain growth.





The differences from the adult skeleton are easily seen.

In general, the indications for paediatric bone scanning are:

Infection or Inflammation

Bone Tumours

Aseptic Necrosis

Traumatic Bone Disease

Sudeck's atrophy

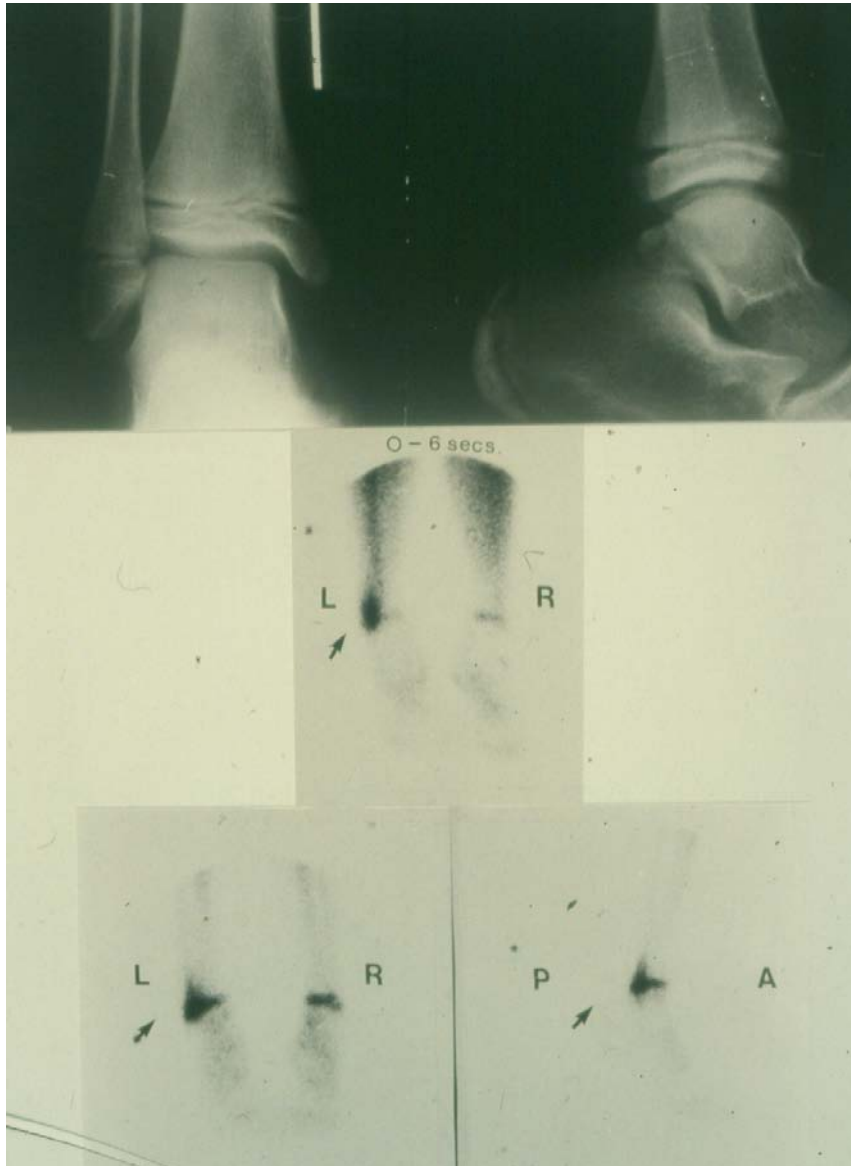
Bone Scintigraphy Guided Surgery

Bone Dysplasia

Other Clinical Situations in Paediatrics

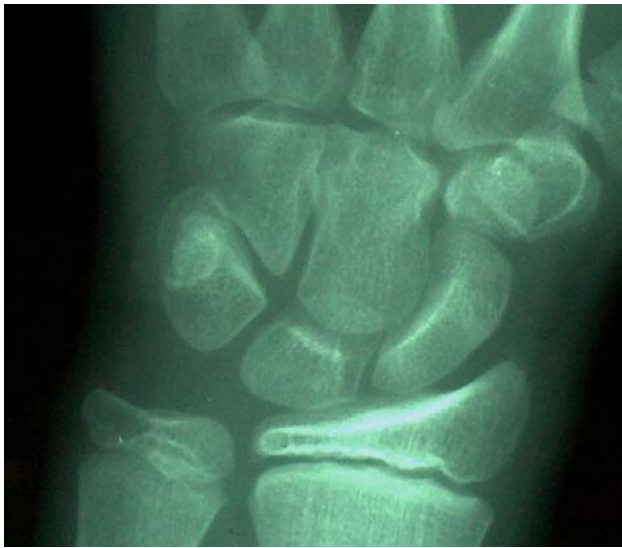- pain possibly due to bone pathology
- the child with a limp or backache
- child refusing to stand or to use one limb
- fever of unknown origin
- NAI (non-accidental injury)

although in modern practice most use is in bone infection, trauma and obscure skeletal pain, and possibly in NAI, since MRI provides far better information in the other cases, and also does not involve ionising radiation.

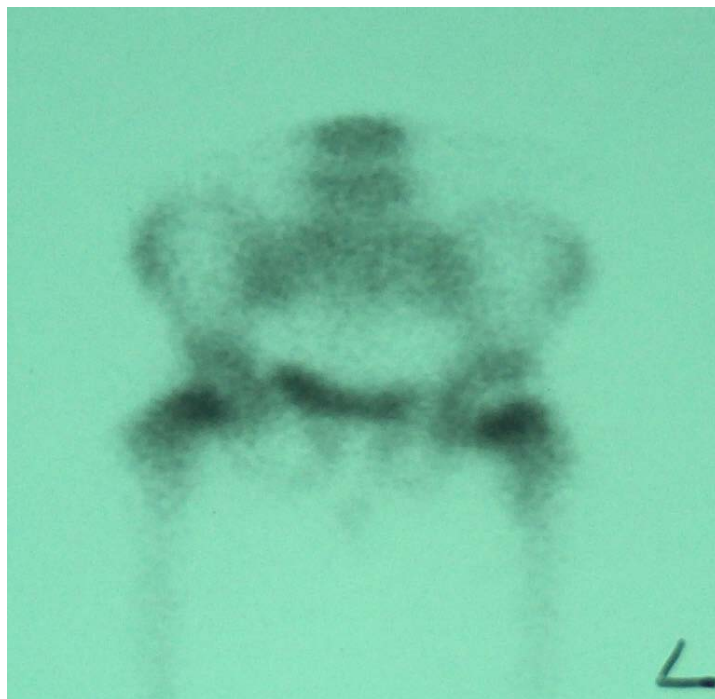


These images of a 5 year old show normal x-rays but intense activity in the left lateral malleolus in all phases of the bone scan, due to osteomyelitis.

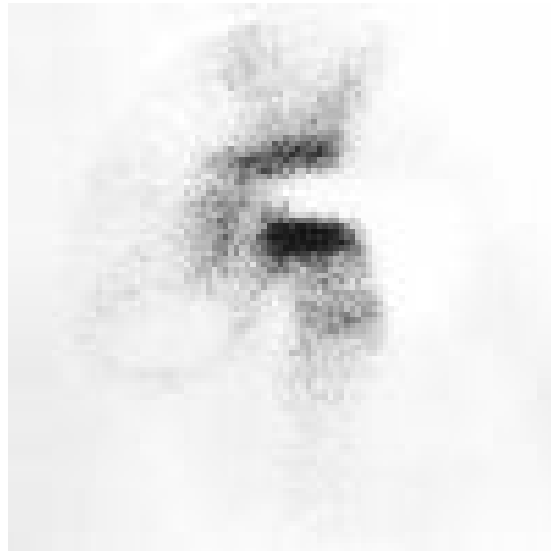The images below of a child's wrist show normal x-rays but local increased uptake in the scaphoid, due to a fracture following a fall.



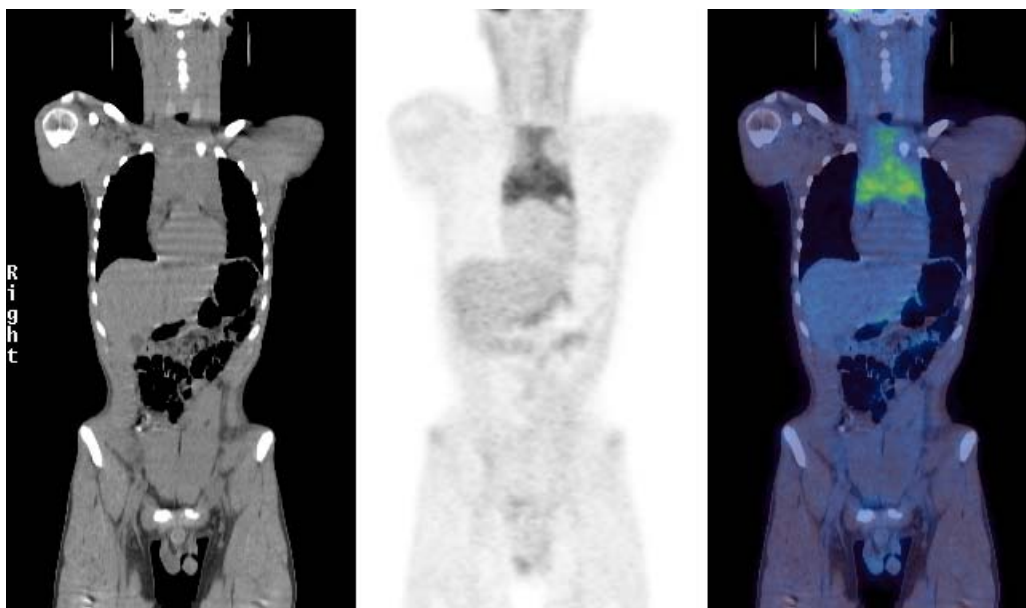
Vascular bone problems such as Perthe's disease, are well shown, but may be better imaged with MRI.

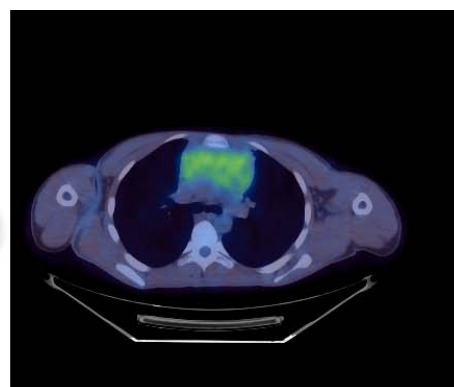
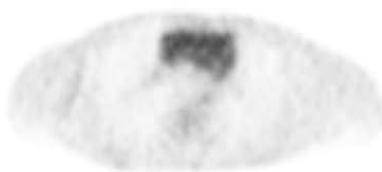
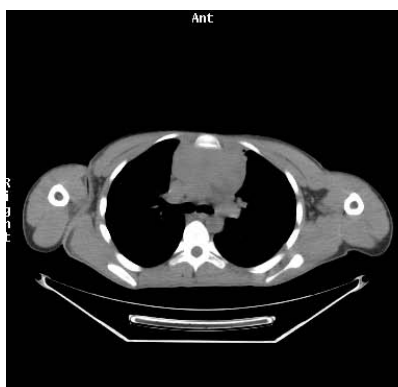
More detail may be obtained using a pinhole collimator over the affected hip, as below.



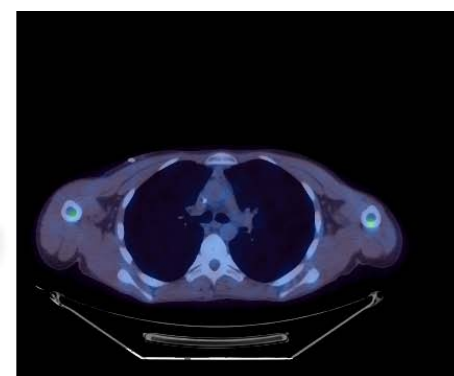
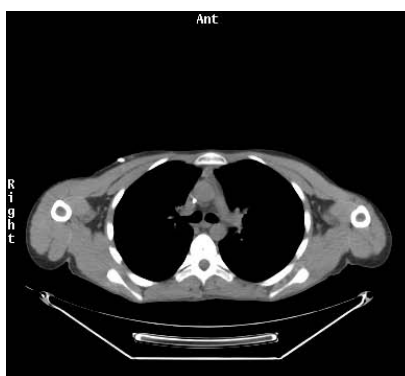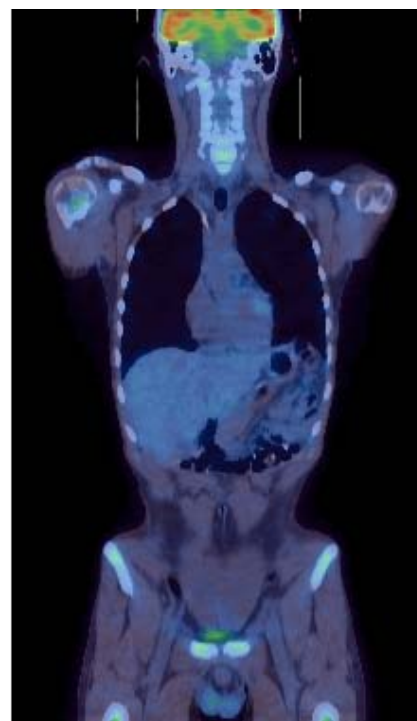
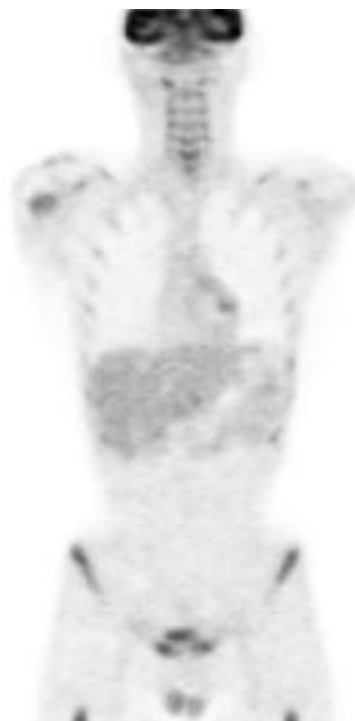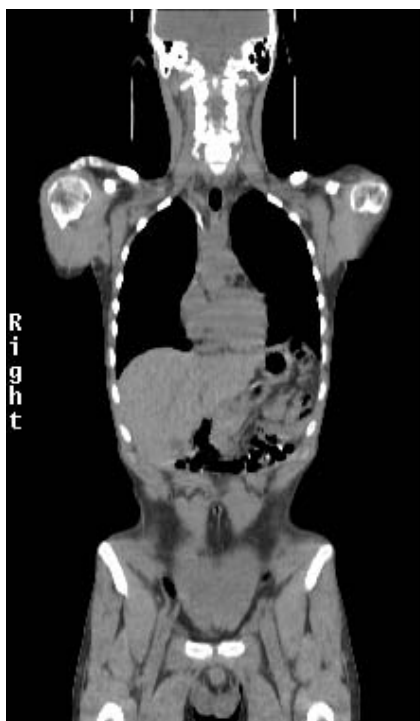Tumour imaging in paediatric practice now uses PET/CT. The images are essentially the same as those obtained in adults, but special precautions need to be taken with children, such as using a smaller administered dose.





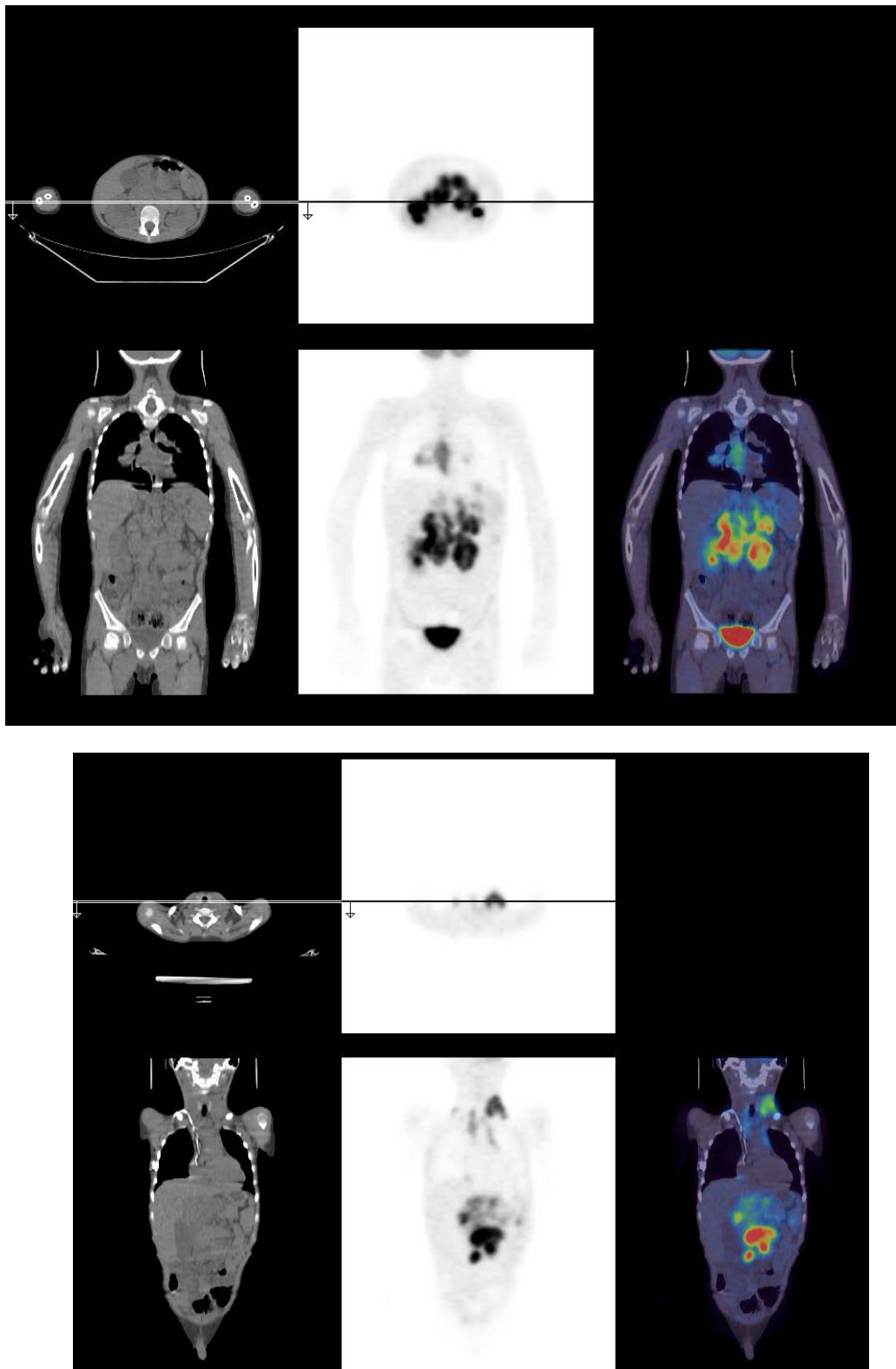
Courtesy of Dr Sally Barrington, Dept of Nuclear Medicine, St Thomas's Hospital, London

These images show a teenager with Hodgkin's Disease before (above) and after (below) 6 courses of chemotherapy.



Courtesy of Dr Sally Barrington, Dept of Nuclear Medicine, St Thomas's Hospital, London

The images below show a 6 year-old with stage 3b Hodgkin's Disease, again before and after chemotherapy.

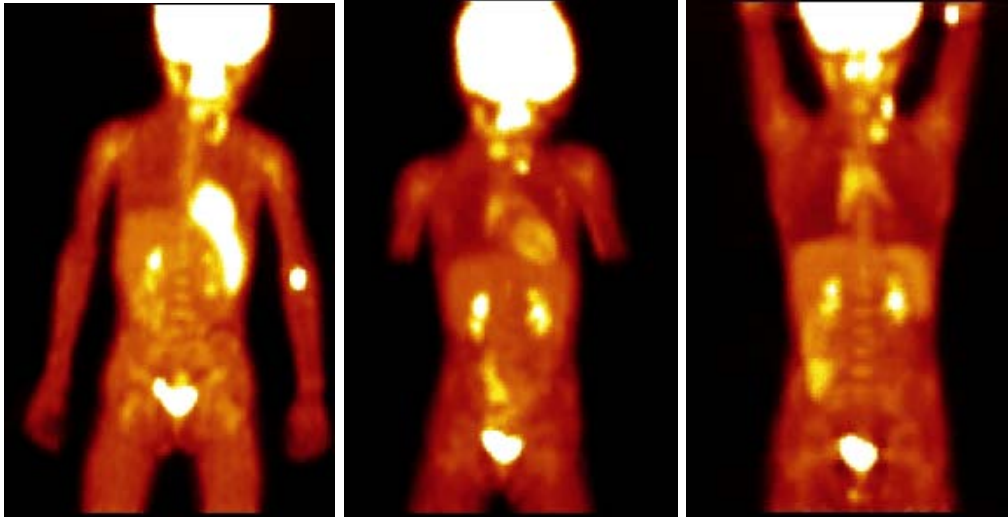


Images courtesy of Dr Sally Barrington, Dept of Nuclear Medicine, St Thomas's Hospital, London

A major use of PET/CT is in assessment of recurrence. A PET/CT scan is performed at the time of diagnosis and after 2 or 3 courses of chemotherapy. If there is

improvement, then the chemotherapy regime is continued, but if not, then changes can be made to the therapy.

These three images, below, of a 4 year-old girl, show relapse of her Hodgkin's Disease over a period of a year after chemotherapy and radiotherapy.



Images courtesy of Professor Otakar Bělohávek, PET Centre, Na Homolce Hospital, Prague

This allowed re-planning of her therapy.

### **Diagnostic algorithms**

#### **Renal - UTI**

- Microbiology of urine
- DMSA
- US

#### **Benign bone disease**

- Conventional Nuclear Medicine bone imaging for bone infection, trauma and obscure skeletal pain including NAI
- MRI for everything else

#### **Malignant bone disease**

- MRI
- PET/CT

#### **Tumour**

- PET/CT

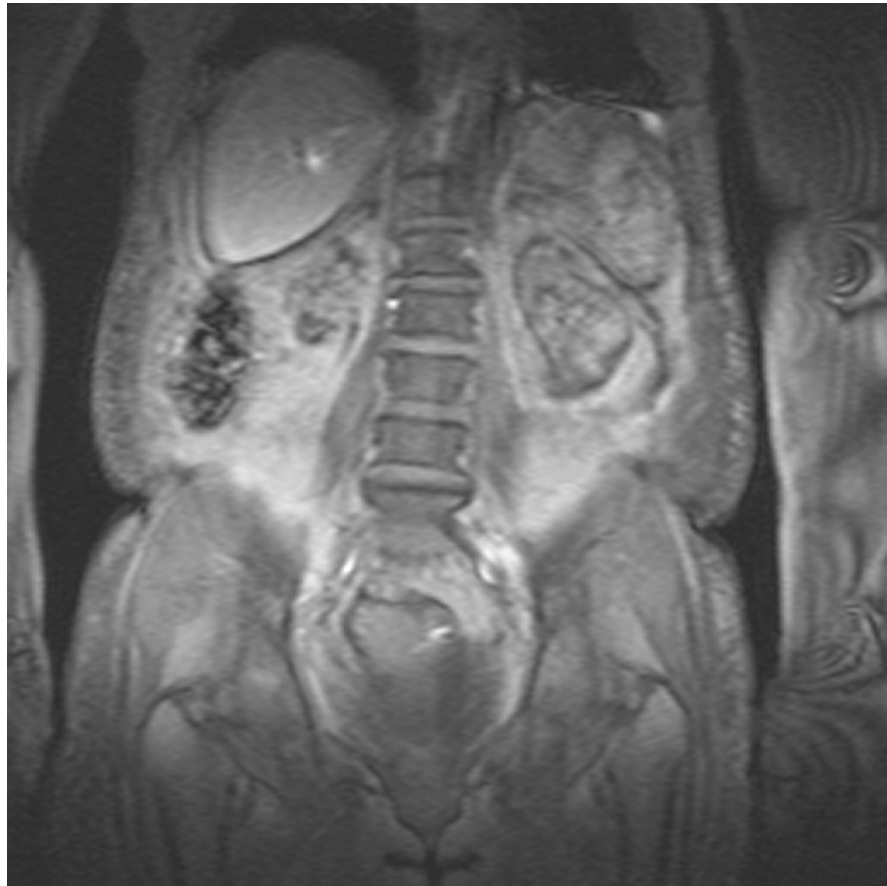


## **RENAL IMAGING**

### **Principles**

The urinary tract can be visualised anatomically with Ultrasound, CT and MRI, anatomically and semi physiologically with x-rays (IVU) and physiologically with Nuclear Medicine studies.

This MRI shows the liver, spleen, spine, kidneys and muscles. It provides excellent anatomical information but no physiological data.



### **Indications**

Renal pain, infection or haematuria. Bladder outflow problems. Renal transplant follow-up.

### **Contraindications**

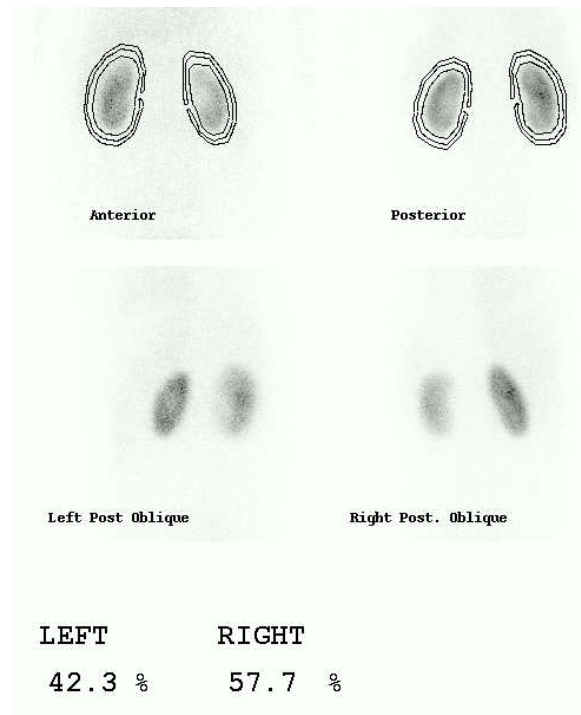
None.

## Patient preparation

Patients should be well but not over hydrated. In cases of children with UTIs, they must be on long-term antibiotics for 6 months prior to the DMSA scan.

## How to perform the nuclear medicine tests

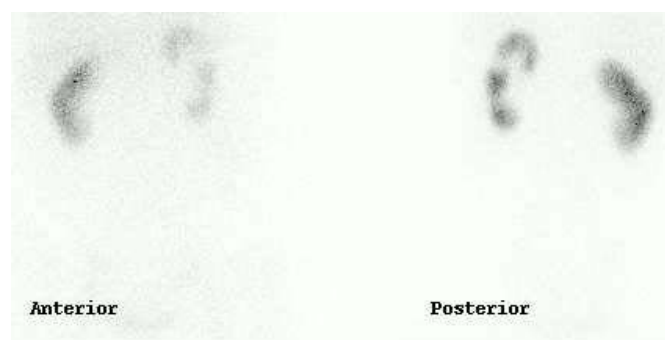
There are two main types of Nuclear Medicine renal imaging - static and dynamic.



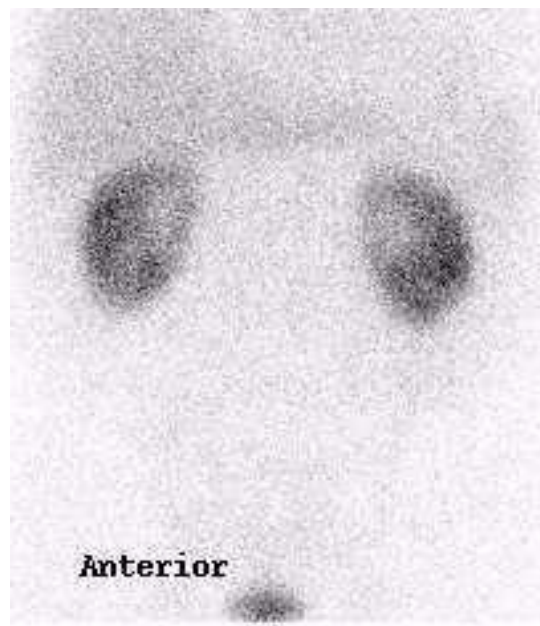
This static renal image is obtained using 80 MBq  $^{99m}\text{Tc}$  labelled DMSA in adults, proportionately less in children.

Anterior, posterior and oblique images are acquired, and then by drawing regions of interest around the kidneys with appropriate background regions, the relative renal function can be calculated using the geometric mean method. The scan above is normal.

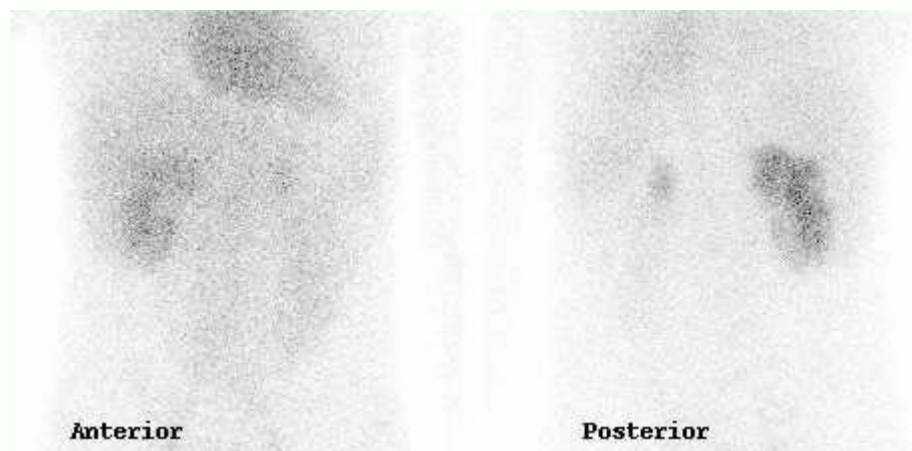
The images themselves will also show if there are any scars or photon-deficient areas.



The above scan shows scarring in the left kidney, and the scan below shows a photon-deficient area due to a tumour.

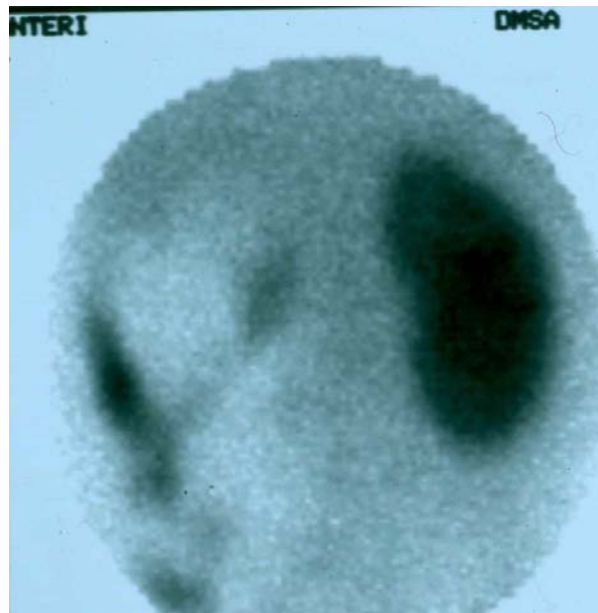


In cases of renal failure, the isotope is not cleared by the kidneys, and so the blood background is very high and the kidneys seen poorly.

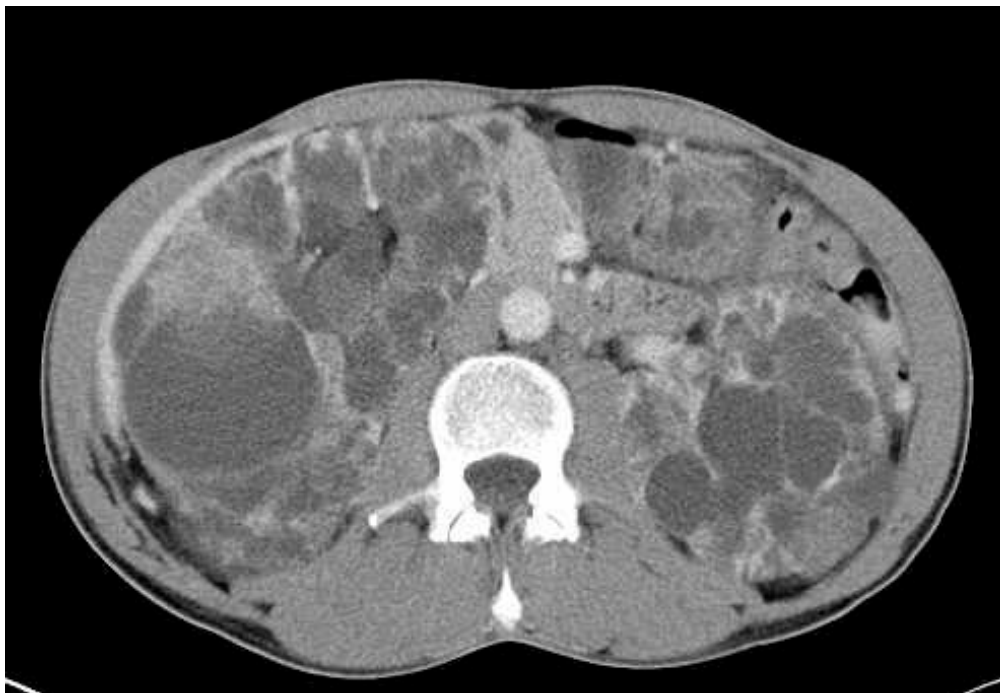


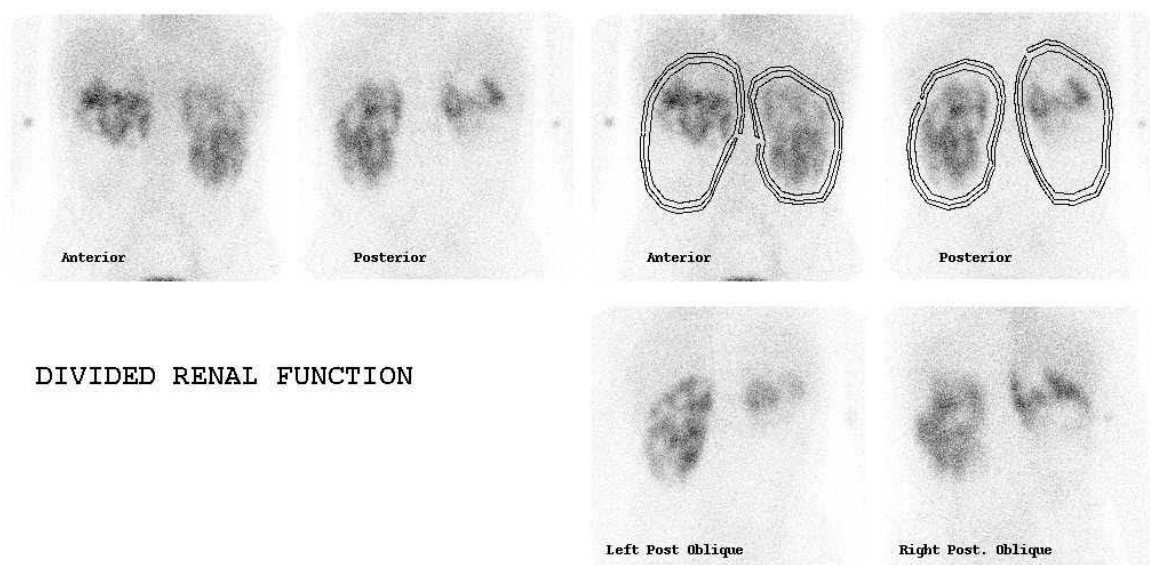
In cases of gross hydronephrosis, a DMSA scan will be very helpful in assessing the degree of renal function in the hydronephrotic kidney, and if less than 15% may well indicate nephrectomy as the treatment of choice.

The image below shows a gross right hydronephrosis.



The CT below, from another patient, shows huge bilateral polycystic kidneys.

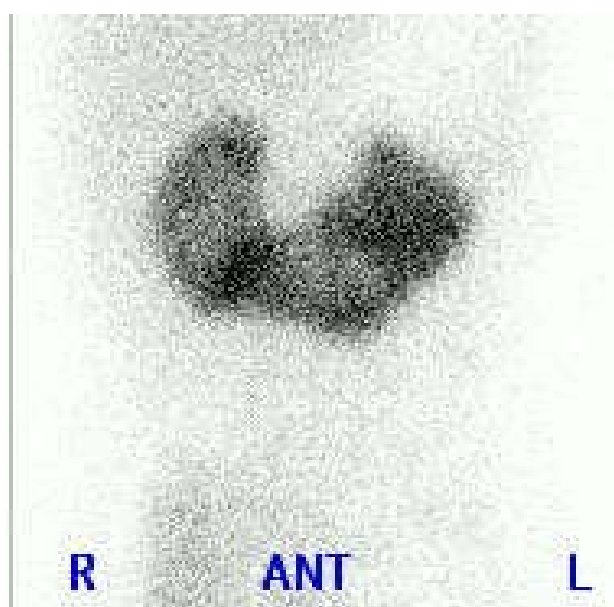




Nuclear Medicine Department  
Charing Cross Hospital  
LONDON UK

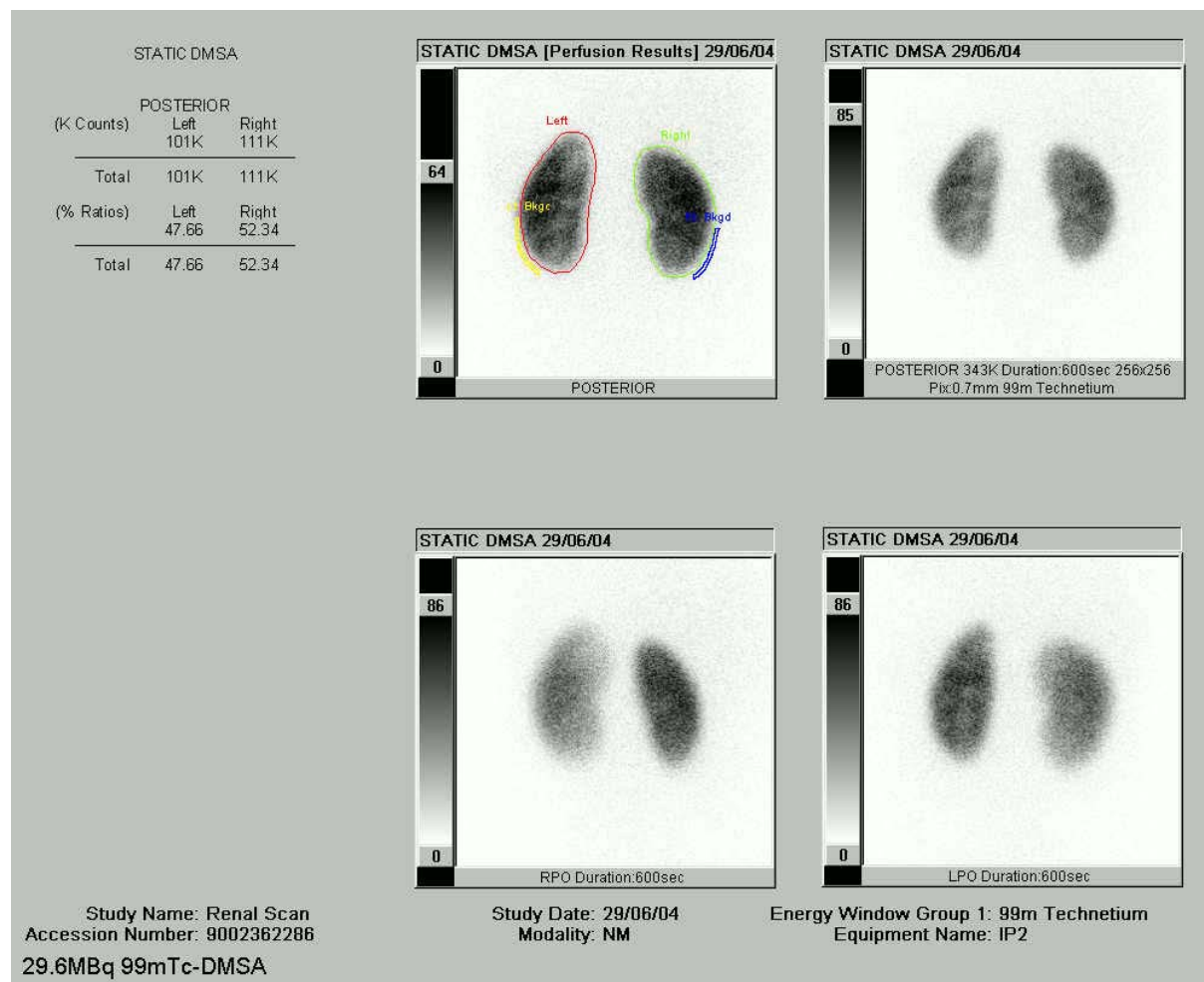
LEFT	RIGHT
61.3 %	38.7 %

The DMSA scan above in this case of bilateral polycystic kidneys shows which parts of the kidneys are functioning, and also the relative function.



DMSA static scans are also useful in cases of irregular renal morphology, such as horseshoe kidneys, as above, and also in following up cases of renal transplantation when there is a question of rejection.

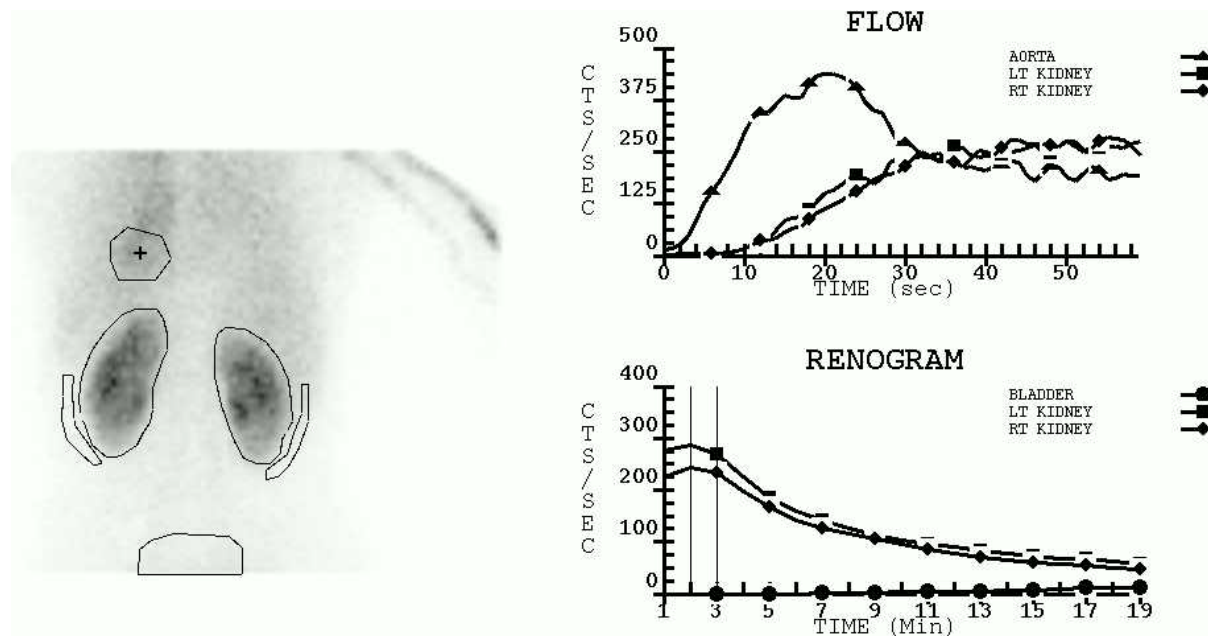
Most DMSA scans are performed in children with repeated urinary tract infections. The infections must be diagnosed bacteriologically, and the child is put on long-term low dose antibiotics for six months before the scan is performed. Should the scan be performed in the acute infective stage, then the DMSA scan will show very little uptake in the affected kidney, giving an erroneous result. The scan is performed to show any scarring and to show the relative renal function.



The normal range is 45 - 55%, so the above scan shows normal renal function.



Dynamic scans are equivalent to the IVU, but by computer analysis also allow relative renal function to be calculated. The studies are often done by stressing the kidneys by injecting furosemide 15 mins prior to injecting the  $^{99m}\text{Tc}$ -MAG3. The administered dose is 100 MBq in adults, proportionately less in children.

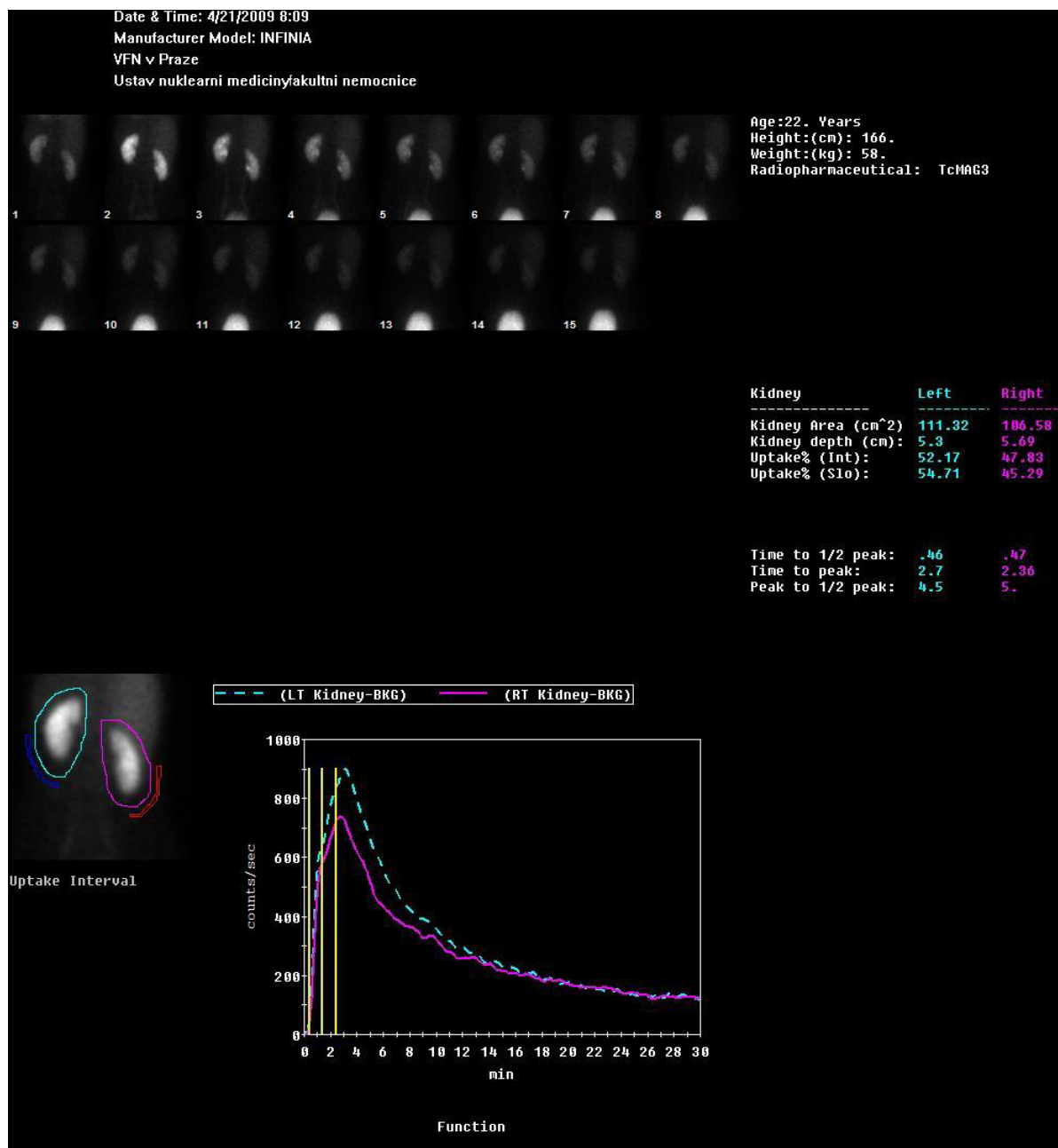


This is a normal  $^{99m}\text{Tc}$ -MAG3 renogram showing good uptake and rapid bilateral clearance in the two graphs on the right of the image.

Most computer programs differentiate between the renal blood flow (upper) and the renal clearance curves (lower). This allows assessment of renal artery input, which is essential in investigating hypertension if renal artery stenosis is suspected. The renogram curve shows how the kidneys actually clear the isotope.

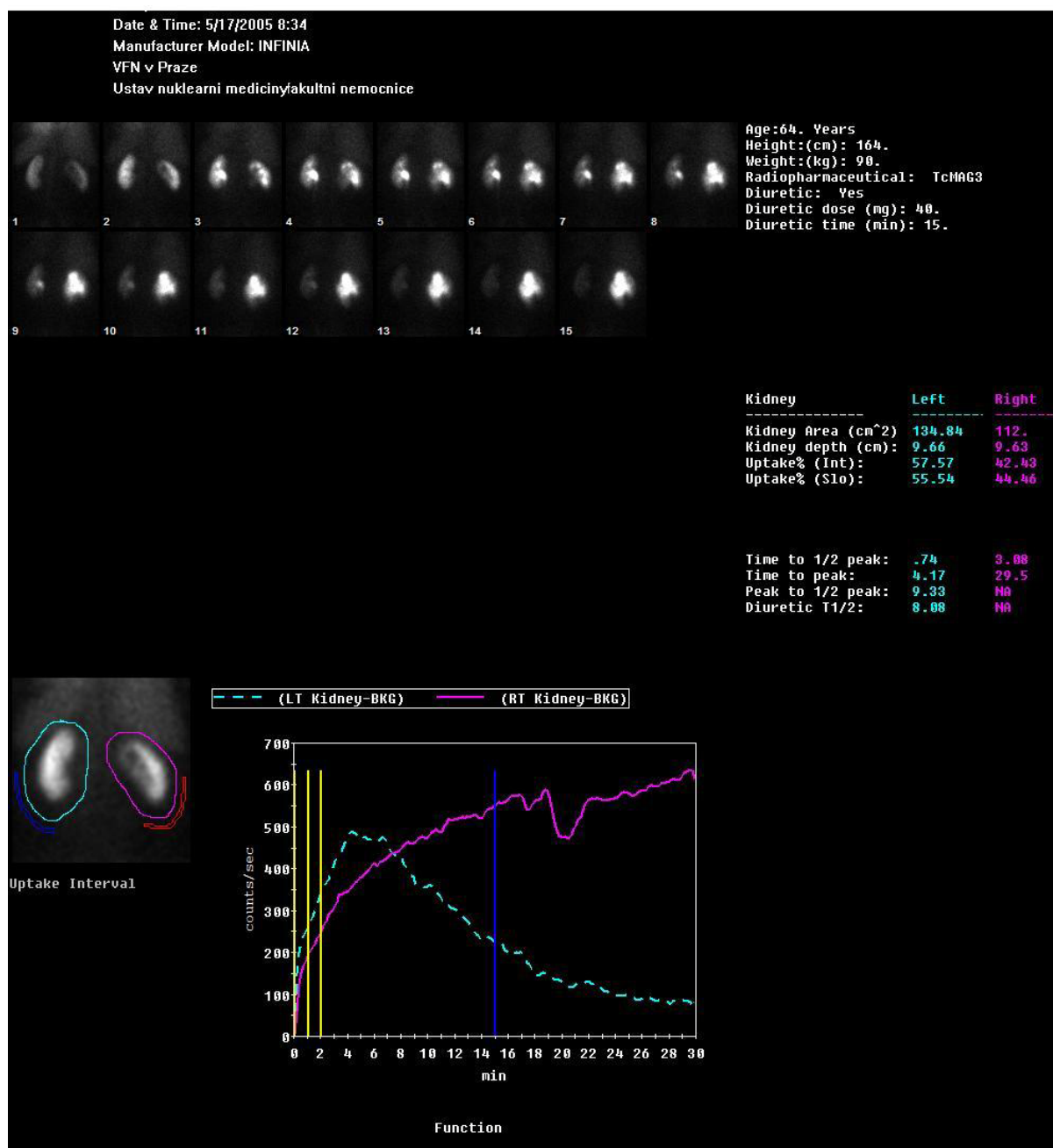
Some computer programs allow the data to be demonstrated on a continuous curve, as below, which also shows a selection of the images in sequence and the percentage function.





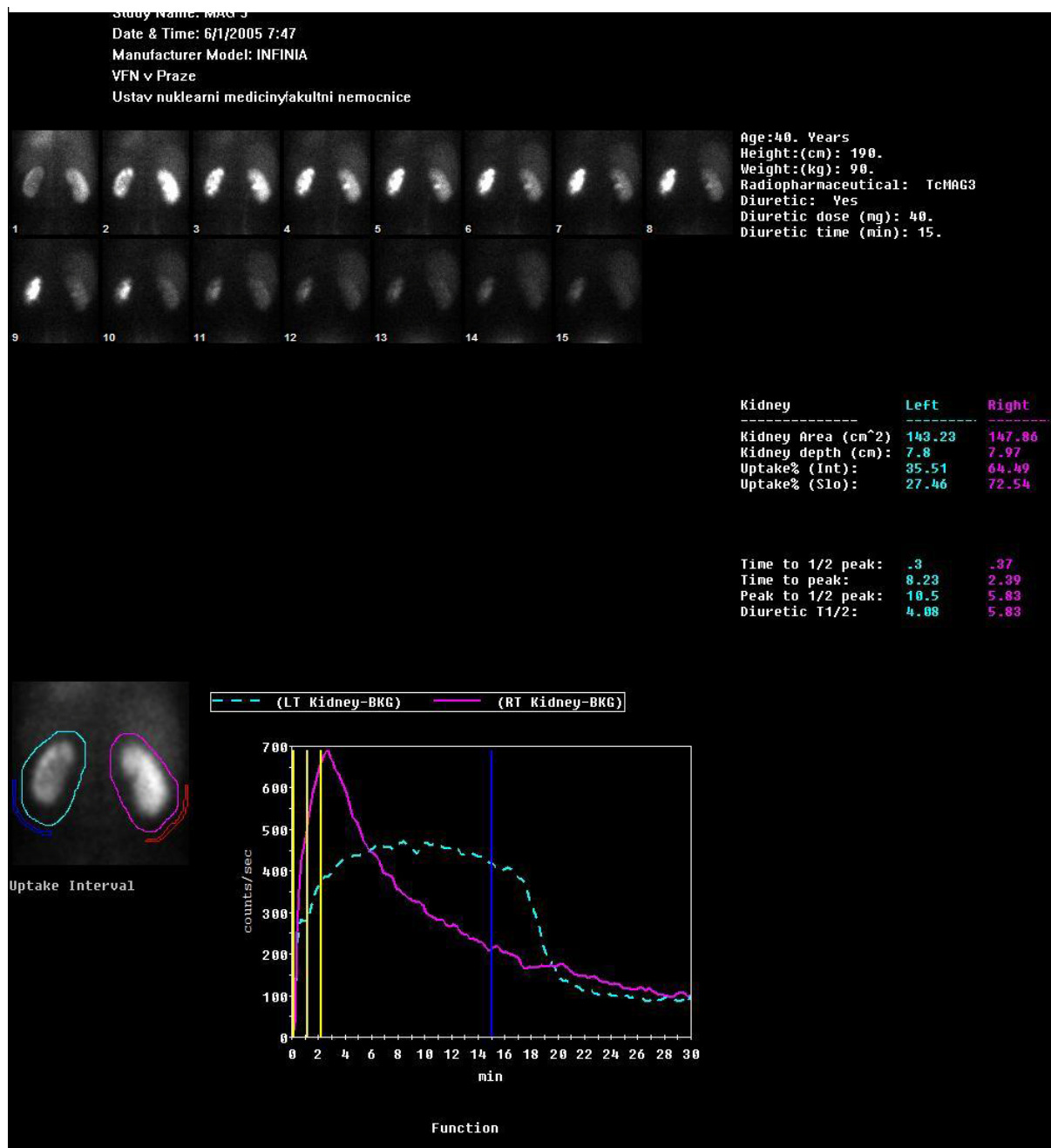
Courtesy of Dr Jozef Kubinyi, Institute of Nuclear Medicine, 1<sup>st</sup> Medical Faculty, Charles University

The images (below) show the typical appearances of obstruction on a renogram. Note that furosemide was given half way through the study, and that there was no clearance afterwards. The appearances of the sequential images confirm this.



Courtesy of Dr Jozef Kubinyi, Institute of Nuclear Medicine, 1<sup>st</sup> Medical Faculty, Charles University

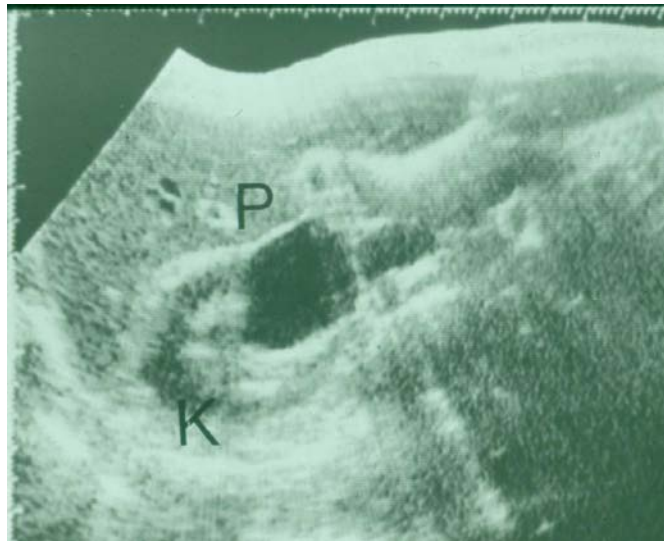Furosemide studies are important in determining whether the full renal pelvis is due to pelvi-ureteric junction (PUJ) obstruction, or simply due to a saggy extra-renal pelvis. This information is used in planning surgery, since operating on a saggy bag will not improve the overall situation.



Courtesy of Dr Jozef Kubinyi, Institute of Nuclear Medicine, 1<sup>st</sup> Medical Faculty, Charles University

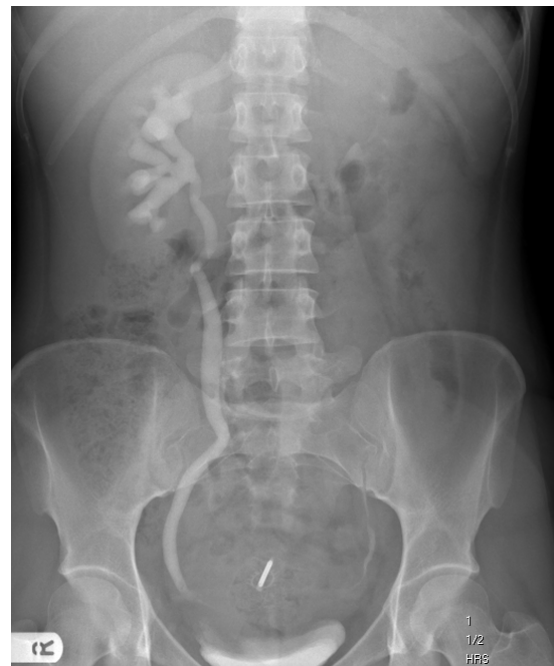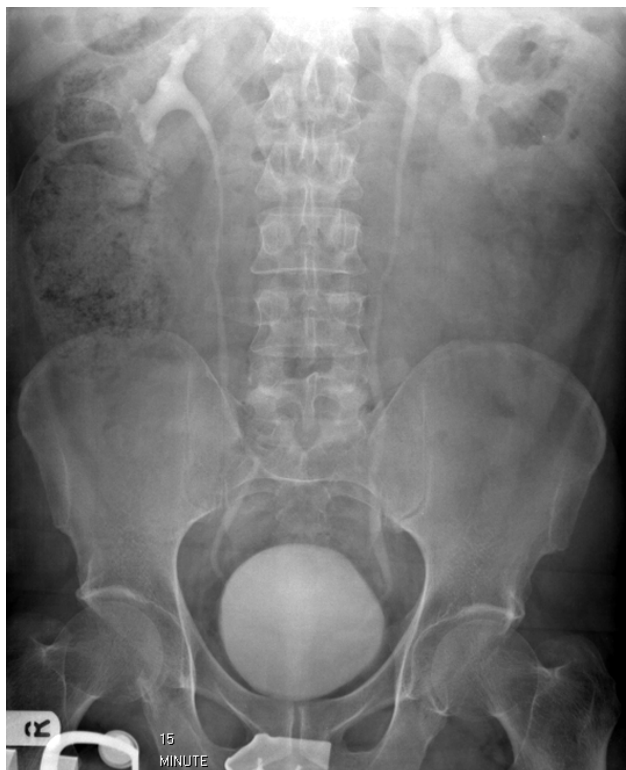These images initially suggest obstruction on the left, but there is rapid clearance after the furosemide indicating a saggy bag, and this is also well shown on the sequential images.

The dilated renal pelvis can also be well shown on Ultrasound.



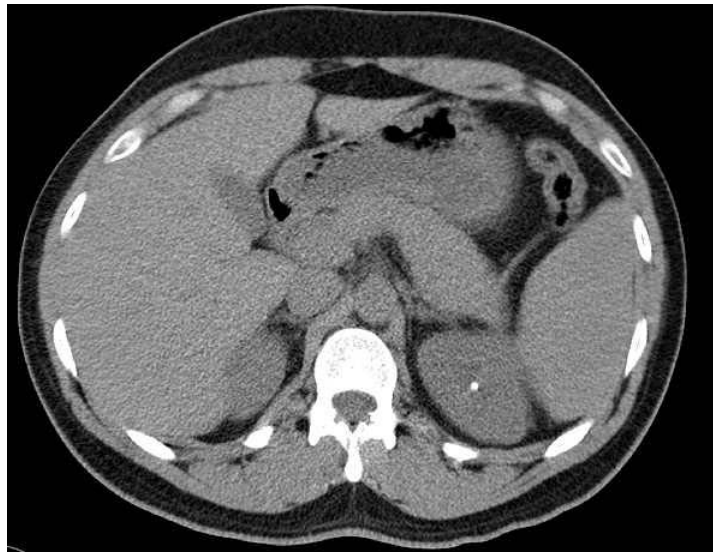
P = pelvis, K = kidney

Other causes of obstruction may be due to stone, ureteric problems or retroperitoneal fibrosis. These are not normally investigated with renography, rather with CT or IVUs.



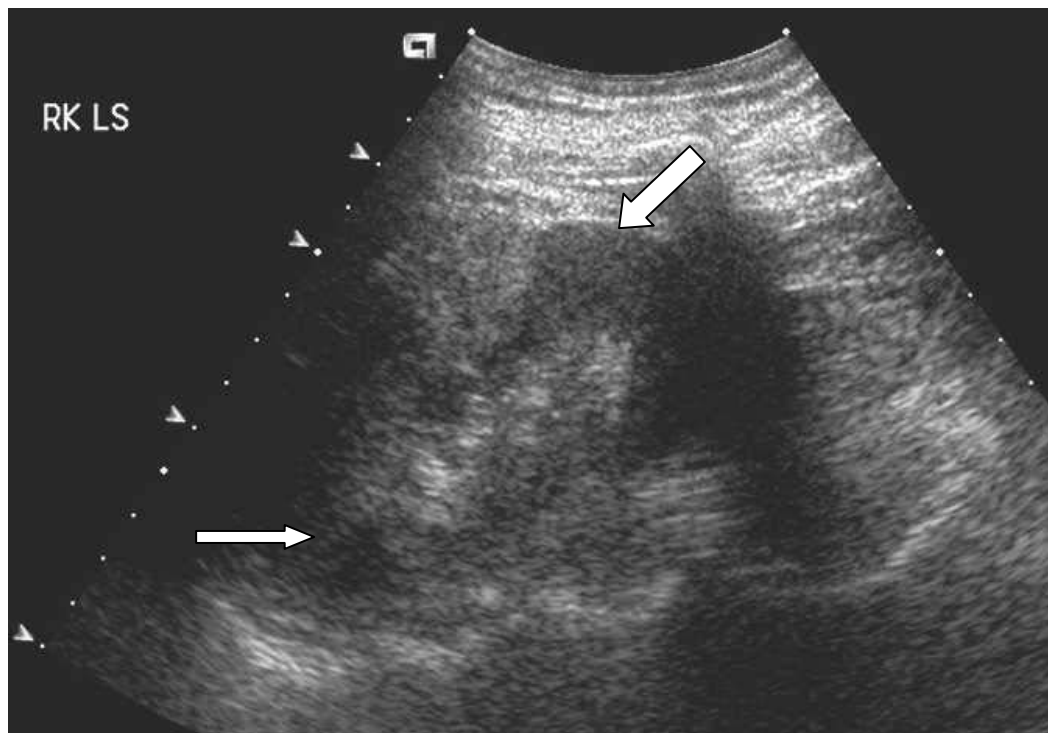
The left x-ray shows a normal IVU, whilst that on the right shows obstruction at the right vesico-ureteric junction in a female patient. Note the IUCD.

Stone disease is best imaged with CT.

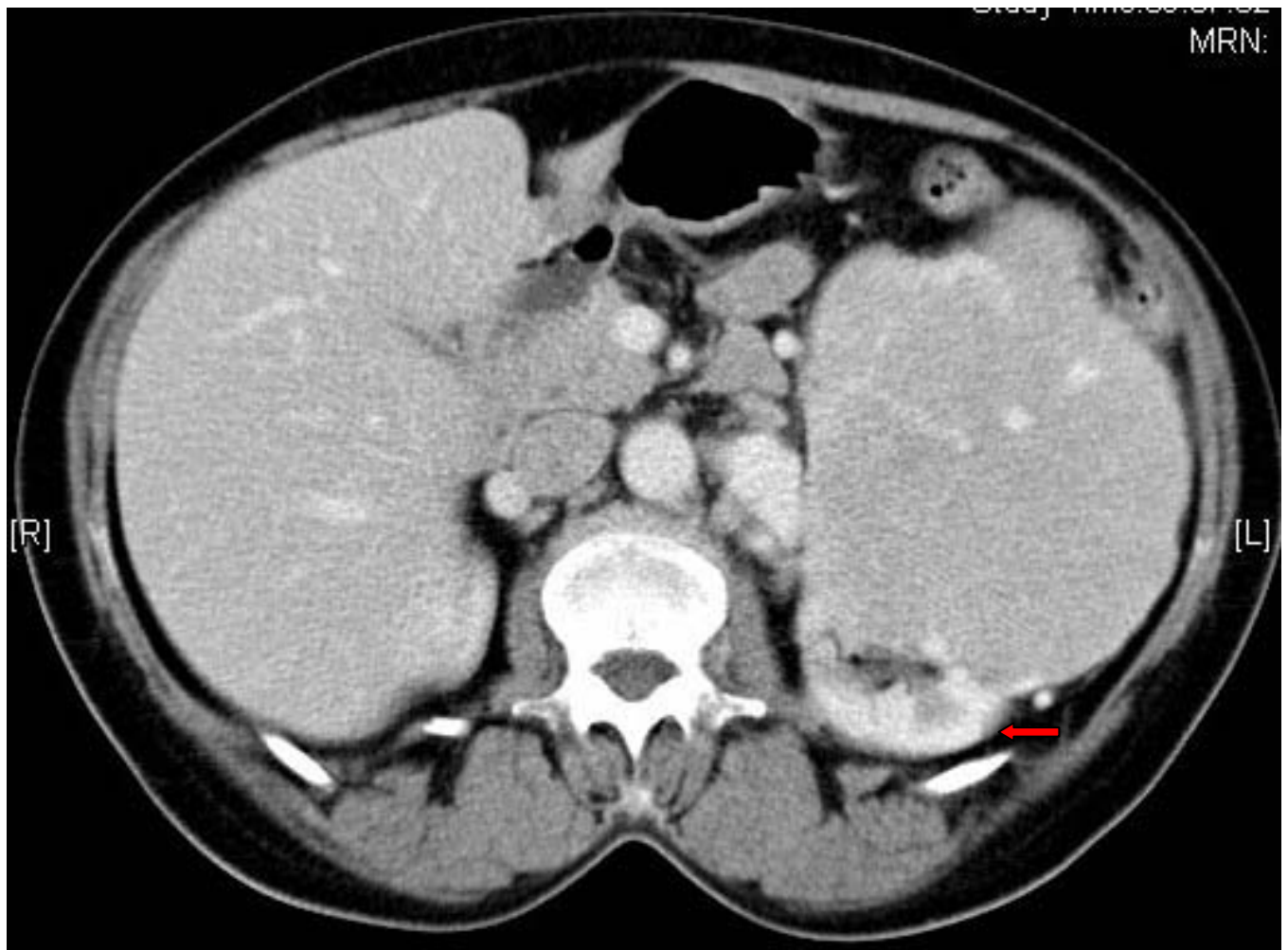


This CT of the upper abdomen clearly shows the liver, gall bladder, pancreas, spleen and the left kidney, with the top of the right kidney also being visualised. The dense white spot in the left kidney is a renal calculus.

Haematuria is also best investigated with Ultrasound and CT.



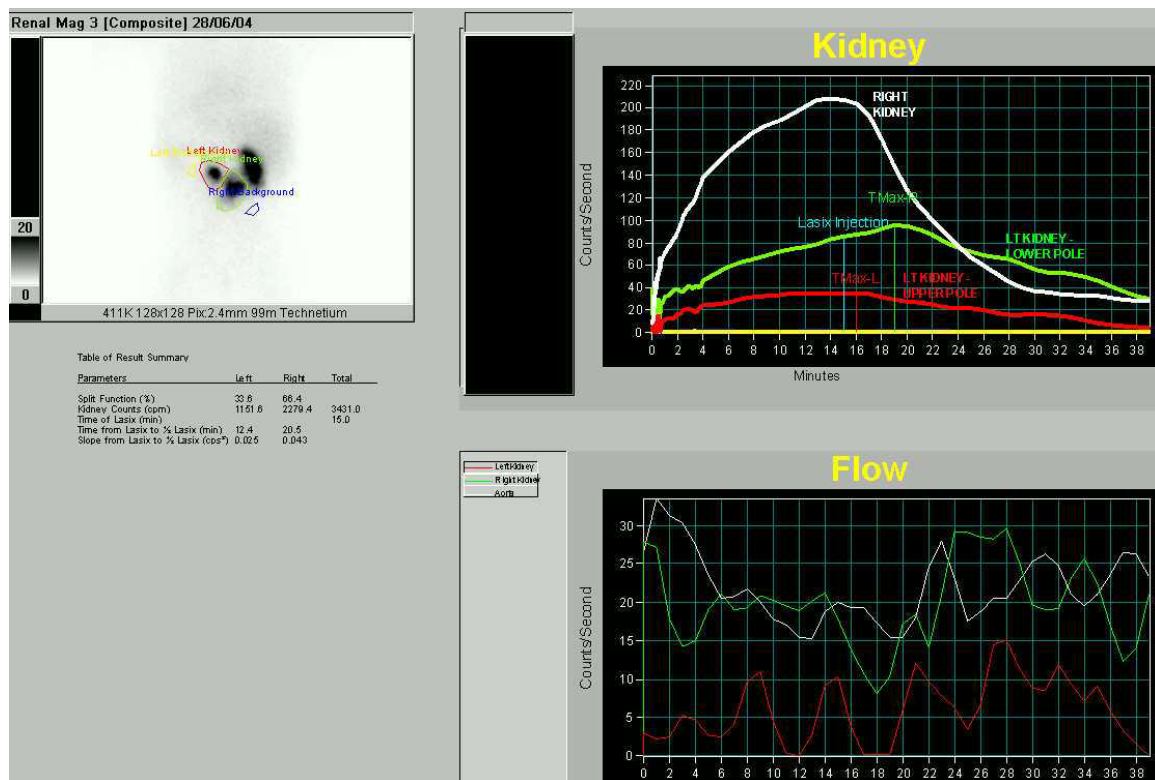
This Ultrasound shows normal renal substance at the upper end of the kidney (broad arrow) with a large amorphous mass at the lower end (thin arrow) due to a renal cell carcinoma.



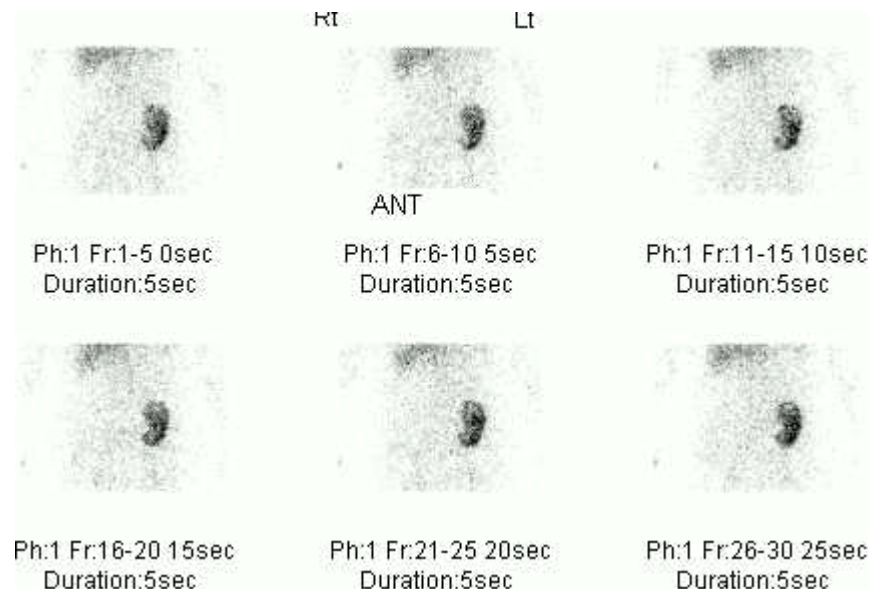
The CT image clearly shows a large left renal tumour arising from the kidney (arrowed). Note that the renal parenchyma and aorta are white - this is because the patient was given iv contrast, and vessels can also be seen within the tumour.



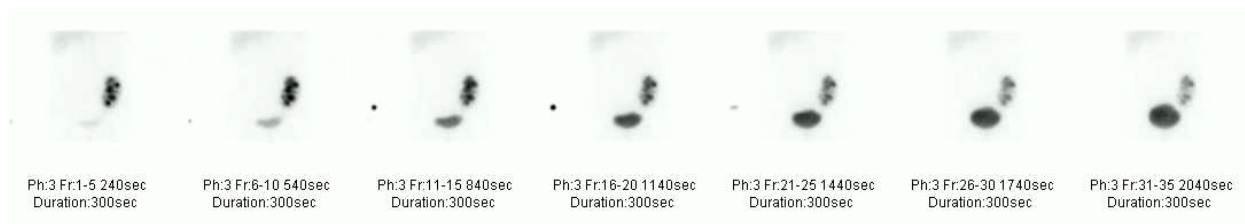
Studies can be performed even in tiny children with urinary tract problems.



Transplants can also be imaged dynamically to assess their function, once they are established and there is no risk of rejection.

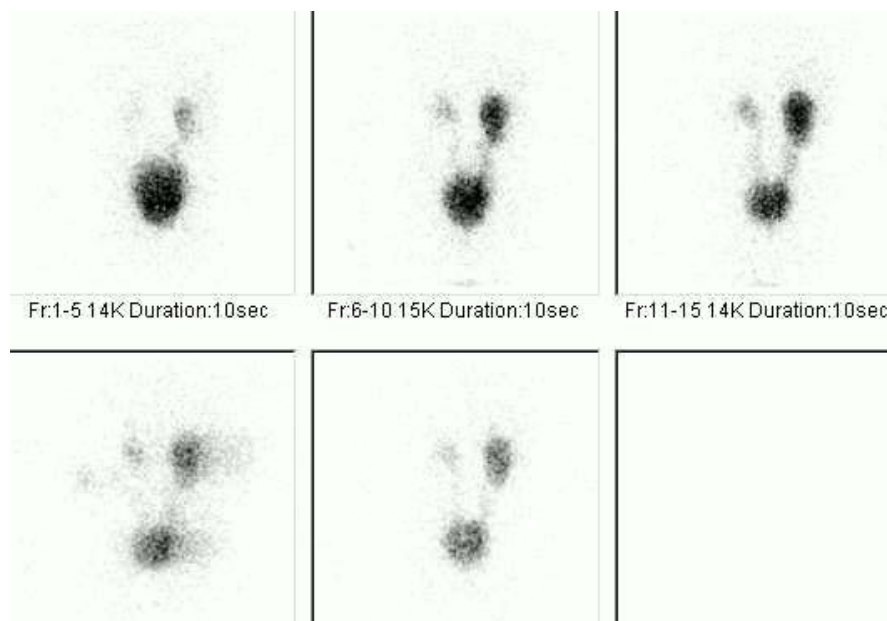


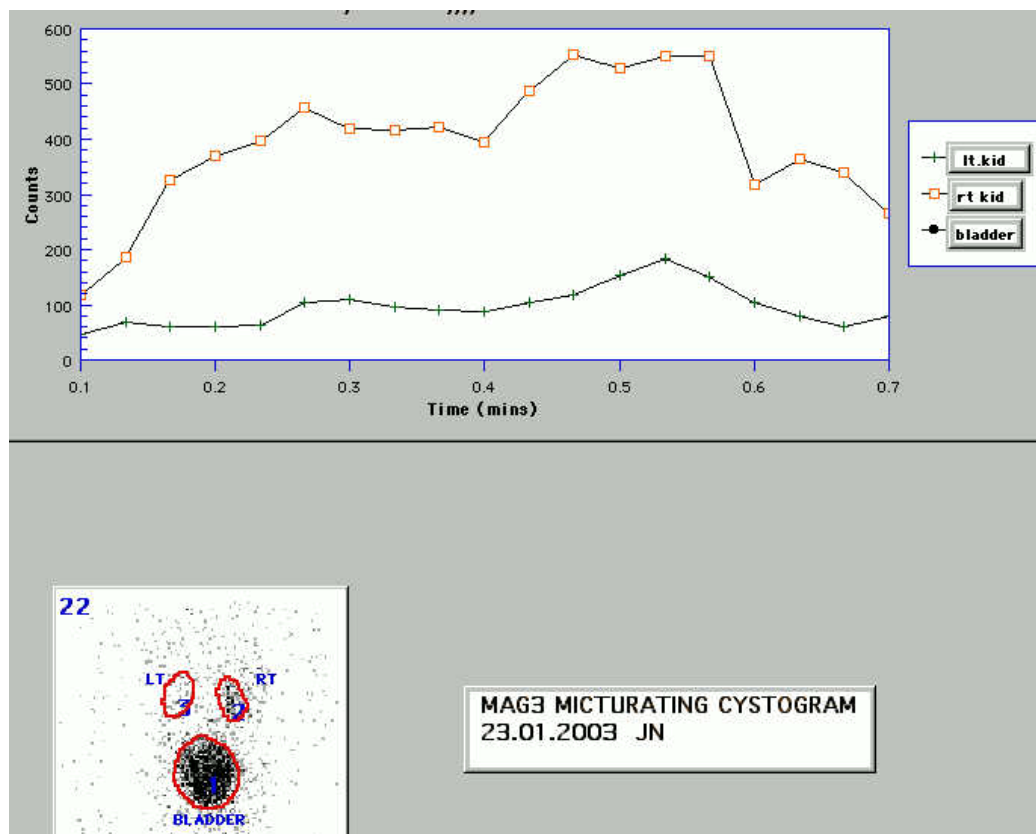




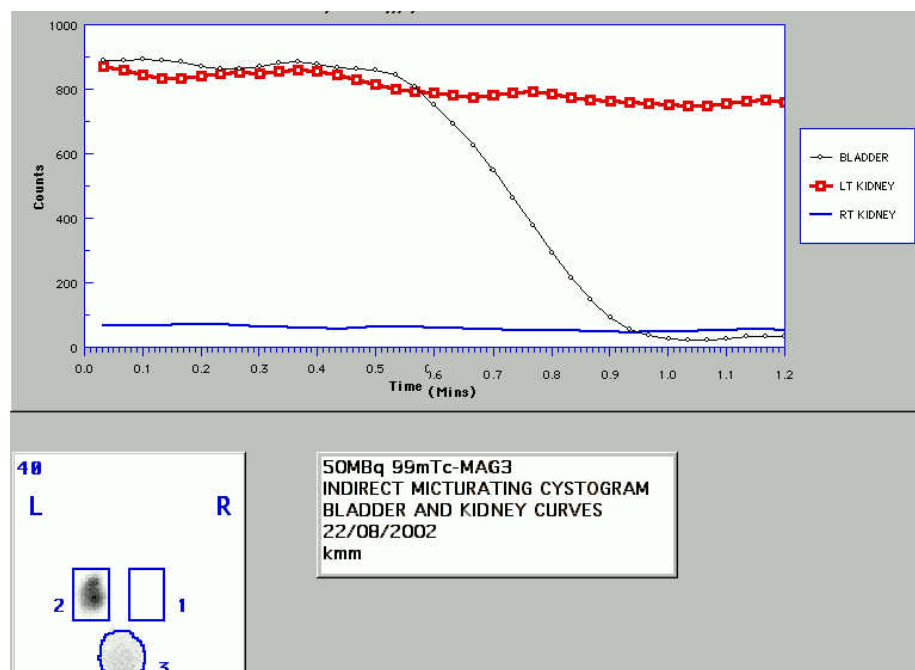
These images show a transplant in the LIF, functioning well.

Reflux is important in children under 5 years of age, since Grade 4 reflux, together with urinary tract infections, leads to renal scarring and hypertension later in life. Micturating cystograms may be carried out at the end of a MAG3 renogram, when the patient micturates whilst standing or sitting in front of the gamma camera. A series of images is obtained, and time activity curves generated.





The study below shows that the bladder empties well, there is no reflux on the right, but the left kidney is obstructed at the PUJ.



## Diagnostic algorithms

### Renal pain

- X-ray including IVU
- US
- Microbiology
- CT for stone disease and tumour
- Renography

### Infection

- Microbiology
- US
- DMSA in children

### Haematuria

- US
- CT
- Bone scan

### Bladder outflow problems

- X-ray cystography in adults
- US +/- prostatic biopsy
- Bone scan where prostate cancer suspected
- Radionuclide cystography in children

### Transplant follow-up

- DMSA

## VASCULAR IMAGING

### Principles

Vascular imaging is mostly performed radiologically, using catheters and intra-arterial contrast media, or MRI (MR angiography). Nuclear Medicine studies have a place in investigating graft problems such as infection. These can be studied either with  $^{99m}\text{Tc}$  HMPAO or PET/CT.

### Indications

Post-graft surgery complications suggesting infection.

### How to perform the Nuclear Medicine tests

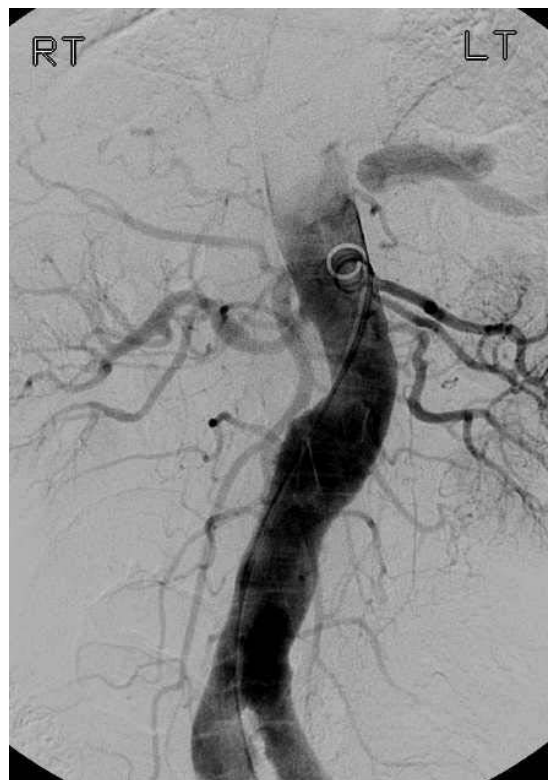The extent of the active disease can best be shown with a labelled white cell study using  $^{99m}\text{Tc}$ -HMPAO. The administered activity is 200 MBq and images obtained at 1 and 3 hours after injection. PET/CT uses 350 MBq  $^{18}\text{F}$ -FDG with imaging after 60 mins, as usual.

### Patient preparation

Nil by mouth for 6 hours before the PET/CT.

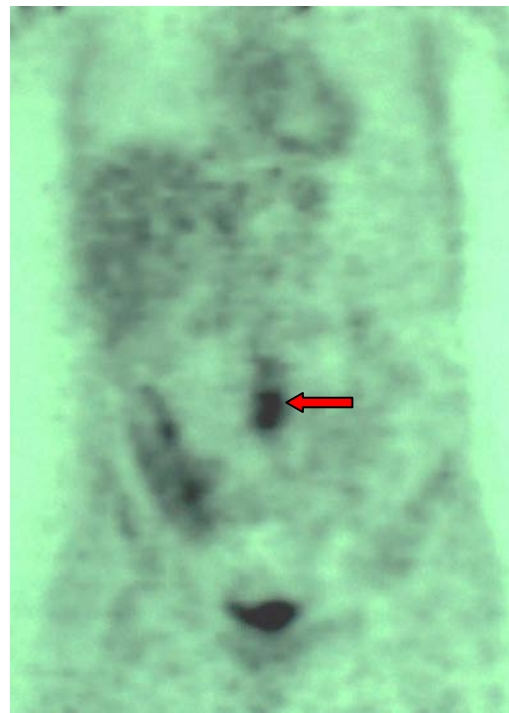
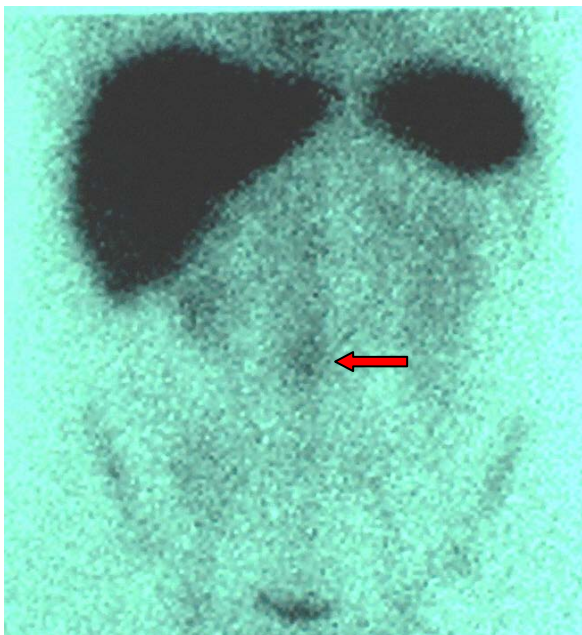
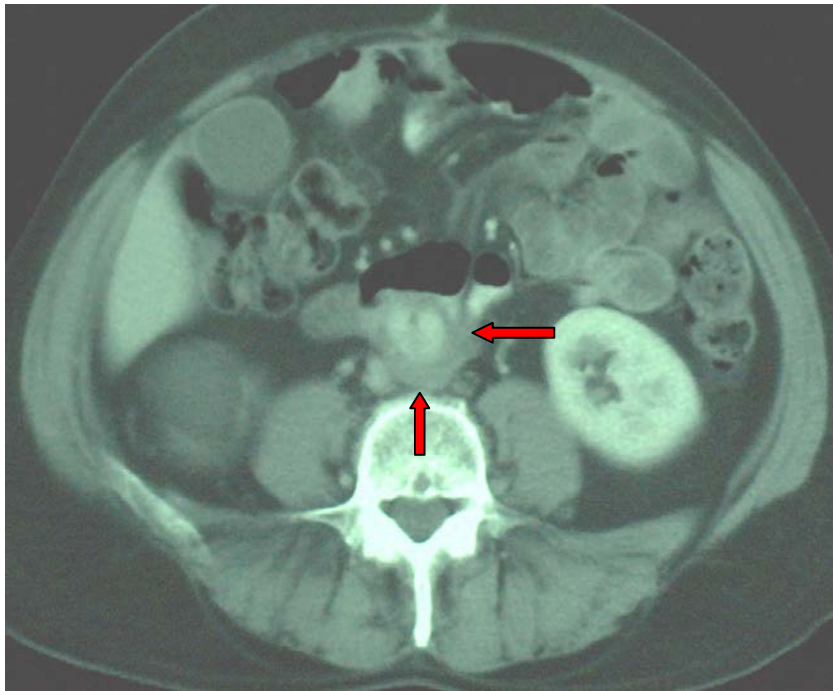
### Examples

This is a typical aortogram using iodine-containing contrast medium injected by a pump intra-arterially. The catheter is clearly seen.



In the series of images below, the top image (CT) shows an ill-defined collection around the aorta (arrow) in a patient who has had a graft. The CT shows the anatomy very clearly, as does Ultrasound, but cannot differentiate between fibrosis and active inflammatory change.

The lower left image uses  $^{99m}\text{Tc}$ -HMPAO and shows minimally increased activity in the mid-abdomen (arrow), and the lower right image is a PET scan using  $^{18}\text{F}$ -FDG which shows intense uptake at the site of the inflammatory change (arrow).



## **Diagnostic algorithms**

Arteriography

CT/Ultrasound

HMPAO or PET/CT in suspicious cases

## **RADIONUCLIDE THERAPY**

Various radiopharmaceuticals may be used in targeted radionuclide therapy. Most of them are  $\beta^-$  emitters, since the range of  $\beta^-$  particles is between 2 and 11mm depending on the energy. There is some new work using  $^{211}\text{At}$ , an  $\alpha$  (alpha) emitter, in melanoma, but this is largely experimental.

Both benign and malignant disease may be treated.

### **Benign disease.**

The main benign disease treated is thyrotoxicosis, using  $^{131}\text{I}$  as NaI. This disease occurs mainly in women. The patient needs to have been assessed by an Endocrinologist or a Nuclear Medicine specialist dealing with such therapy. The patient can be treated whilst toxic, but it is better to render them euthyroid with medication. The best results are achieved in Grave's disease, and there are two main treatment pathways. The first is to administer a large dose, around 550MBq, and render the patient hypothyroid quite quickly, following on with replacement therapy with thyroxine tablets. The second is to give smaller doses, around 400MBq, and try and make the patient euthyroid. Whilst in theory this seems a better option, in practice 95% of patients so treated will be hypothyroid at around 1 year after treatment, and if they are not followed up with thyroid function tests, then they become floridly hypothyroid, and very ill.

Toxic autonomous nodules are also well treated with radio-iodine, and after treatment with around 450MBq  $^{131}\text{I}$  the toxic nodule is eliminated and with luck the rest of the thyroid 'wakes up' after about 3 - 6 months, and the patient becomes euthyroid, so no further treatment is needed.

Toxic multinodular goitre (MNG) may also be treated with  $^{131}\text{I}$  but non-toxic MNG does not respond well to such treatment, and the treatment of choice is surgery.

Theoretically, it may be possible to calculate the dose to the thyroid in Gy, but in practise there are so many variables it is better to use an empirical dose of around 550MBq.

When administering radio-iodine, there are several important points to be discussed. The patient must not be pregnant or practice unprotected sexual intercourse, must not have tiny children around, must not be incontinent and must understand the procedure. Informed written consent is needed. After treatment, the patient may have to stay in hospital or may be able to go home - this depends on the local national regulations. Follow-up is with thyroid function blood tests, and it may well be possible to run a 'Telephone Clinic' where the clinician telephones the patient after each blood test and advises on further therapy.



The other main benign disease treated with radionuclide therapy is synovial proliferation, particularly in rheumatoid arthritis. This technique is widely used in mainland Europe, but not in the UK.

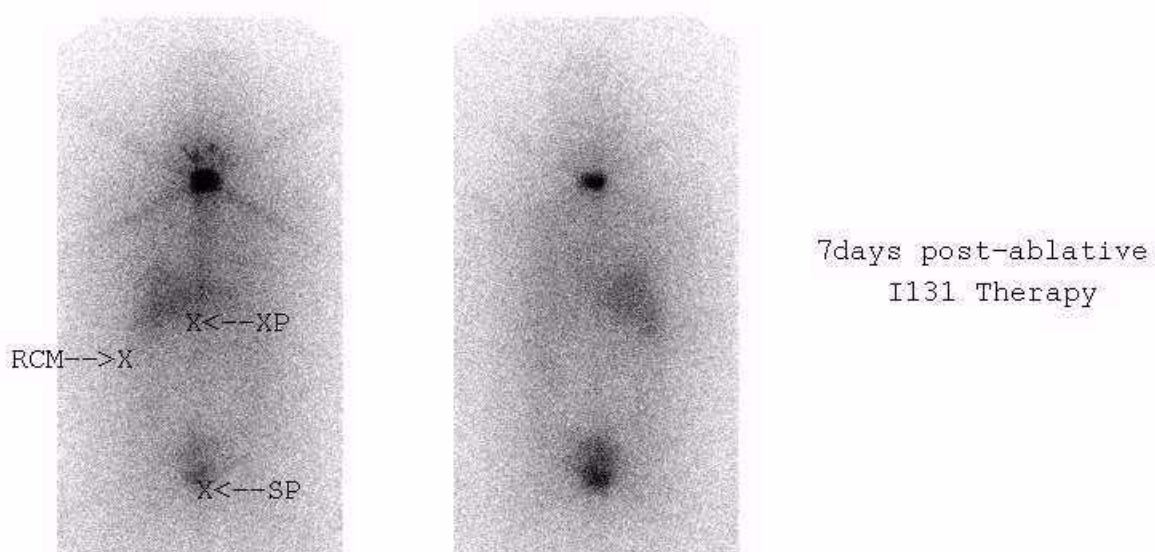
The affected joint is aspirated and then the relevant isotope injected. The joint is then immobilised for a period of time. The choice of isotope depends on the size of the joint. The major contra-indications are septic arthritis, young patients with unfused epiphyses or pregnant women.

### **Malignant disease.**

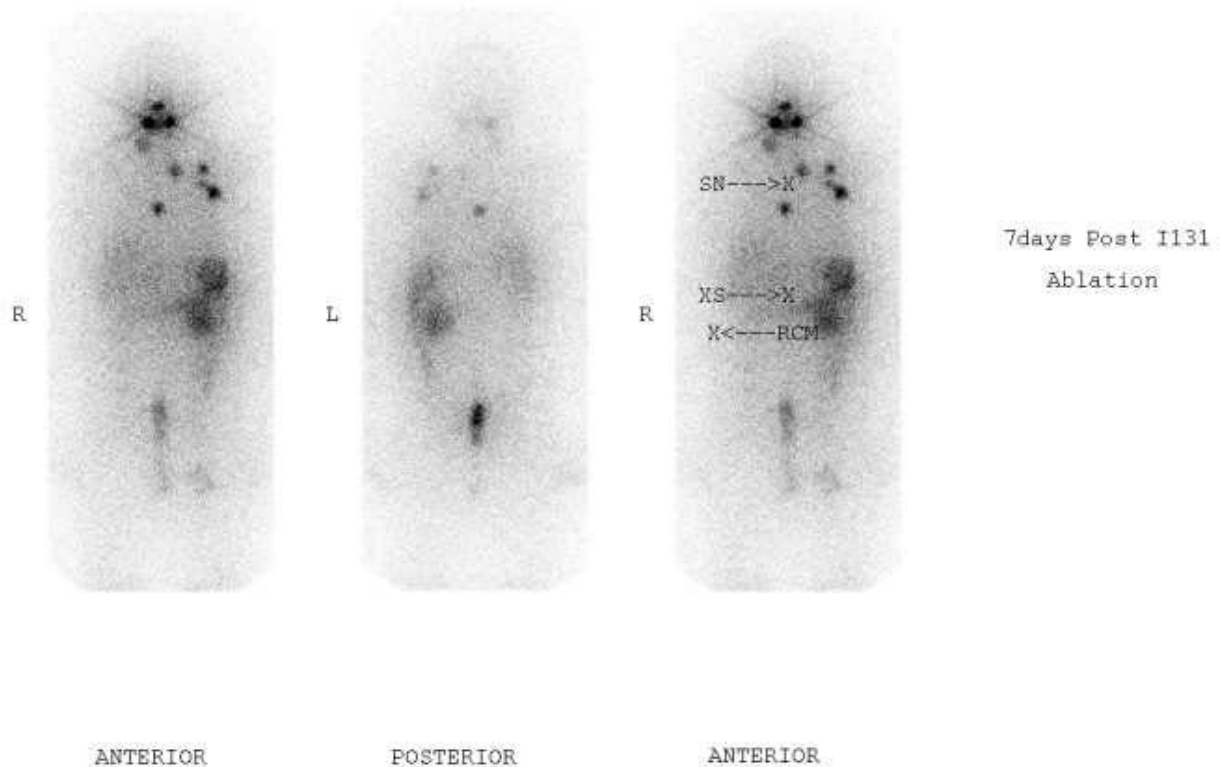
Those treated are listed with the isotopes used.

LESION	ISOTOPE USED
Thyroid cancer - papillary or follicular	$^{131}\text{I}$
Thyroid cancer - medullary	$^{131}\text{I}$ -MIBG
Neuroendocrine tumours	$^{131}\text{I}$ -MIBG
Bone metastases	$^{89}\text{Sr}$ , $^{186}\text{Rh}$ -HEDP, $^{153}\text{Sm}$ -EDTMP
Liver metastases	$^{131}\text{I}$ -Lipiodol, $^{90}\text{Y}$ glass microspheres
NHL	$^{90}\text{Y}$ -Zevelin

*Thyroid cancer.* The primary treatment is total thyroidectomy, after which the TSH begins to rise. Treatment with between 3.7 GBq and 5.5 GBq is given, and the patient scanned 7 days afterwards.



The image above shows uptake in the thyroid bed, with some normal activity in liver and bladder. There are no metastases.

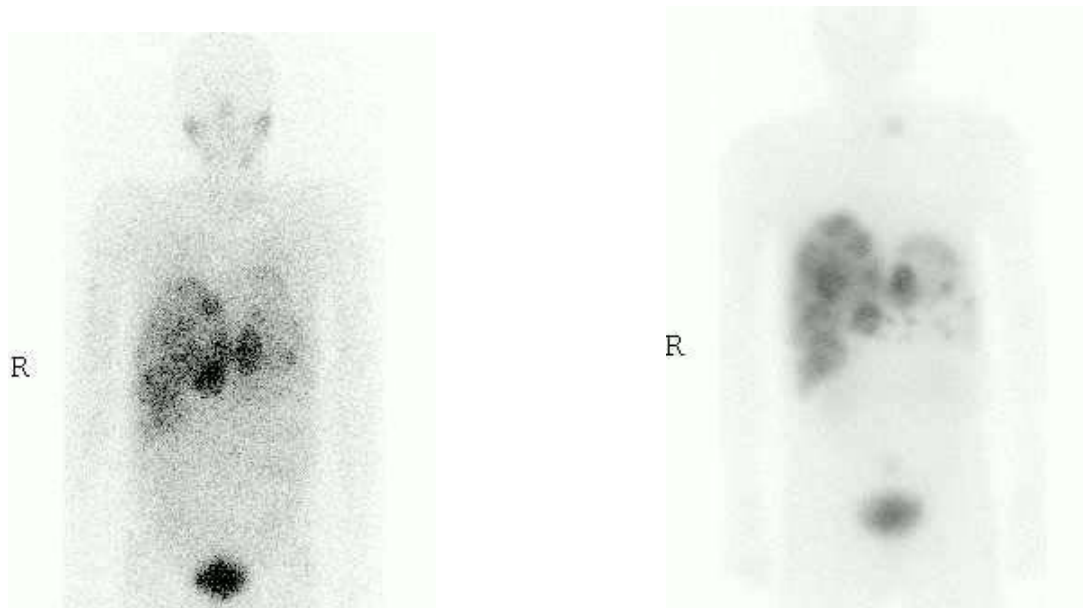


In this image there are obvious metastases in the thorax.

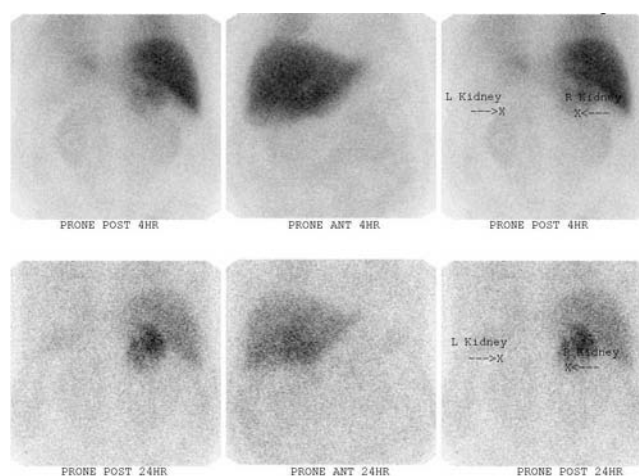
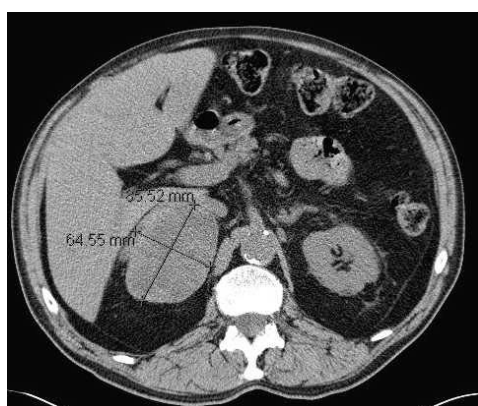
The patient is re-scanned at six months, one, three, five and seven years after ablative therapy, using  $^{123}\text{I}$  which gives better images. If there is evidence of metastatic disease then a further dose of  $^{131}\text{I}$  is given, and the time-line starts again. If after seven years there is no evidence of disease, then the patient is deemed cured.

**Neuroendocrine tumours.** Medullary thyroid cancer is a neuroendocrine tumour which does not take up  $^{131}\text{I}$  as iodide, and so must be treated with  $^{131}\text{I}$ -MIBG, as other neuroendocrine tumours. In general, neuroendocrine tumours are imaged with  $^{123}\text{I}$ -MIBG and  $^{111}\text{In}$ -octreotide to make the diagnosis, and if they take up  $^{123}\text{I}$ -MIBG then  $^{131}\text{I}$ -MIBG can be used to deliver therapy. If they do not, but only take up the  $^{111}\text{In}$ -octreotide, then treatment can be given with  $^{90}\text{Y}$ -lanreotide.

The images below, of the same patient with carcinoid, show that there is poor uptake with  $^{123}\text{I}$ -MIBG (left image) but good uptake with  $^{111}\text{In}$ -octreotide. This would indicate that therapy with  $^{131}\text{I}$ -MIBG would fail.



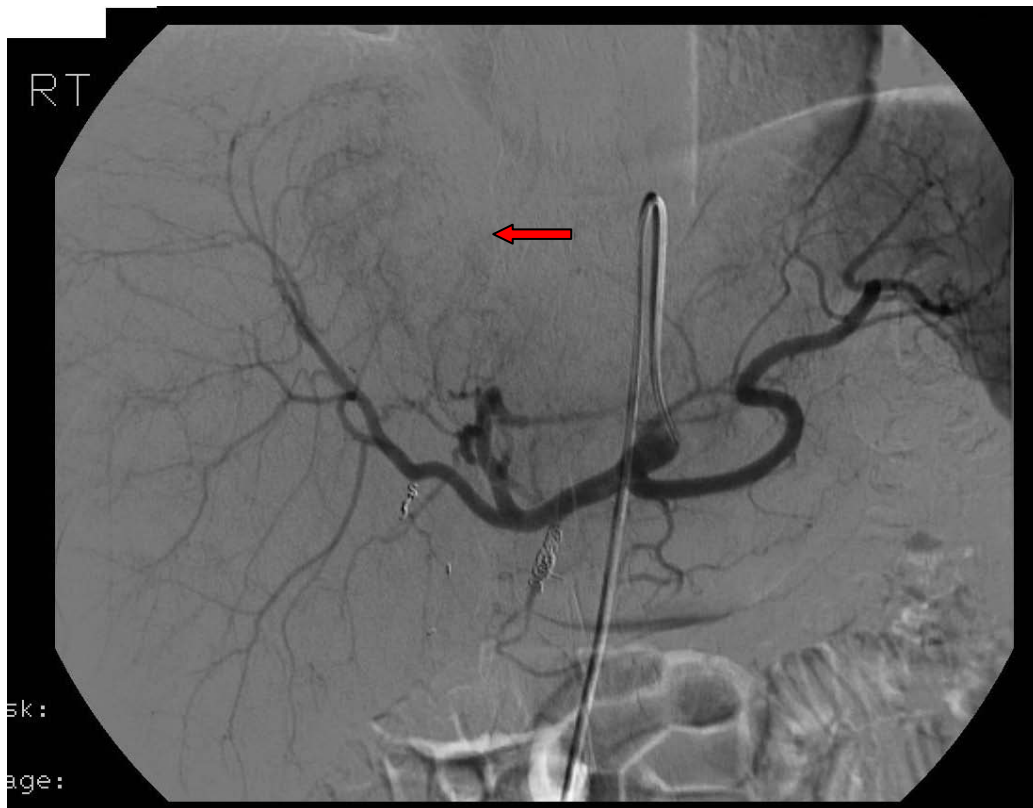
Phaeochromocytoma may be localised or metastatic. If localised, then surgery is the treatment of choice, but if metastatic, then treatment with  $^{131}\text{I}$ -MIBG can be considered.



These images show the CT of the large right-sided phaeochromocytoma and the  $^{111}\text{In}$ -octreotide image.

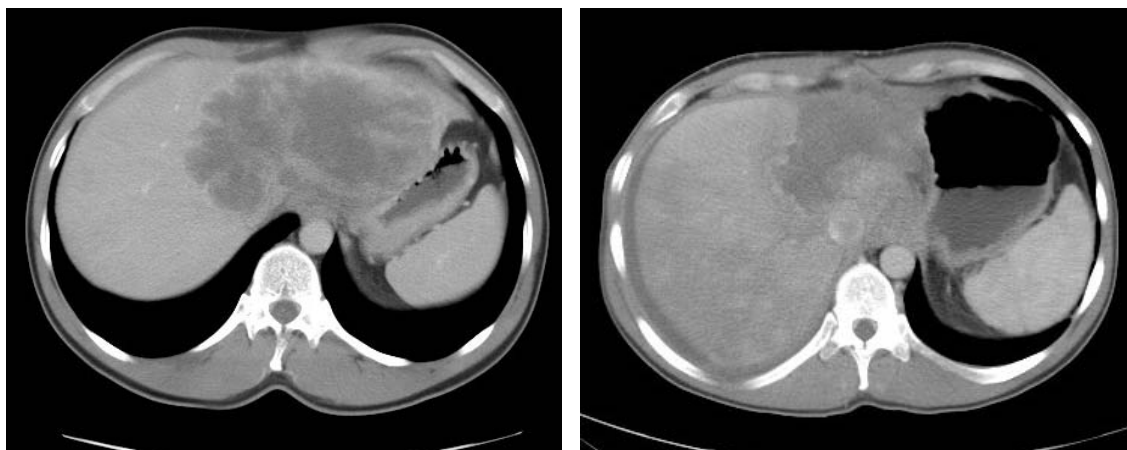
**Bone metastases.** Bone metastases are painful, and may be treated by palliative external beam radiotherapy, or by bone seeking isotopes that are taken up by the rim of the metastasis and so deliver a high local dose with pain relief. Obviously, this option is only possible when there is a positive bone scan. The isotopes used are all  $\beta$  emitters.

**Liver tumours.** These can be treated in a variety of ways - surgical extirpation, cryogenic ultrasound or using  $\beta$  emitters injected intra-arterially into the liver.



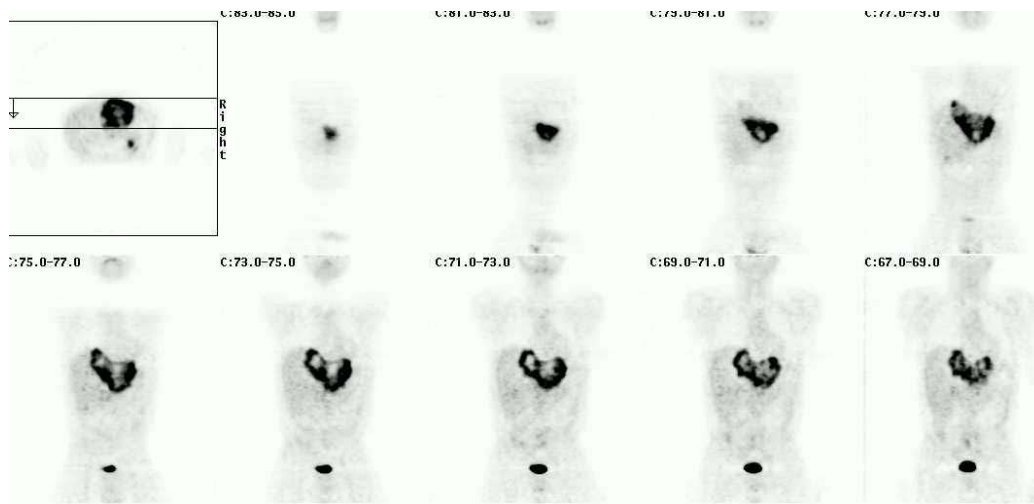
This shows the selective hepatic angiogram, and the tumour blush is arrowed. The catheter would then be advanced to the tumour prior to delivering the agent.

The agents such as  $^{131}\text{I}$ -lipiodol will be trapped in the tumour and cause local tissue necrosis. This method of treatment can be used for hepatocellular carcinomas. The initial imaging is with CT, which can be used to follow up the result of therapy.

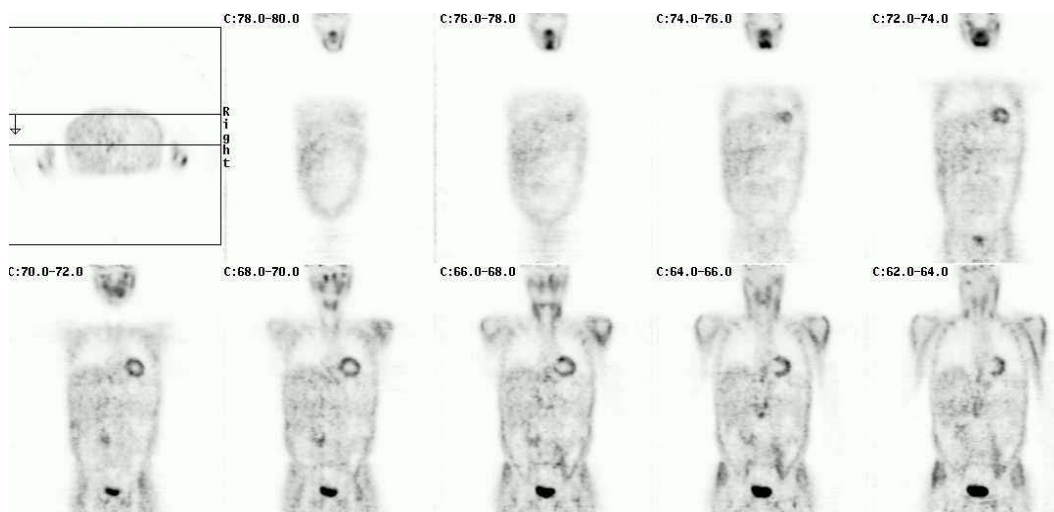


These show the shrinkage of the tumour after treatment.

The metabolic effect of the tumour is best assessed with  $^{18}\text{F}$ -FDG PET.



This image, above, shows the metabolic extent of the tumour shown on CT, and indicates the large necrotic centre. The image below shows that although there are abnormalities shown on the post-therapy CT, there is no metabolically active disease.

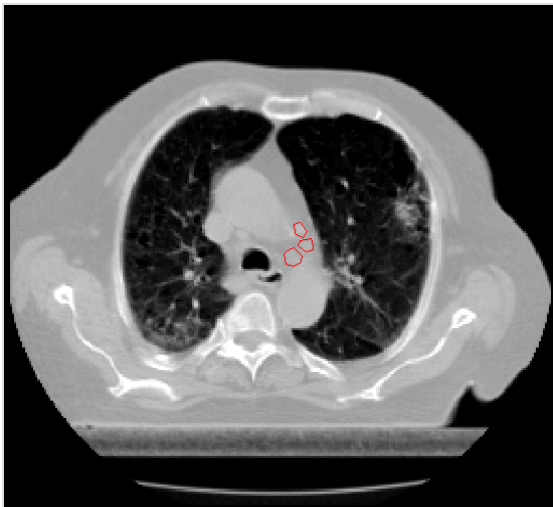


*Monoclonal antibodies.* These are labelled with  $^{90}\text{Y}$  and can be targeted against a variety of tumours. Their names all end in '-mab', such as ibritumomab tiuxetan, which is known as Zevelin, labelled with  $^{90}\text{Y}$ , and is used in the treatment of low grade follicular NHL. Another anti-NHL drug is tositumomab or Bexxar which is labelled with  $^{131}\text{I}$ . This has problems with the gamma radiation which may need the patient to be admitted to a radiotherapy room for the treatment. Both deliver  $\beta$  radiation to the CD20 antigen. The treatments are effective, but expensive, around €20,000 per course of treatment.

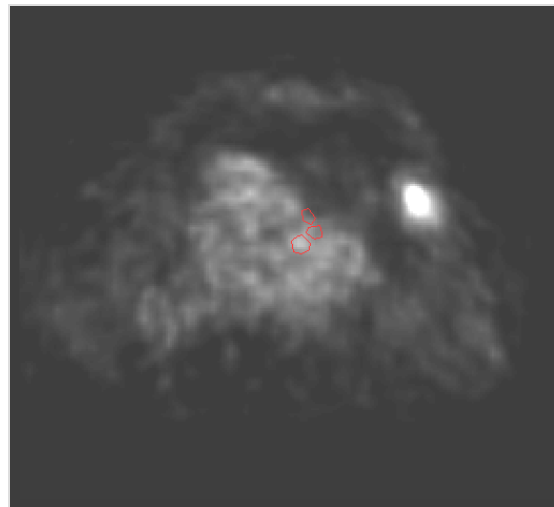
Radiotherapists use PET/CT images to accurately delineate the tumour so that the radiotherapy fields are as close to the tumour edge as possible, and also increasing the number of fields, thus increasing the dose to the tumour. PET/CT machines



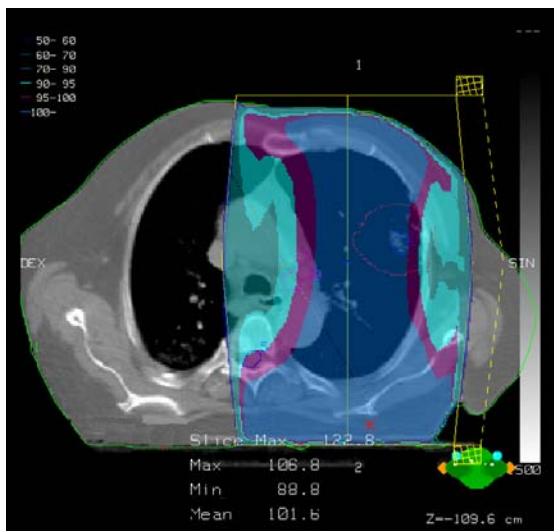
also allow the radiotherapy fields to be calculated directly from the images. This technique is known as intensity modulated radiotherapy (IMRT), which minimises radiation load to surrounding tissues.



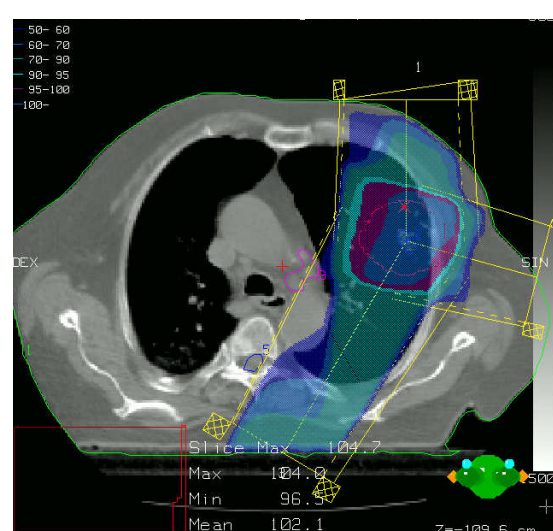
CT image of left mid zone cancer



PET image of left mid zone cancer



CT based radiotherapy planning fields

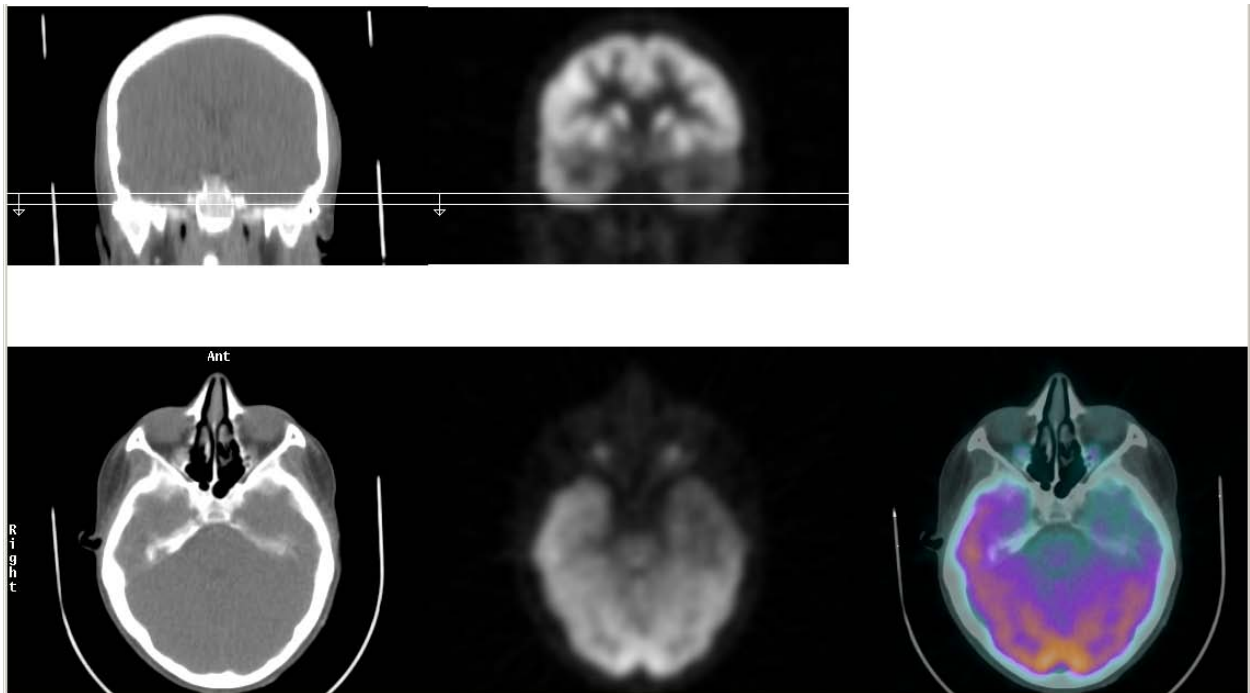


PET/CT based radiotherapy planning fields

After F Fazio, University of Milan

## THE FUTURE

Nuclear Medicine technology is developing rapidly, and the major future developments are in hybrid imaging and new therapeutic agents. Hybrid imaging is currently SPECT/CT and PET/CT, but PET/MR is on the horizon as a combined machine; using modern nuclear medicine computer techniques, the MRI can be fused with the PET, especially in neurology. The images below show CT (left), MR (centre) and fused PET/CT (right).



Courtesy of Dr Sally Barrington, Dept of Nuclear Medicine, St Thomas's Hospital, London

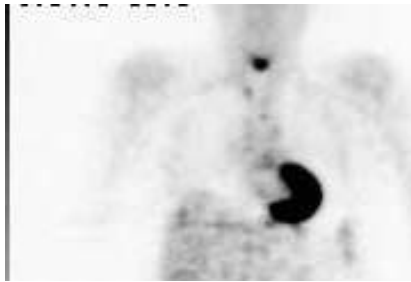
This shows left temporal lobe hypometabolism in a case of epilepsy.

PET imaging is essentially molecular imaging, but there are several important pitfalls that need to be recognised.

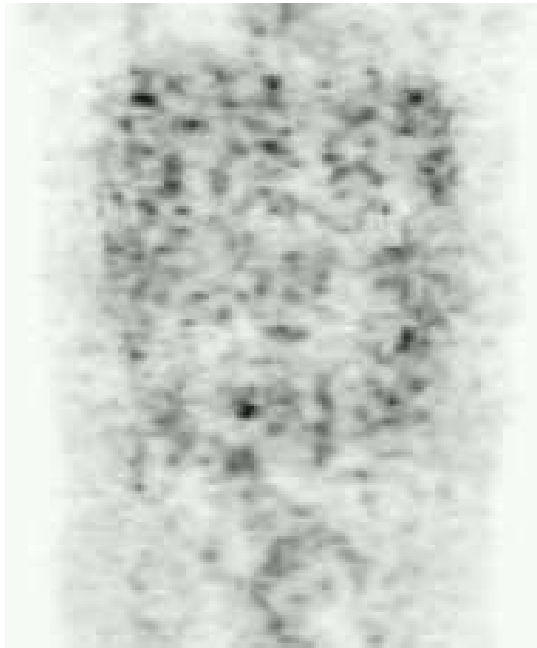
There is variable physiological uptake in salivary glands, larynx, heart, stomach and bowel, and in muscle and brown fat. The main pitfalls in interpretation are caused by talking, which gives abnormal laryngeal uptake, barium contrast, prostheses, movement artefacts, muscle uptake, injection artefacts, misregistration of PET with CT, poor uptake in uncontrolled diabetics, and confusing anatomical variations. The reason for having the patient rest quietly in a dark room is to minimise muscle uptake, as FDG is a glucose analog.



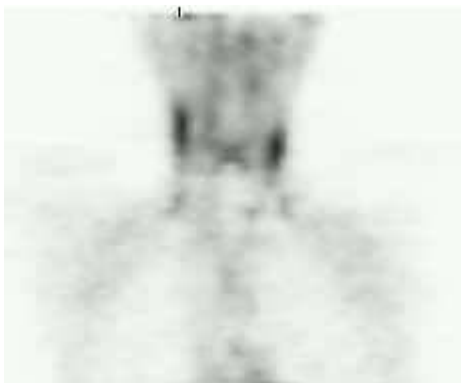Some examples are given below.



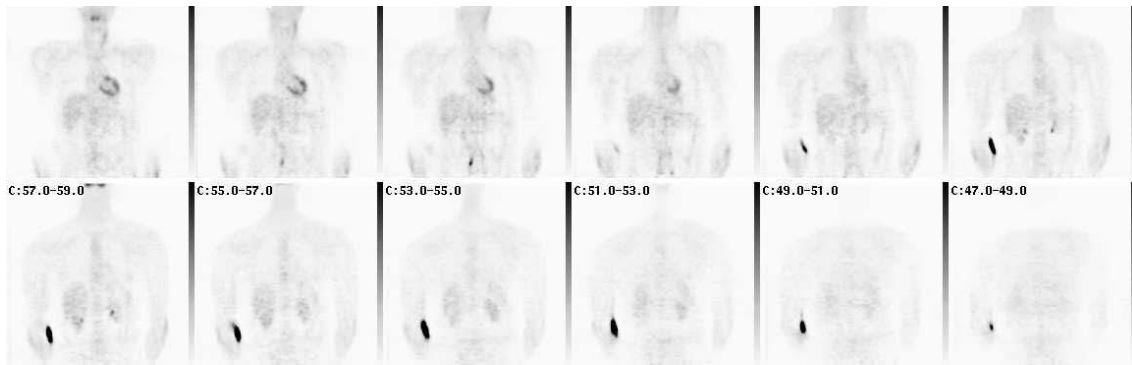
Laryngeal uptake from talking



Poor uptake in a diabetic



Neck muscle uptake due to tension

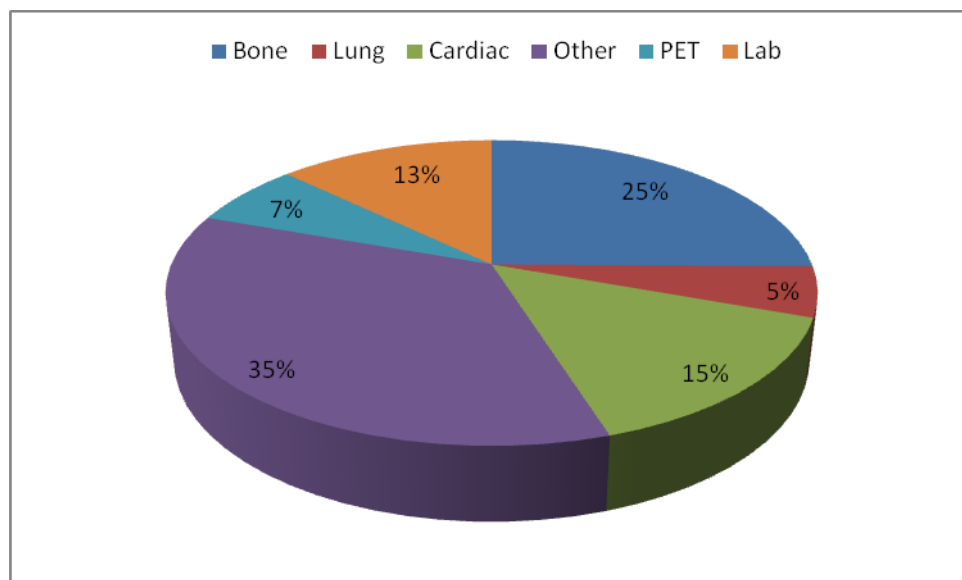


Poor injection - tissue.

Both new diagnostic radiopharmaceuticals and labelled monoclonal antibodies for therapies are being developed. PET/CT molecular imaging using a variety of PET tracers has a vital role to play in showing the distribution of the labelled radiopharmaceutical, at the same time reducing the need for animal experimentation. This is obviously better for the animals, and often much better science. Translational research, carefully planned and carried out, helps both human and veterinary practice.

## STATISTICS

The following pie chart gives the annual statistics for a large Nuclear Medicine department in London. The total number of studies is 7002, and this includes research studies. The chart shows that the greatest number of scans performed are bone and cardiac.



The category 'other' is made up of, among other investigations, endocrine, FP-CIT, renal, infection and therapies, plus a large number of studies not individually recorded on the departmental statistics. 'Lab' are non-imaging tests of renal function (GFR = glomerular filtration rate).

Courtesy of Ms Wendy Wallis, Charing Cross and Hammersmith Hospitals, London

## *LEGAL REQUIREMENTS*

The main ideal in limiting the dose to the patient is the ALARA principle - 'As Low As Reasonably Achievable'. To this end, the activity administered to the patient is often regulated by statutory bodies.

In the UK, the administration of radioactive substances is controlled by various Acts of Parliament - MARS [Medicines (Administration of Radioactive Substances)] Regulations 1978 and IR(ME)R [Ionising Radiation (Medical Exposure) Regulations] 2000. In addition, before a doctor can administer radioactive substances, they must be suitably trained and hold a valid licence from the Administration of Radioactive Substances Advisory Committee (ARSAC), who issue extremely comprehensive Notes for Guidance, and these indicate the maximum permissible activity that can be administered. The Notes are now available on the ARSAC website. It is the responsibility of the Radiopharmacy to ensure that the radio-isotopes are licenced under the various Medicines Acts.

In addition, before any doctor or technologist draws up a dose for administration to the patient, they must check the vial to ensure that it is the correct radiopharmaceutical, and then the activity to be administered must be measured in a dose calibrator, and recorded.

Obviously, the patient must not be or likely to be pregnant.

Similar regulations exist in other countries, and are administered by a variety of official bodies. In the Czech Republic this is the Ministry of Health and in the US the FDA. They will publish their own regulations and guidelines.

It is also extremely helpful to have information leaflets for the patients. This is an example:

# Nuclear Medicine Examinations

## Some questions answered

### HOW DO I PREPARE FOR THE TEST?

There is no general set of instructions covering all Nuclear Medicine examinations. Your appointment letter will give you instructions on how to prepare for the test. It is important to follow these instructions to ensure accurate, diagnostic results.

### HOW LONG WILL THE TEST TAKE?

The length of the test varies with the type of examination you are having. Please see your appointment letter for the estimated time required in your case.

### AFTERWARDS

Unless a member of our staff advises otherwise, you may resume normal diet and activities immediately.

### FINDING OUT THE RESULTS

Your test will be interpreted promptly. The results will be forwarded to your doctor in time for your next scheduled appointment. He/she will inform you of the results.

We realise you probably have some questions regarding your Nuclear Medicine examination and hope this information will help explain the procedure to you. If you have further questions, do feel free to telephone the Department.

### GENERAL

You are asked not to bring children to the Department with you unless the child is the patient.

### WHAT IS NUCLEAR MEDICINE?

Nuclear Medicine is a section of the Imaging (X-ray) Department that uses radioactive materials to determine if organs are working properly.

## WHAT KINDS OF NUCLEAR MEDICINE TESTS ARE AVAILABLE?

There are several Nuclear Medicine tests available for diagnostic purposes. They share in common the use of radioisotopes to show not just the appearance of the body part but also function.

## HOW DOES NUCLEAR MEDICINE WORK?

Before the test begins you will be given a small amount of radioactive material called a radioisotope that will usually be injected into a vein (similar to giving a blood sample) or sometimes swallowed or breathed in. There should be little or no discomfort during the test. Nuclear Medicine procedures are safe, effective and painless.

How the test is performed depends on the examination your doctor has requested. In many cases there will be a delay between the time you are given the radioisotope and the time the pictures are actually taken. This gives the radioisotope time to flow through the body and concentrate in the organ that is being examined. In some cases, a series of pictures will be taken with a delay of several hours or sometimes days between them.

For most studies the patient lies comfortably on a table. A large camera is positioned over the body and is moved or rotated around the patient, depending on the test. The camera detects the radioactive substance and displays this information as a picture on a computer screen or on film.

## IS THERE ANY RISK FROM THE RADIATION?

The Nuclear Medicine staff members are trained in radiation safety procedures. The radioisotopes used are administered in the smallest possible doses needed to achieve best quality results.

The radioactivity is quickly eliminated from the body, usually within 24 hours. There are usually no reactions or side effects to Nuclear Medicine tests and you should resume normal activity as soon as the test is complete.

The benefits of the scan far outweigh the risk to your health. If you have any concerns, please contact us.

## **ARE YOU PREGNANT, THINK YOU MAY BE PREGNANT, OR A NURSING (BREAST-FEEDING) MOTHER?**

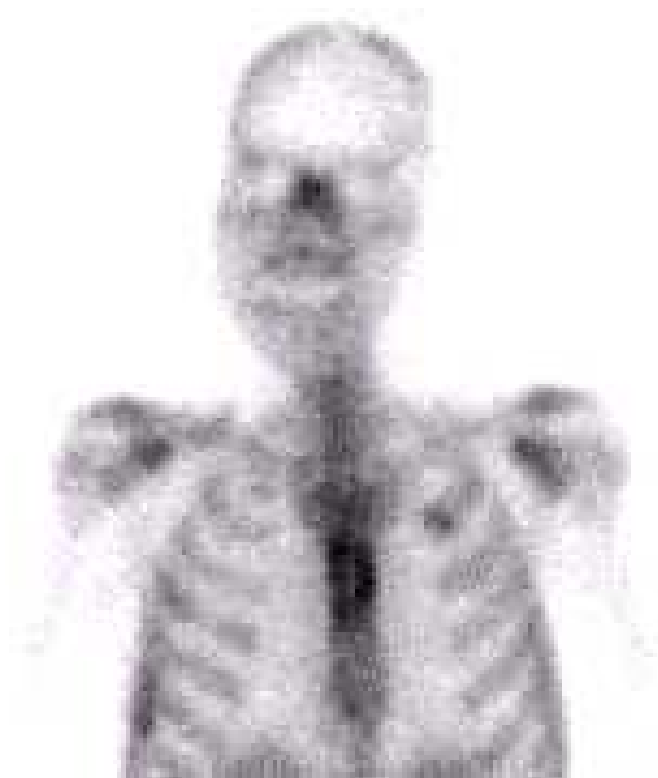
**Special rules apply to pregnant patients and nursing mothers. Please contact the Department for advice**

Courtesy of Ms Wendy Wallis, Dept of Nuclear Medicine, Charing Cross Hospital, London

## QUIZ

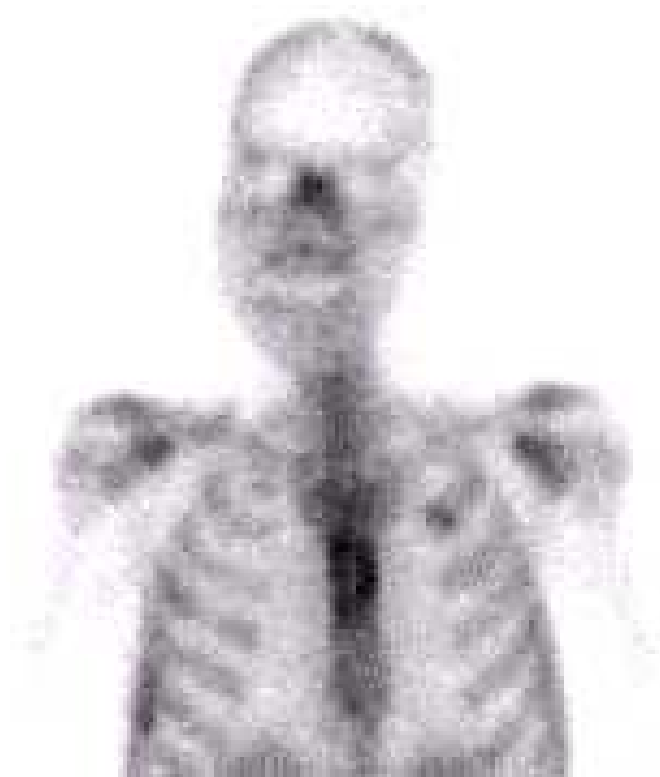
The following images are more for fun than anything else, but do show the range of Nuclear Medicine potential.

1. What is this and what does it show?





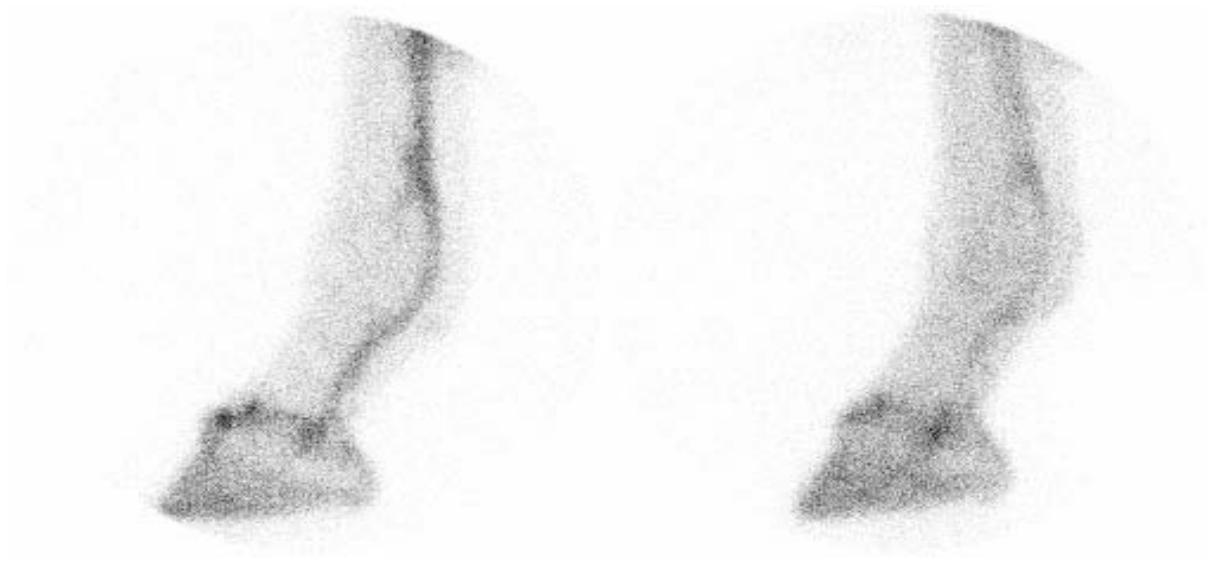
ANSWER



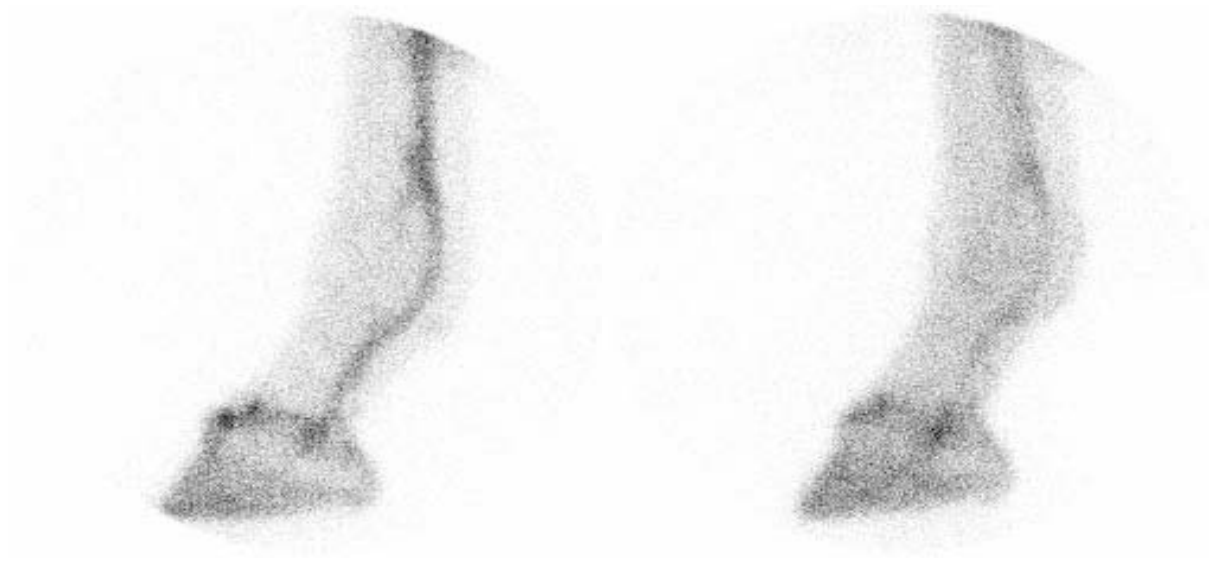This is a bone scan of the face and thorax obtained using  $^{99m}\text{Tc}$ -HDP. It shows asymmetry of the jaw which is due to a tumour (adamantinoma), which showed intense uptake on the PET scan.



2. What are these?



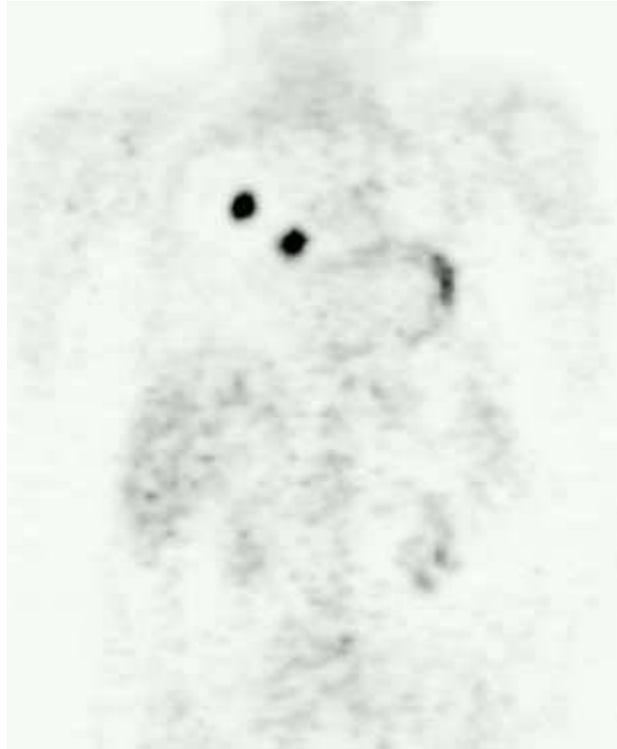
ANSWER



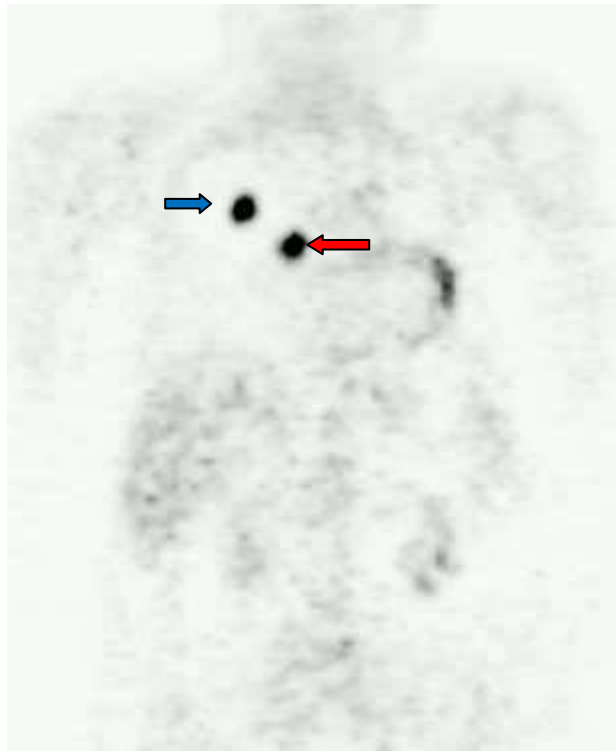
They are the blood pool and delayed images of a horse's foreleg and hoof, obtained using  $^{99m}\text{Tc}$ -HDP.

Image courtesy of Prof Greg Daniel, Dept of Veterinary Medicine, University of Tennessee

3. What type of examination is this? What isotope was used? What does it show?

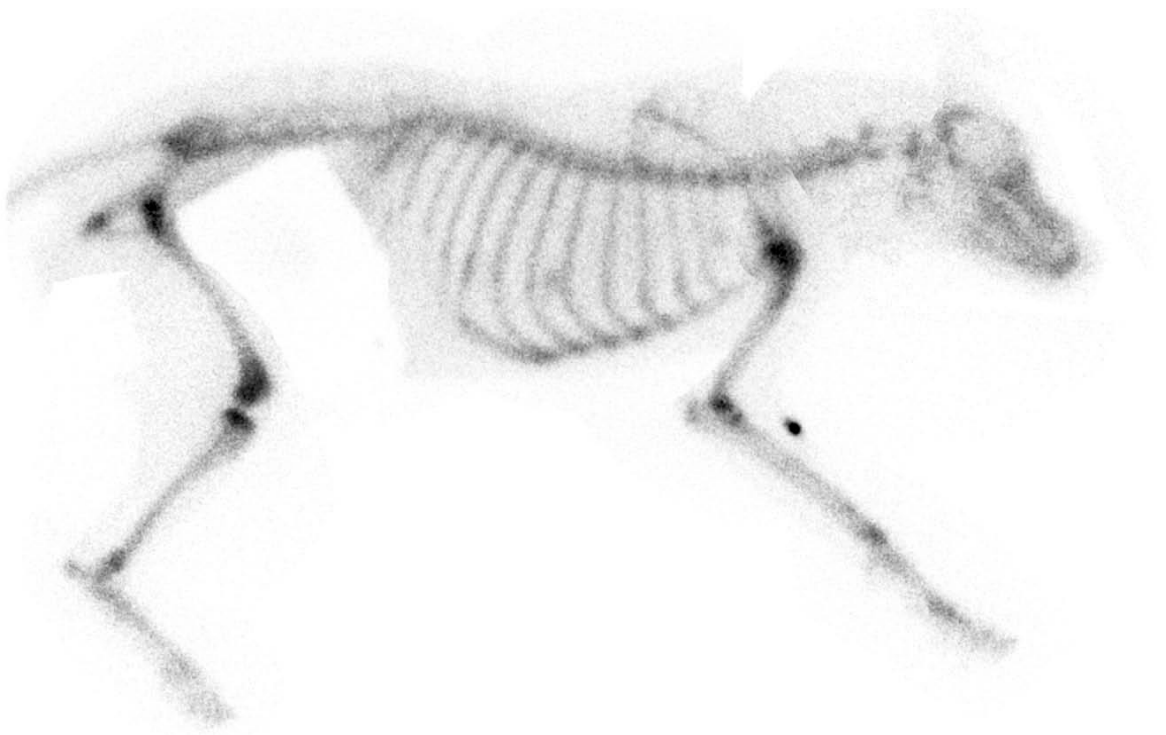

## ANSWER

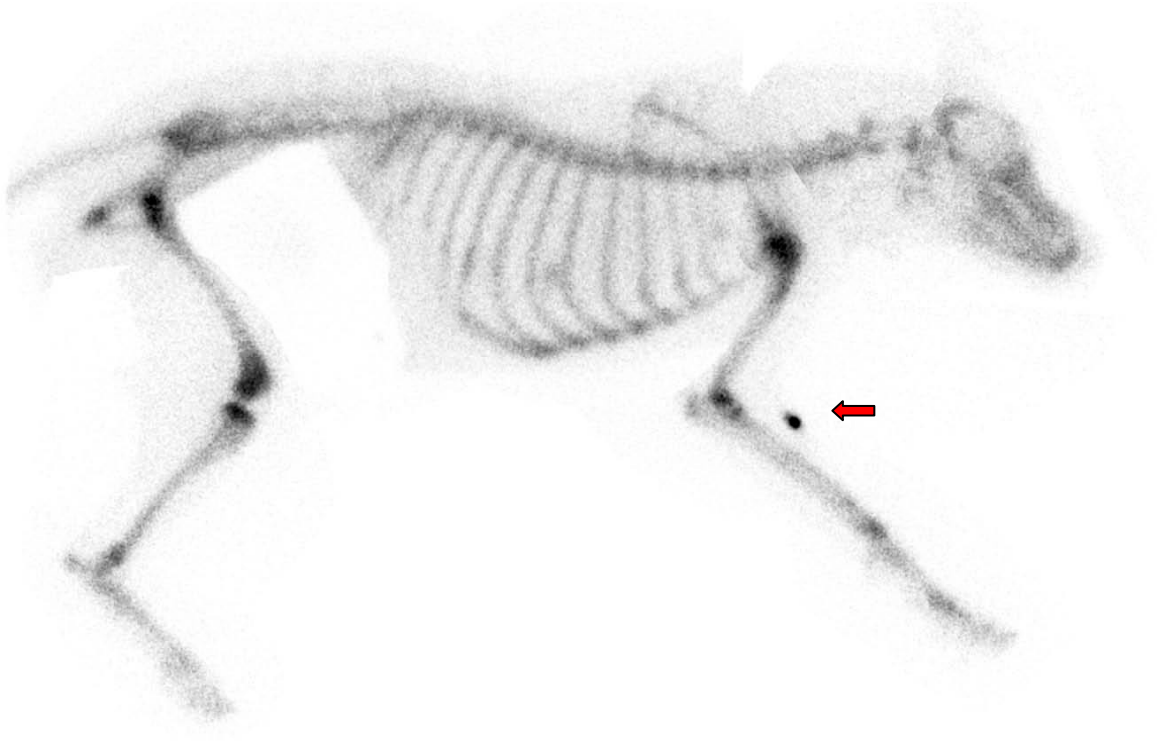

This is a PET scan using  $^{18}\text{F}$  labelled FDG. It demonstrates a right mid-zone lung cancer (blue arrow) and also uptake in the right hilar nodes (red arrow). The positive hilar uptake makes this an inoperable lesion.

4. What is this? What radiopharmaceutical was used?



ANSWER

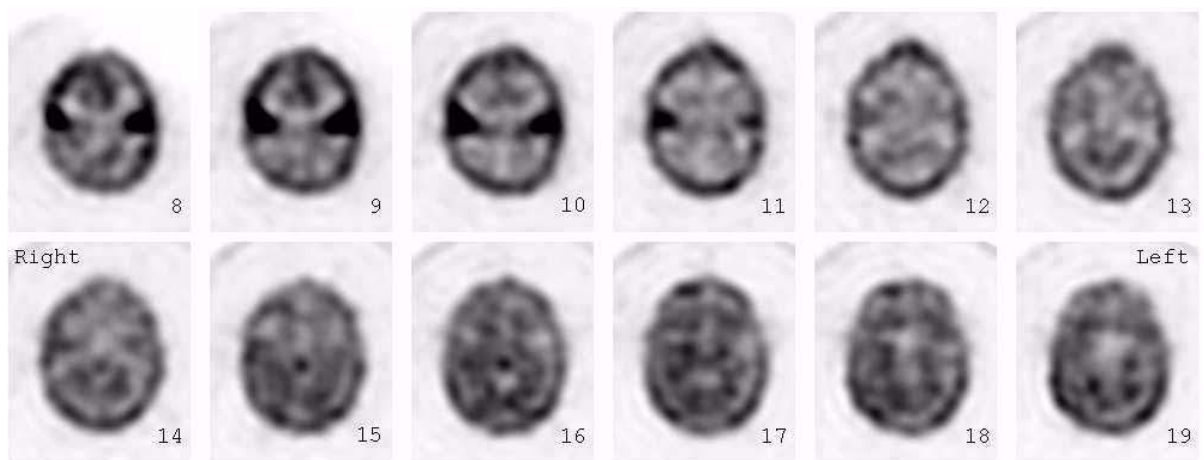


This is a normal lateral view of a dog's skeleton, obtained using  $^{99m}\text{Tc}$ -HDP. Note the injection site (arrowed).

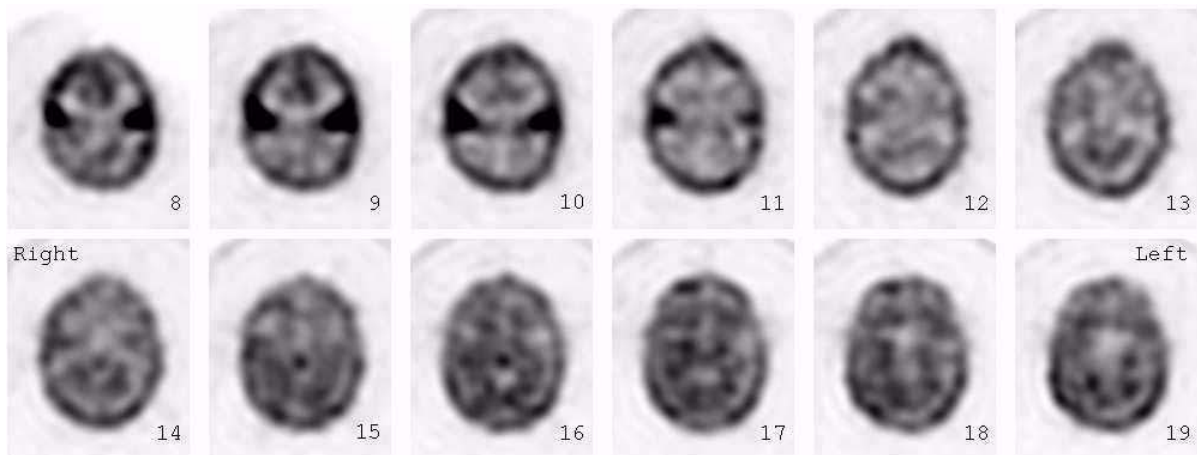
Image courtesy of Prof Greg Daniel, Dept of Veterinary Medicine, University of Tennessee



5. This is a FP-CIT scan. Is it normal? What can you see?




## ANSWER

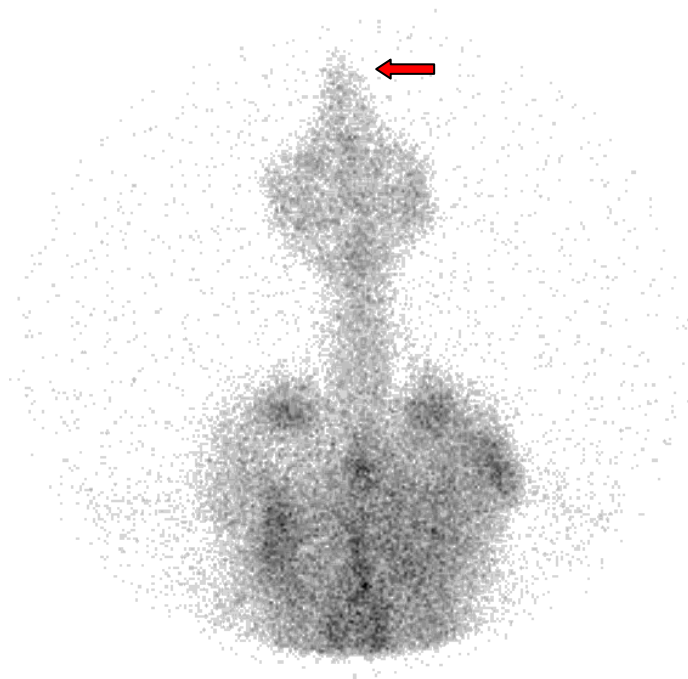


There is no uptake at all in the basal ganglia and very high background activity in a patient who had suffered bilateral middle cerebral artery occlusions, and subsequently died.

6. What do you think this is?



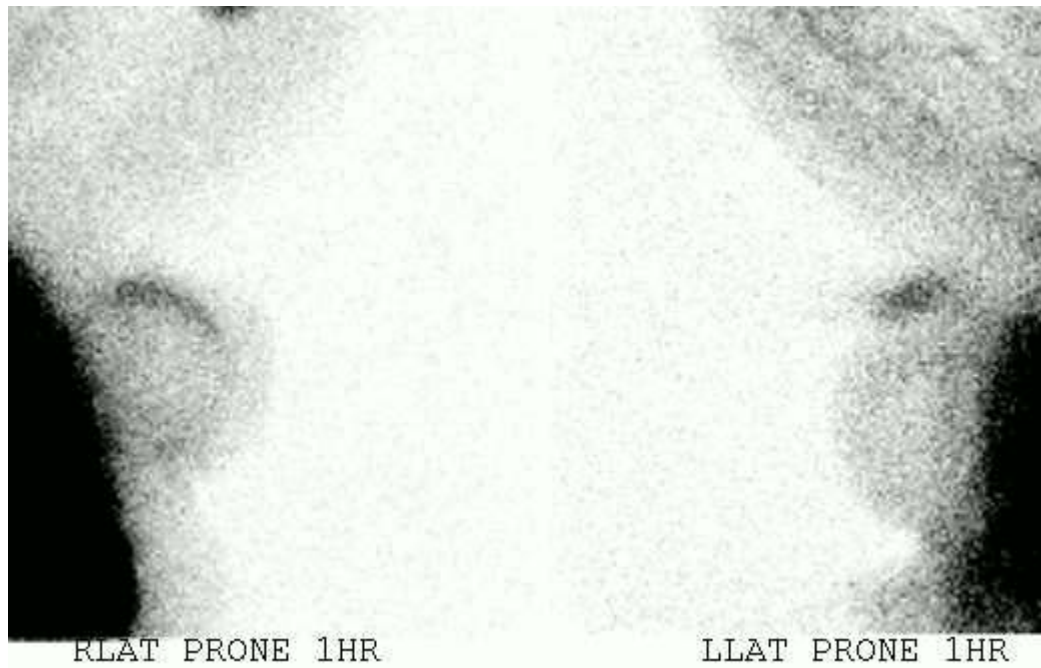
ANSWER



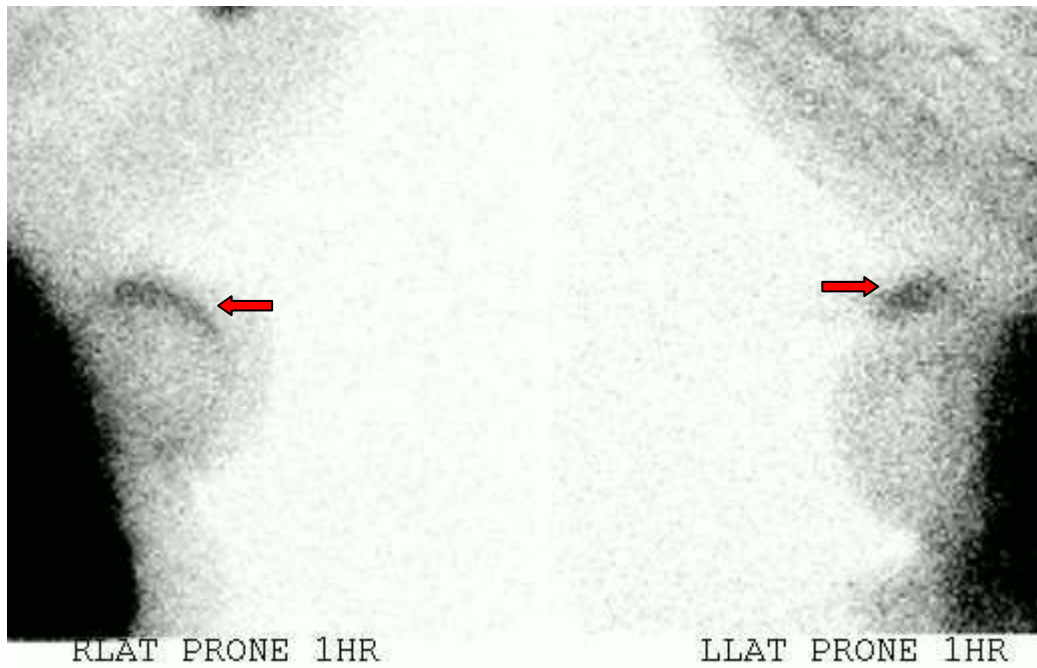
This is a dorsal view of a bone scan of an owl. Note the beak (arrowed) has a blood supply. The image was obtained using  $^{99m}\text{Tc}$ -HDP.

Image courtesy of Prof Greg Daniel, Dept of Veterinary Medicine, University of Tennessee

7. This patient had recent bilateral breast implant surgery, and now had pain. What can you see? What imaging agent was used?

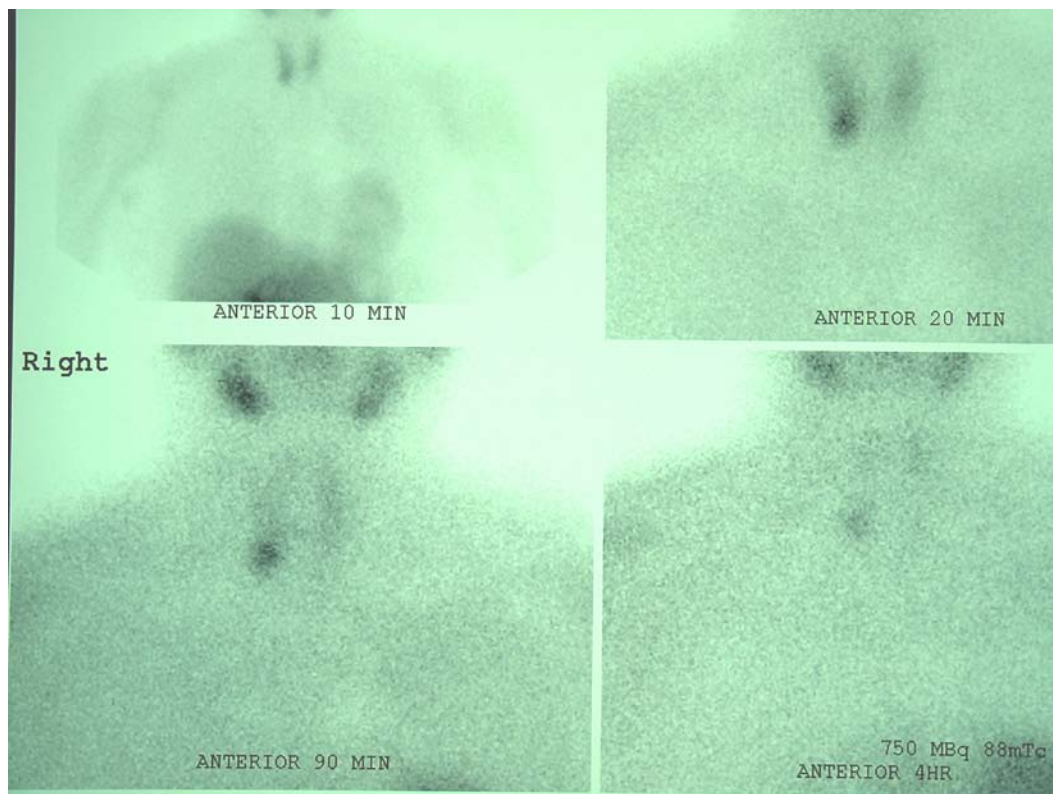

## ANSWER



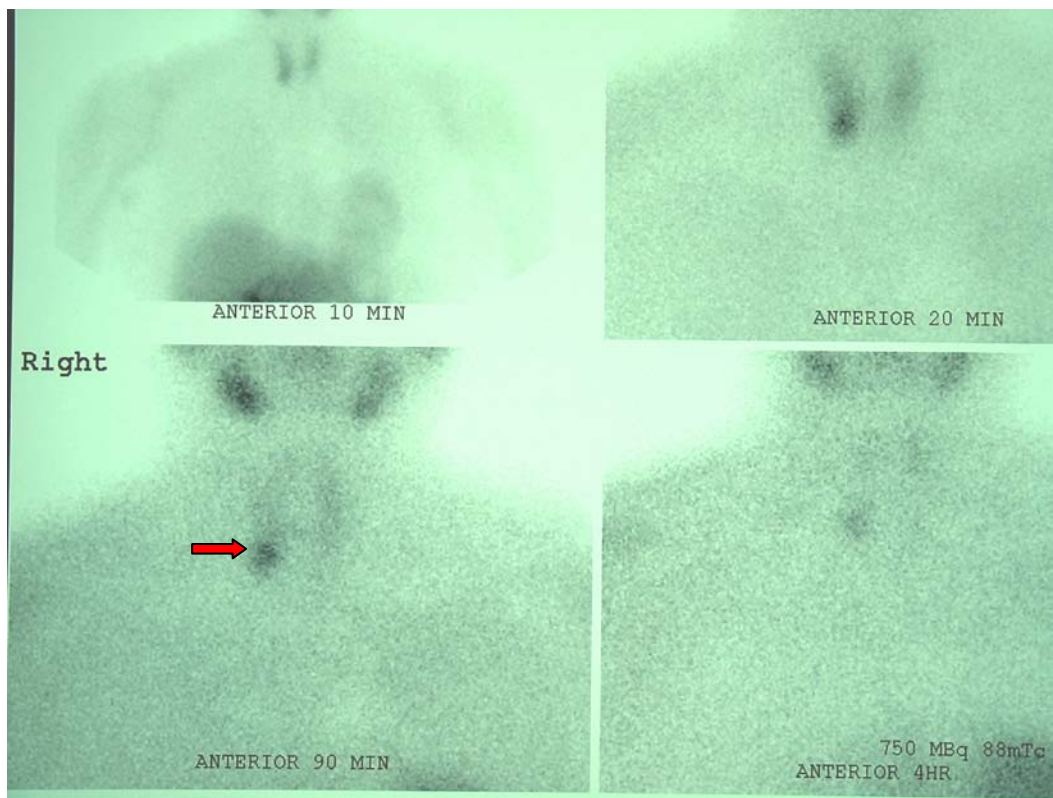The imaging agent was  $^{99m}\text{Tc}$ -HMPAO used to label the patient's own white cells, looking for sites of infection. There is crescentic abnormal uptake in both breasts (arrowed) at the sites of infection.

8. What examination is this, and what does it show? What is the isotope?



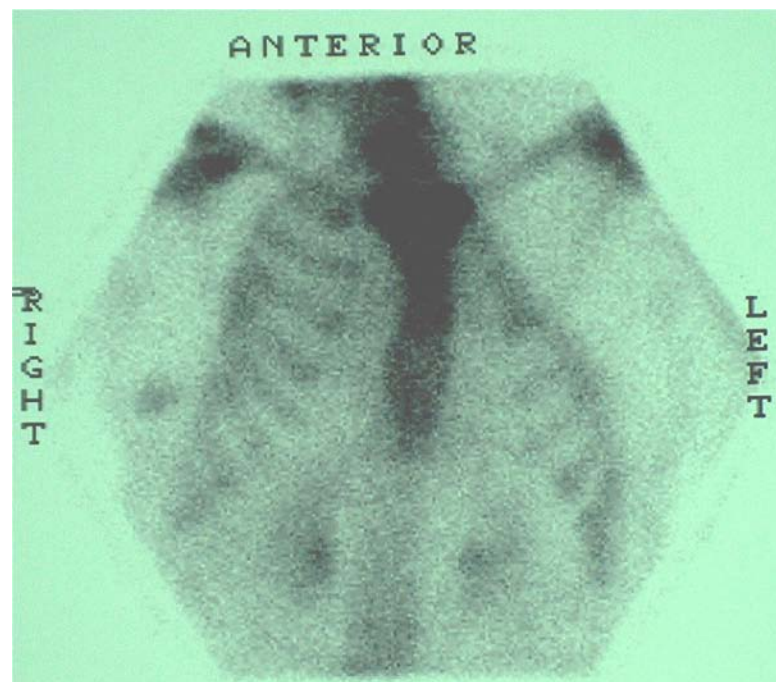


ANSWER

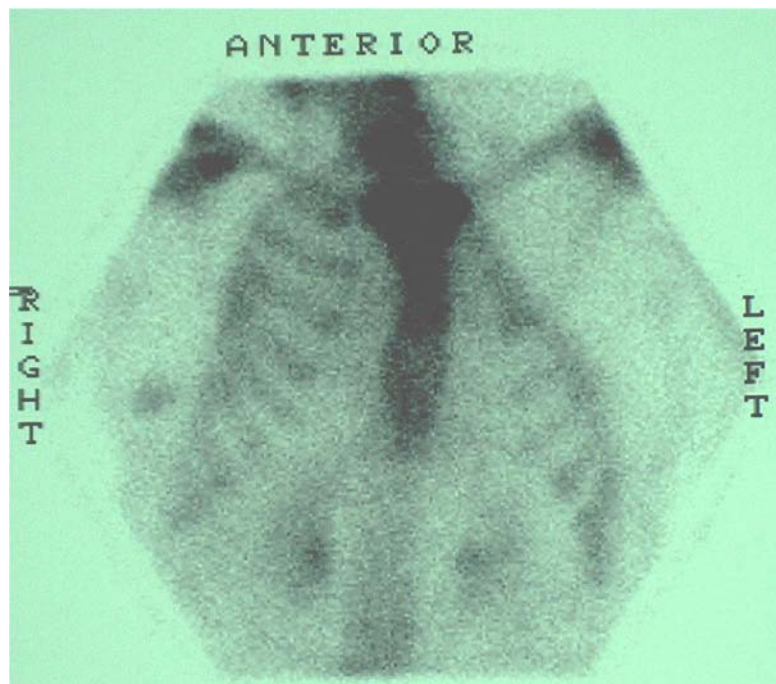


This is a  $^{99m}\text{Tc}$ -sestaMibi scan to demonstrate a parathyroid adenoma (arrowed).

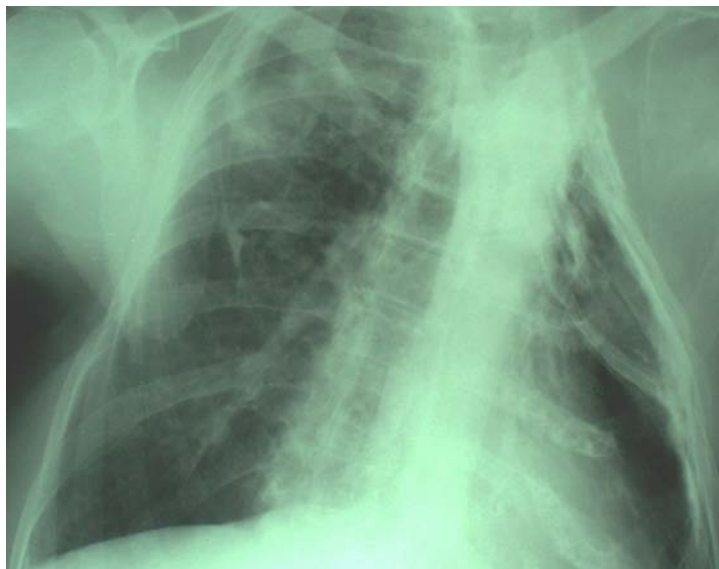9. What is this and what does this show?



ANSWER

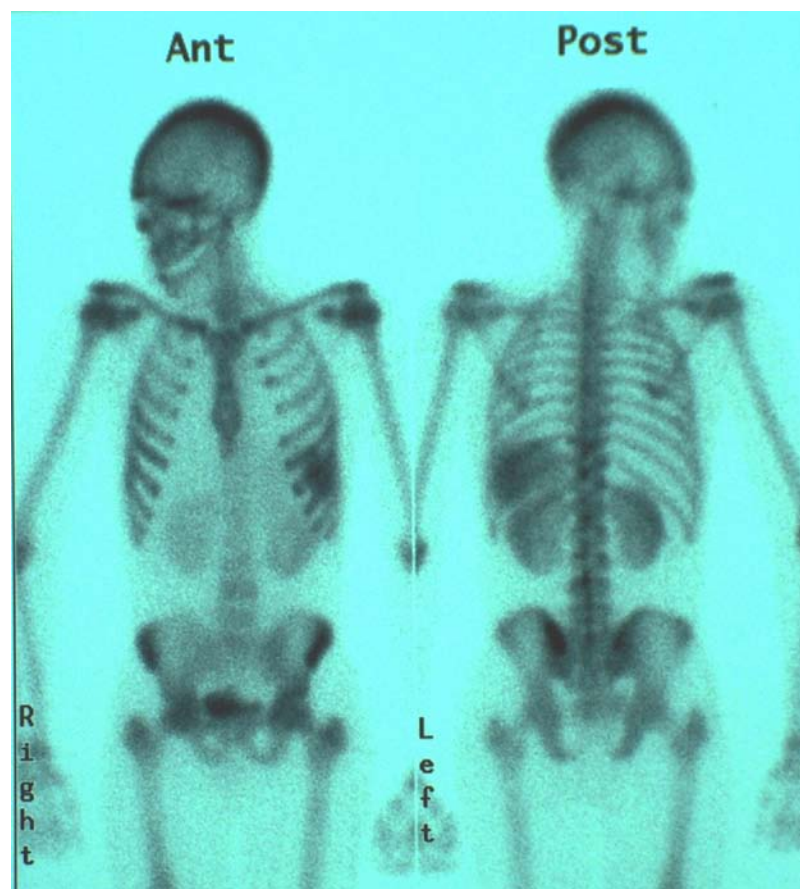


This is an anterior view bone scan of the thorax. It is asymmetrical, as the patient has had a thoracoplasty on the left for TB in the past.

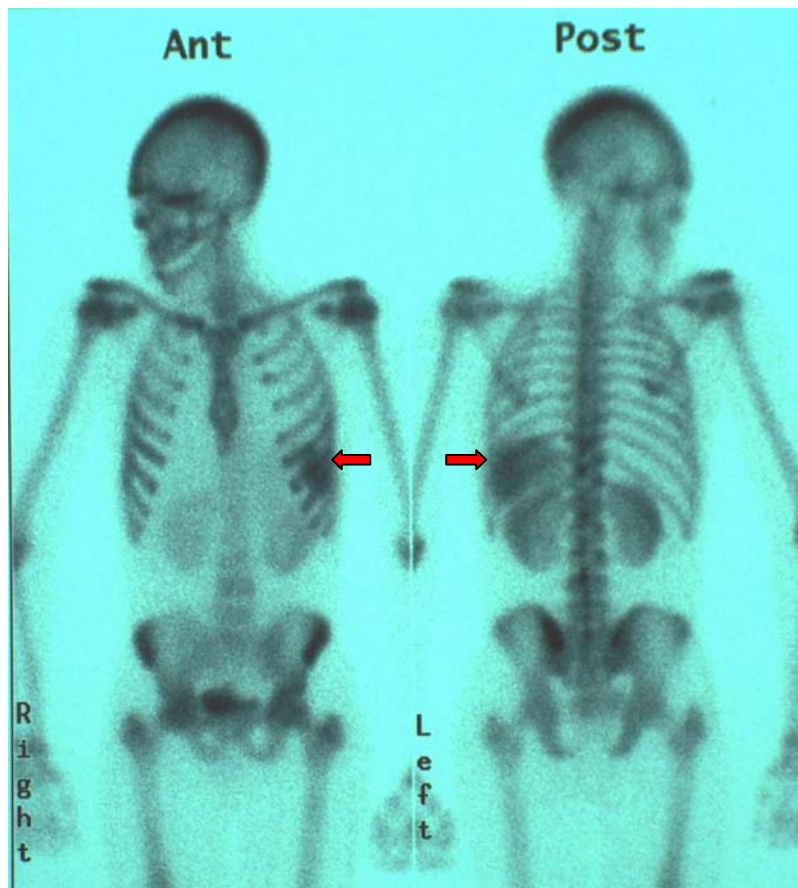

This is the x-ray.

10. This patient has sickle cell disease. What can you see, and why?

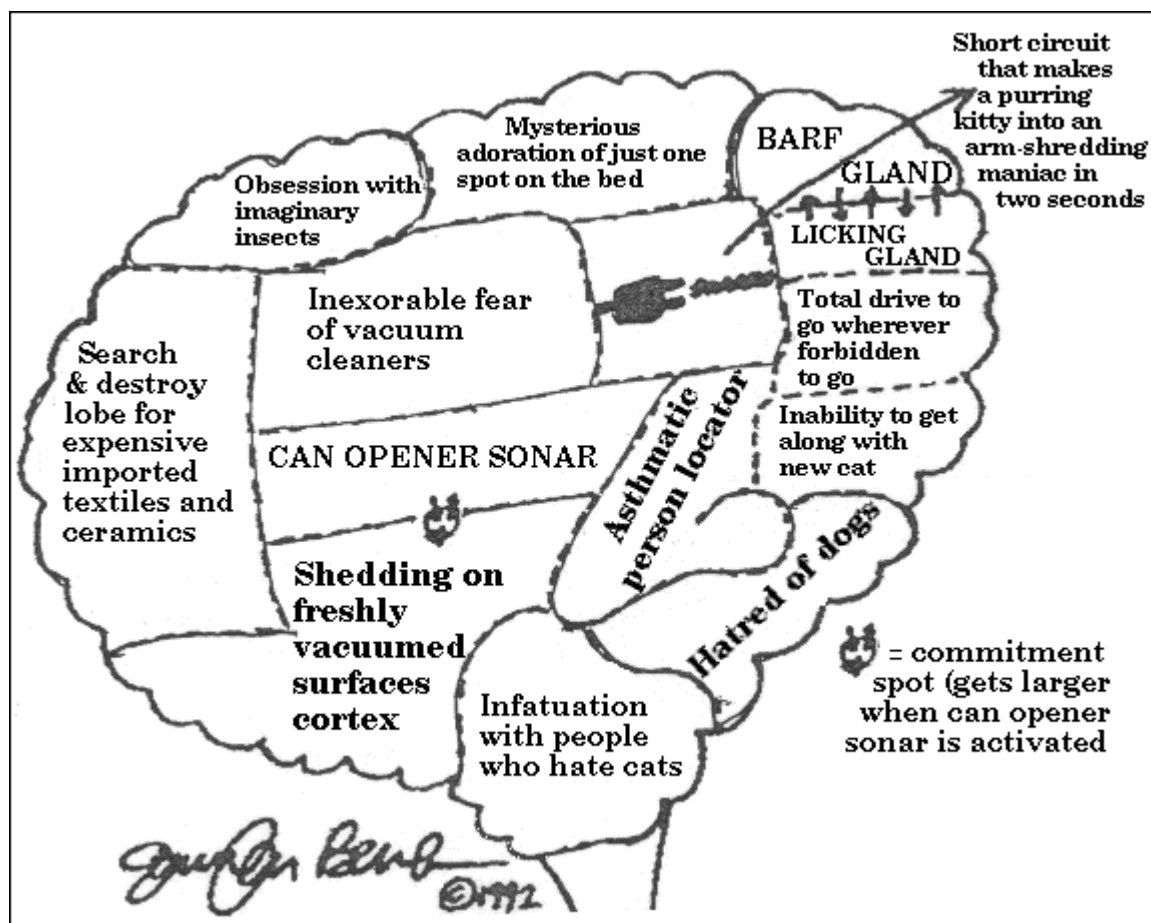


ANSWER

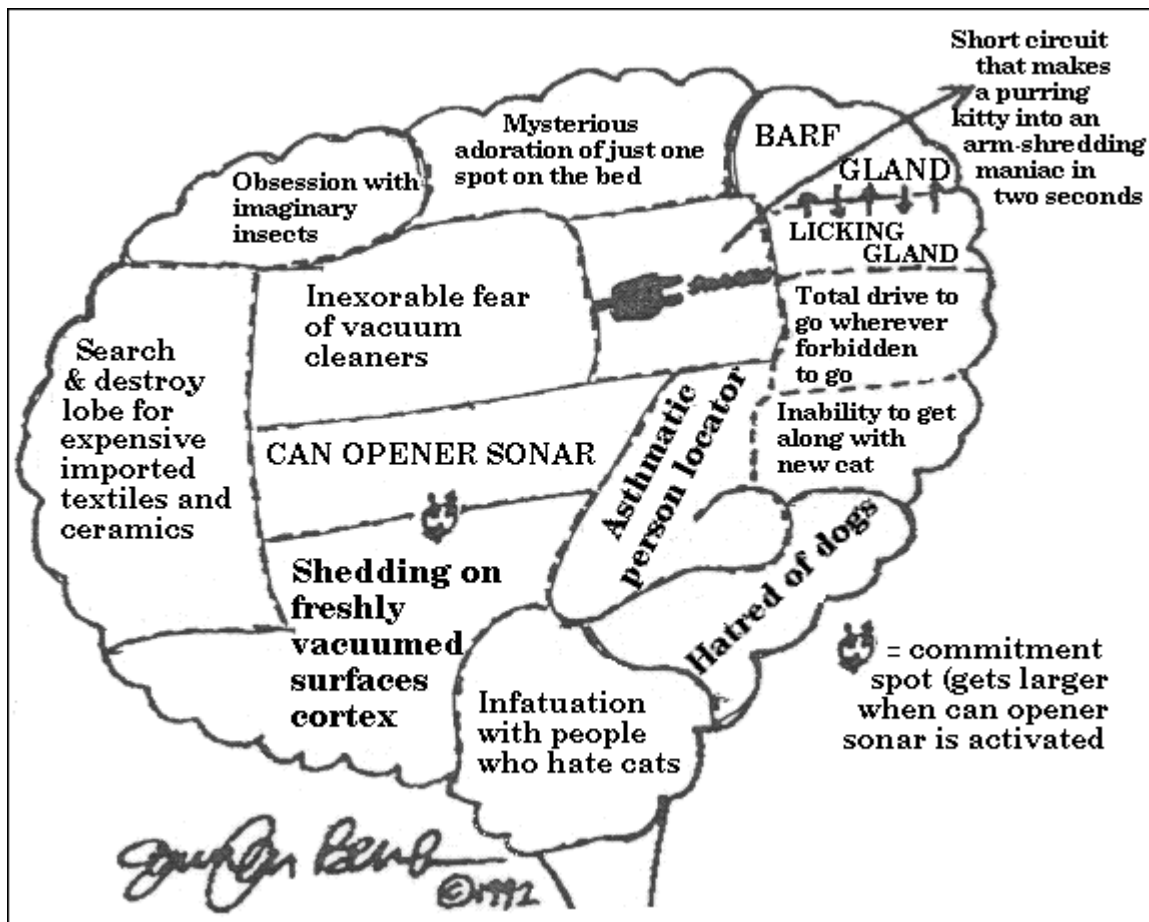


This is a bone scan in a patient complaining of pain, as such patients may well have bone infarcts. However, there is abnormal uptake in the spleen (arrowed), as the patient had had a splenic infarct, which was the cause of the pain.

11. What does this show?



ANSWER



Courtesy of Dr Kathelijne Peremans, Dept of Veterinary Medicine, University of Ghent

The cerebral mapping of a cat's brain!



### *SUGGESTED READING AND WEBSITES*

Clinical Nuclear Medicine - Maisey, Britton, Collier and Siraj

A Clinician's Guide to Nuclear Medicine - Taylor, Schuster and Alazraki

Get Through Nuclear Medicine for the FRCR and MRCP - Frank and Nunan

Exercises in Clinical Nuclear Medicine - Cook and Dutton

Making the best use of a Department of Clinical Radiology (MBUR) - Royal College of Radiologists, London

Radiology - an Illustrated History - Eisenberg

### WEBSITES

[www.arsac.org.uk](http://www.arsac.org.uk)

[www.bnms.org.uk](http://www.bnms.org.uk)

[www.csnm.cz](http://www.csnm.cz)

[www.eanm.org](http://www.eanm.org)

[www.nucmedinfo.com/](http://www.nucmedinfo.com/)

[www.snm.org](http://www.snm.org)